

Can a Bullet be Dangerous without a Weapon?

Smaranda Ioana Lupușoru^{1*}, Simona Damian^{1,2}, Bianca Codrina Morărașu^{1,3}, Alexandru Grigorovici^{1,3}

¹Grigore T. Popa University of Medicine, Iași, Romania

²Department of Legal Medicine, Forensics Institute, Iași Romania

³Sf. Spiridon County Clinical Emergency Hospital, Iași, Romania

*Corresponding author:

Smaranda Ioana Lupușoru, M.D.

Grigore T. Popa University of Medicine

E-mail: smaranda-ioana.lupușoru@d.umfiiasi.ro

Rezumat

Poate fi periculos un glonț fără armă?

Introducere: Leziunile provocate de explozii sunt unice prin capacitatea lor de a provoca leziuni acute mai multor persoane în același timp. Mecanismul și gravitatea impactului depind de distanță, de energia cinetică eliberată, de material, de suprafață, de protecția disponibilă și așa mai departe. Unda de explozie poate provoca diferite tipuri de leziuni, de la cele superficiale la cele interne, care pun viața în pericol. Prin urmare, examinarea clinică și imagistică, precum și tratamentul în urgență sunt obligatorii. *Prezentarea cazului:* prezentăm cazul unui tânăr de sex masculin în vârstă de 19 ani, victimă a unei leziuni accidentale provocate de explozie în urma manipulării necorespunzătoare a unui cartuș, respectiv a încercării de a tăia glonțul cu un fierăstrău circular. Explozia a afectat cinci segmente ale corpului. După îngrijirile în departamentul de urgență, pacientul a fost admis în sala de operație unde au lucrat concomitent trei echipe chirurgicale diferite. În următoarele șase zile a fost monitorizat îndeaproape în unitatea de terapie intensivă și ulterior a fost externat după 13 zile de la internare.

Concluzie: Curiozitatea tinerilor este cheia unei dezvoltări continue, dar, uneori, aceasta poate avea efecte dăunătoare asupra bunăstării lor. Managementul traumei este o cursă contra cronometru pentru a menține pacientul în viață și fără invalidități ulterioare.

Cuvinte cheie: explozie accidentală, leziuni abdominale, managementul traumei

Received: 05.04.2023

Accepted: 28.07.2023

Abstract

Background: Blast injuries have a unique ability to cause acute harm to multiple individuals simultaneously. The severity and mechanism of injury depend on factors such as distance, released kinetic energy, material properties, affected area, and available protective measures. The resulting explosion wave can cause a range of injuries, from superficial to internal, and potentially life-threatening. Therefore, it is crucial to promptly evaluate the patient clinically and with imaging techniques and provide immediate emergency interventions.

Case Report: We present the case of a 19-year-old male who accidentally sustained blast injuries while mishandling a cartridge while attempting to cut the bullet with a hand-held circular saw. The explosion caused injuries in five anatomical regions. After receiving immediate emergency care, the patient underwent surgical intervention performed simultaneously by three surgical teams. Subsequently, he was monitored in the intensive care unit (ICU) for six days and was eventually discharged after a 13-day hospitalization.

Conclusion: The natural curiosity of young individuals plays a significant role in promoting ongoing progress. However, it can sometimes lead to detrimental consequences for their well-being. Effective management by a polytrauma team becomes a race against time to preserve the patient's life and prevent disabilities.

Key words: accidental blast, abdominal injuries, trauma management

Introduction

Scientific literature on blast injuries primarily focuses on the effects of blast waves in the context of warfare, terrorist attacks, and work-related accidents. Blast injuries are a complex form of trauma that can have life-threatening consequences across multiple body systems. In regions like Iraq and Afghanistan, more than 71% of United States (US) military personnel have experienced blast injuries (1), and the US witnesses over 1300 bomb incidents annually (2).

Explosions generate a blast wave, inflicting diverse lesions upon contact with the human body. As the wave travels through tissues of different densities, it can lead to severe complications such as barotrauma affecting organs filled with air, including the lungs, bowels, and ears, as well as trauma-induced coagulopathies (3,4). Prompt clinical intervention is essential to enhance survival prospects. In such cases, a multidisciplinary team should swiftly engage in resuscitation maneuvers, active bleeding management, damage control surgery, and the prevention of iatrogenic

hypothermia, acidosis, and coagulation disorders (5-7).

Abdominal injuries can range in severity depending on the mechanism and forces involved. They can be classified as blunt or penetrating trauma. When focusing on penetrating abdominal trauma, it involves damage and contamination of various structures, including the abdominal wall, solid organs, hollow viscera, and blood vessels.

Although Romania is currently experiencing peaceful times, the use of weapons by civilians is prohibited by legislation. However, given the ongoing international conflicts near the border (8), this case report highlights the challenges associated with managing blast injuries in patients, thereby raising awareness on the matter.

Case Report

We present a case of a 19-year-old male who was transported via ambulance to the Emergency Department (ED) of Saint Spiridon County Clinical Emergency Hospital Iaşi with polytrauma resulting from an explosion of a

cartridge. The patient had an unfortunate incident while attempting to dismantle a cartridge using a hand-held circular saw.

In the prehospital setting, the area was secured by the police, firefighters, and paramedics to ensure the absence of additional victims. The patient received immediate care from emergency doctors equipped in an intensive care unit ambulance, following the Advanced Trauma Life Support protocol. Initial interventions included controlling external bleeding, ensuring airway patency, and ruling out life-threatening conditions such as tension pneumothorax, open chest wound, massive hemothorax, or cardiac tamponade. These assessments were performed through clinical examination and extended-Focused Assessment with Sonography for Trauma (extended-FAST) ultrasound. Continuous monitoring of vital signs, including electrocardiogram (ECG), blood pressure (BP), and oxygen saturation (SpO₂), was implemented, and intravenous crystalloids were administered before transport to the hospital.

Upon arrival at the ED, the patient was alert (Glasgow Coma Scale = 15), had a normal respiratory pattern (respiratory rate 18/min, SpO₂ = 96% on room air), and maintained hemodynamic stability (blood pressure

= 150/80 mmHg, heart rate = 90/min) with a Trauma Score of 16. Clinical examination revealed multiple penetrating injuries in the chest, abdomen, and bilateral thighs, along with distal third amputation of the left forearm and fold in the right orbit. (*Fig. 1A*). Abdominal ultrasound, chest X-ray, and left limb X-ray were performed as per the trauma protocol, along with a comprehensive set of blood tests. A multidisciplinary evaluation was conducted by the general, plastic, vascular, orthopedic, ophthalmology, and oral maxillofacial surgical teams on call. The patient's medical history indicated a previous accident resulting in a residual foreign body in the liver (*Fig. 1B*).

A total body CT scan was performed to identify foreign bodies and potential sources of bleeding. Notable injuries observed included a fracture on the right orbit roof, frontal right hem sinus, and intracranial metal fragments of 11 mm and 1.5 mm. Soft tissue infiltration with hemorrhagic densities of the eyelid and multiple gas bubbles in the inner and outer sides of the orbit canal were evident. Additionally, two metal fragments measuring 5.5 mm and 7 mm were found in the soft tissue adjacent to the left horizontal mandible, along with hematic infiltration and gas bubbles

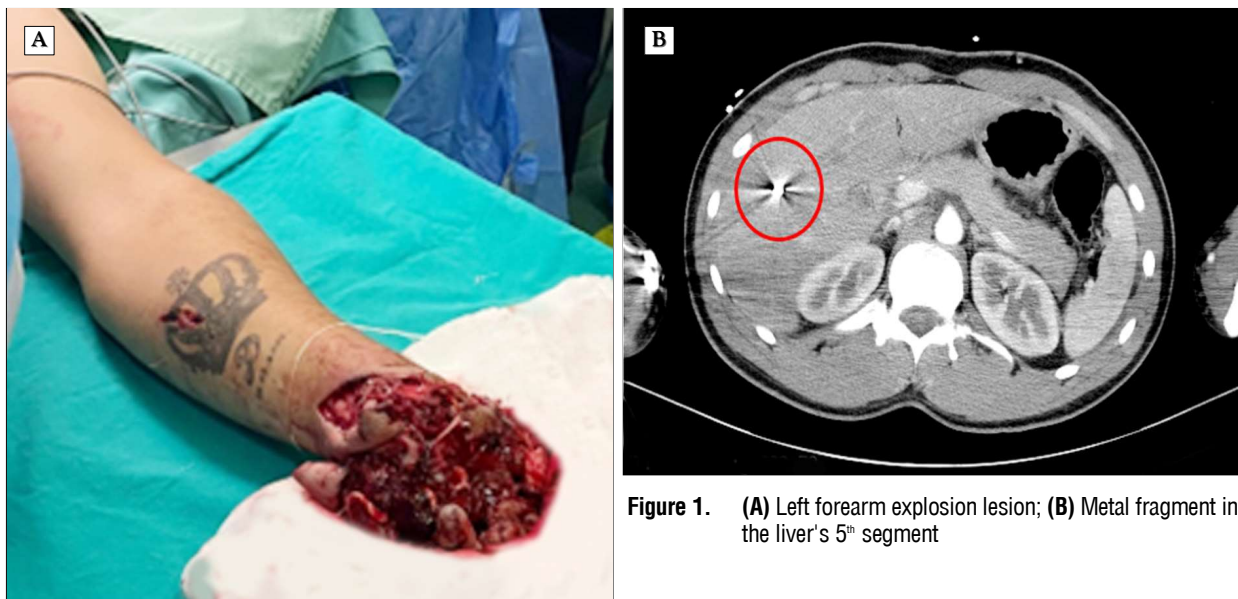


Figure 1. (A) Left forearm explosion lesion; (B) Metal fragment in the liver's 5th segment

extending to the angle. An 11 mm metal fragment was discovered, with infiltration of adipose tissue and gas bubbles corresponding to the right C3 vertebral cartilage, and another 3 mm fragment corresponding to the right chondrocostal C5 vertebral cartilage. The CT scan revealed a 5 mm metallic foreign body with adjacent gas bubbles in contact with the left rectus abdominis muscle in the epigastric area, as well as 6.5 mm and 4.5 mm metal fragments adjacent to the right rectus abdominis muscle and paraumbilical area. A cluster of metallic fragments, measuring up to 7 mm, was identified in the adipose tissue of the right iliac fossa (RIF) (*Fig. 2A*). Additionally, another intraperitoneal foreign body was observed between small bowel loops, accompanied by 35 mm of free fluid in the hypogastrium and 19 mm in the left paracolic gutter.

Lacerations in the left rectus abdominis muscle near the epigastric artery were confirmed by imaging. Lower limb scans detected multiple foreign bodies in the right quadriceps muscle and metallic foreign bodies in the left hip.

A multidisciplinary team of surgeons, including specialists in general surgery, orthopedics, and ophthalmology, conducted the following procedures:

An ophthalmologist conducted an examination of and sutured the wound located in the superior orbital region

Orthopedic surgeons performed the ampu-

tation of the distal third of the left forearm (*Fig. 2B*).

General surgery management involved exploring penetrating wounds and extracting foreign bodies from the abdominal and thoracic walls. A laparotomy was performed to evaluate the small bowel, which revealed five lesions that were treated with multiple enterorrhaphies. Intraabdominal foreign bodies were also removed, and the abdominal cavity was lavaged and drained. During the exploration of the thigh lesions, foreign bodies were found approximately 1 cm from the right femoral vein, along with a large hematoma and muscle tearing (*Fig. 3*).

Post-operative care was provided in the intensive care unit (ICU) for six days. The patient received analgesia, proton pump inhibitors (PPIs), anticoagulation, laxatives, and underwent daily blood tests (*Fig. 4*). Regular surgical assessments were conducted to monitor the patient's recovery comprehensively.

Psychological support was also given to the patient, who remained stable throughout the post-operative phase. After 13 days of admission, the patient's condition had steadily improved, and as a result, the patient was discharged without any further complications.

Discussion

The management of trauma cases resulting from domestic explosions requires following

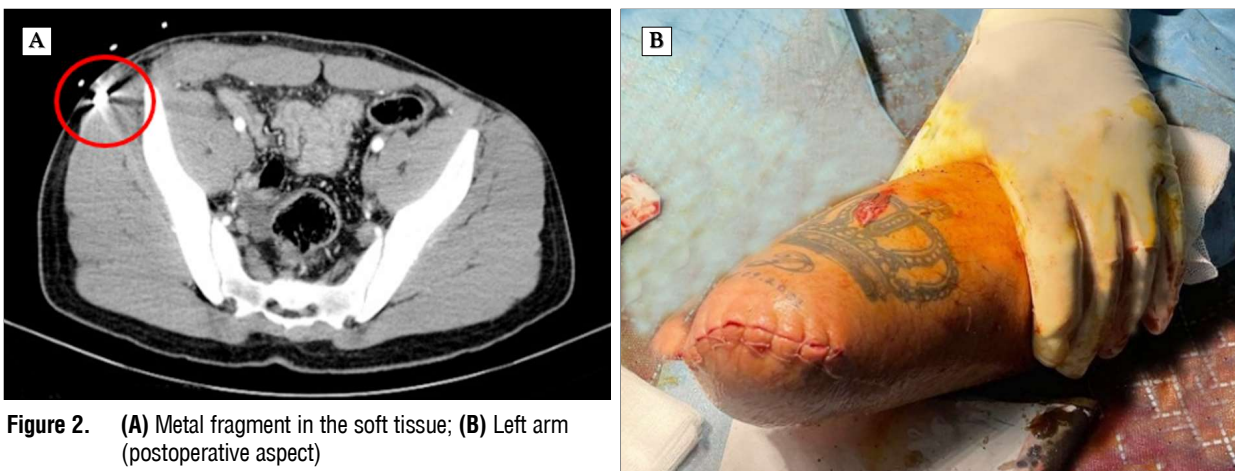


Figure 2. (A) Metal fragment in the soft tissue; (B) Left arm (postoperative aspect)

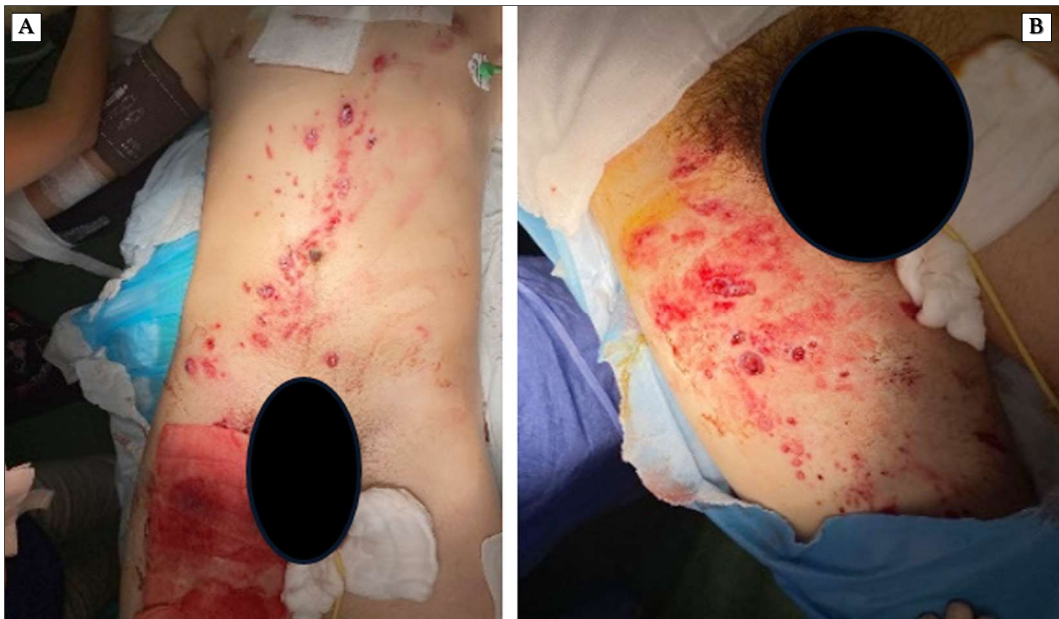

Figure 3. (A) Abdominal lesions; (B) Right thigh lesions

established protocols both at the incident site and within the hospital. An essential aspect of this process involves a multidisciplinary team consisting of medical personnel, police, fire brigades, and forensic experts.

Pre-hospital medical management poses challenges as patients may not exhibit obvious signs of significant injury but could experience sudden deterioration. Quick and decisive action is crucial, especially in cases involving

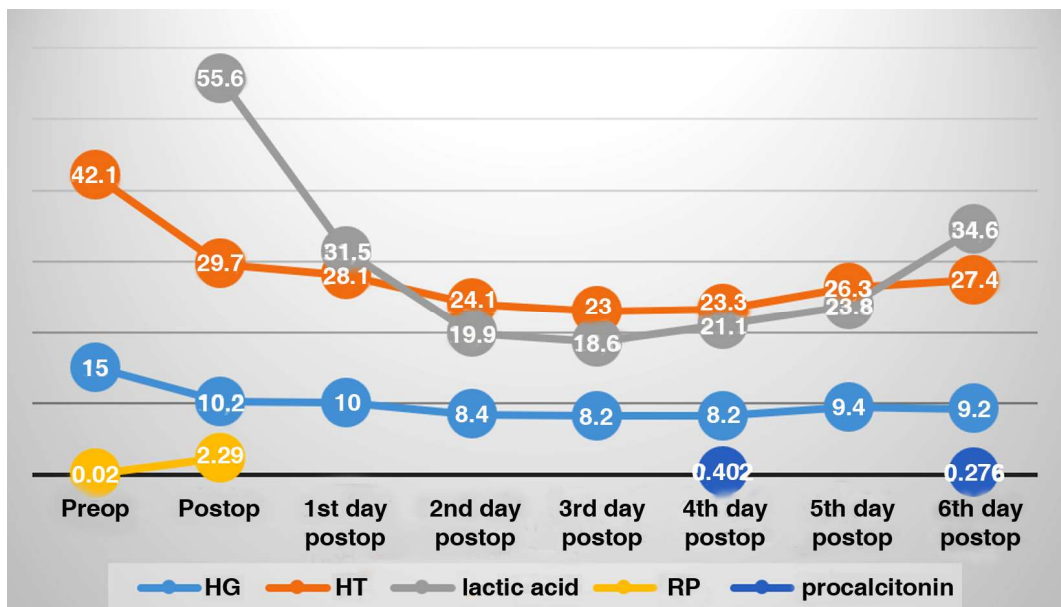


Figure 4. Evolution of biological parameters. HB=hemoglobin; HT=hematocrit; CRP=C-reactive protein; PREOP = before surgery; POSTOP = after surgery

traumatic amputations. In our patient's case, a rapid assessment of life-threatening injuries caused by the explosion was performed, and immediate control of bleeding at the affected limb level was carried out according to the guidelines of the Advanced Trauma Life Support (ATLS) protocol (9).

Upon arrival at the hospital, comprehensive clinical examinations and imaging investigations should be promptly conducted. However, there is no specific prioritization of various investigations, necessitating an individualized approach. It is important to note that Chien-Hung Liao et al. (10) studied the characteristics of computed tomography (CT) images for the detection of blunt bowel and mesenteric injuries. Their findings suggested that CT had limited predictive value in such cases, indicating that surgical evaluation should be considered when faced with uncertain blunt bowel and mesenteric injuries.

The literature proposes a three-level classification system for blast injuries. The first level, known as the primary lesion, refers to the interaction between the shock wave and the individual. The second level, called the secondary lesion, results from the impact of fragments originating from the explosive device or the surrounding environment. The third level, known as the tertiary lesion, involves changes in the person's position due to the kinetic force of the explosion. Additionally, N.J. Prat et al. (11) have described additional types of lesions, including those caused by burns, pathogens, radiation, and dust particles.

The Department of Defense (DoD) East Research Coordination Office (12) has classified explosive device injuries into five levels. The first three levels overlap with the classifications proposed by other authors. Level 4 includes injuries caused by the exploded material, such as burns and inhalation of dust. Level 5 pertains to the clinical consequences of the post-detonation environment, encompassing chemical burns, radiation exposure, and the presence of viral and bacterial pathogens.

The incident involved a curious 19-year-old who held a cartridge in his left hand and

attempted to cut it using a hand-held circular saw. The explosion occurred at a distance of the arm's length from the individual. According to the classification provided by the Department of Defense (DoD), the primary lesion in this case included lung barotrauma, abdominal piercing, and small amounts of intraperitoneal hemorrhage, without any injury to parenchymatous organs. Secondary lesions were evident, consisting of multiple penetrating wounds in the chest and abdomen, as well as injuries to both thighs. Additionally, a severe tertiary injury involved the traumatic amputation of the left hand.

HE Güven et al. (13) conducted a comparative analysis of injuries resulting from home-made bomb explosions and injuries caused by bullets. They observed that in both groups, the primary lesion was present in 33% of explosion cases and 50% of shotgun cases, often affecting the extremities. In explosion cases, injuries to the face were observed in 24% of the cases, and injuries to the chest and abdomen accounted for 14.88% of the cases. In this specific case, the primary injury was located on the forearm, accompanied by a penetrating wound in the abdominal wall.

Regarding the location and number of lesions, H.E. Güven et al. (13) identified a maximum of three concomitant sites in their study. However, in the case of the 19-year-old patient, five segments were involved: face, upper left arm, chest, abdomen, and bilateral thighs. Despite burns being commonly associated with explosions, this particular patient did not exhibit burns on any of the aforementioned segments, distinguishing his injuries from the observations made by H.E. Güven et al.

After conducting a comprehensive assessment of the patient, surgical intervention was performed. Young-Jun Ki et al. (14) conducted a study evaluating the effectiveness and safety of laparoscopy in patients with blunt abdominal trauma, which showed positive outcomes in terms of reduced blood loss during surgery, shorter hospital stay, decreased missed injuries, and lower morbidity rates. However, in this case, laparotomies were preferred to avoid fur-

ther damage caused by the blast wave. A similar individualized approach was taken by our medical team in managing traumatic injuries resulting from projectile usage (15).

Postoperative follow-up involved clinical examinations, laboratory evaluations, and ultrasound assessments. Considering the patient's stable hemodynamic status, if available, contrast-enhanced ultrasound (CEUS) could have been utilized. CEUS is a non-invasive and cost-effective imaging technique that does not expose the patient to ionizing radiation and does not cause contrast nephropathy, as the contrast agent is metabolized by the liver (16). For patients with blunt polytrauma, CEUS has demonstrated high sensitivity in identifying and monitoring lesions, surpassing the capabilities of regular ultrasound.

Enrico Cicuttin et al. (17) discussed several aspects related to the use of prophylactic antibiotics. Goldberg et al. (18) recommended a 24-hour antibiotic prophylaxis for penetrating abdominal trauma only in the presence of hollow viscus injury. Meanwhile, Jang et al. (19) suggested that if surgery is not required, antibiotic prophylaxis is unnecessary. Considering the penetrating lesions and small bowel perforation in this case, the decision was made to administer 24 hours of prophylactic broad-spectrum antibiotics.

Acute traumatic coagulopathy is a critical complication frequently observed in cases of polytrauma, significantly impacting patient mortality. This condition arises from interconnected pathophysiological mechanisms triggered during hemorrhagic shock, involving the generation of thrombin-thrombomodulin complexes related to tissue injury, which subsequently activate anticoagulant and fibrinolytic pathways (7). Contributing factors to this complication include acidosis, hypothermia, hypoperfusion, intravascular fluid administration, and consumption of coagulation factors, collectively exacerbating its severity along with patient age and comorbidities (20). Bleeding is a leading cause of death in over 30% of polytrauma patients, but direct hemostasis can address this issue. However, specialized coagu-

lation testing methods such as rotational thromboelastometry (ROTEM) and thromboelastography (TEG), described in the literature, may not be universally available in all treatment centers (21). Sophie Thorn et al. (22) conducted a systematic review to identify prediction models for acute traumatic coagulopathy. They presented and analyzed various models, including The COAgulopathy of Severe Trauma (COAST) Score, the Trauma-Induced Coagulopathy Clinical Score (TICCS), the Prediction of Acute Coagulopathy of Trauma (PACT), and the Bayesian Network Model. However, none of these models have been validated as reliable and widely applicable in clinical practice.

This complication has been documented in existing medical literature and can be referred to by various names, such as acute traumatic coagulopathy, early coagulopathy of trauma, or acute coagulopathy of trauma-shock (3,23, 24). Although our patient did not experience this specific complication, it is important to highlight its existence.

Another critical aspect that needs to be addressed is the underlying cause behind the patient's severe self-inflicted injuries. While there were no explicit signs of suicidal ideation, it is hypothesized that the COVID-19 pandemic lockdown, lack of communication, and limited social interaction may have influenced the patient to engage in such dangerous behavior. It is crucial to recognize that such circumstances can potentially lead to the development of post-traumatic stress disorder (PTSD), with a risk estimated between 30% to 40% following exposure to traumatic events, including those associated with the COVID-19 pandemic (25).

Conclusion

Individuals affected by accidental blast injuries may exhibit visually evident wounds, such as traumatic amputations. However, it is vital to exercise caution and perform meticulous monitoring and examination to identify additional life-threatening injuries, such as internal bleeding and barotraumatic lesions, which may

present based on the magnitude and properties of the explosions. To effectively manage these complex injuries, it is crucial to establish local protocols for blast injuries and adopt a comprehensive approach that combines surgical interventions and conservative treatments within the intensive care unit. This integrated approach is necessary to enhance survival rates and improve overall outcomes.

Conflicts of Interest

The authors have declared no conflicts of interest in relation to this study.

Funding

This research was not supported by any external funding sources.

Ethical Statement

Informed consent was been obtained from the patient to publish this article.

References

- Ritenour AE, Blackburne LH, Kelly JF, McLaughlin DF, Pearse LA, Holcomb JB, et al. Incidence of primary blast injury in US military overseas contingency operations: a retrospective study. *Ann Surg.* 2010;251(6):1140-1144.
- Kapur GB, Hutson HR, Davis MA, Rice PL. The United States twenty-year experience with bombing incidents: implications for terrorism preparedness and medical response. *J Trauma.* 2005;59(6):1436-44.
- Spahn DR, Bouillon B, Cerny V, Duranteau J, Filipescu D, Hunt BJ, et al. The European guideline on management of major bleeding and coagulopathy following trauma: fifth edition. *Crit Care.* 2019;23(1):98.
- Eastridge BJ, Mabry RL, Seguin P, Cantrell J, Tops T, Uribe P, et al. Death on the battlefield (2001-2011): implications for the future of combat casualty care. *J Trauma Acute Care Surg.* 2012;73(6 Suppl 5):S431-7.
- Brännström A, Rocksén D, Hartman J, Nyman N, Gustavsson J, Arborelius UP, et al. Abdominal Aortic and Junctional Tourniquet release after 240 minutes is survivable and associated with small intestine and liver ischemia after porcine class II hemorrhage. *J Trauma Acute Care Surg.* 2018;85(4):717-724.
- Borger van der Burg BLS, van Dongen TFCF, Morrison JJ, Hedeman Joosten PPA, DuBose JJ, Hörer TM, et al. A systematic review and meta-analysis of the use of resuscitative endovascular balloon occlusion of the aorta in the management of major exsanguination. *Eur J Trauma Emerg Surg.* 2018;44(4):535-550.
- Tărnăceriu CC, Hurjui LL, Florea ID, Hurjui I, Gradinaru I, Tanase DM et al. Immune Thrombocytopenic Purpura as a Hemorrhagic Versus Thrombotic Disease: An Updated Insight into Pathophysiological Mechanisms. *Medicina (Kaunas).* 2022;58(2):211.
- Hăisan A, Măirean C, Lupuşoru SI, Tărnăceriu C, Cimpoeşu D. General Health among Eastern Romanian Emergency Medicine Personnel during the Russian-Ukrainian Armed Conflict. *Healthcare (Basel).* 2022;10(10):1976.
- American College of Surgeons. Chapter I: Initial assessment and management. In *Advanced Trauma Life Support (ATLS®)*, 10th ed. American College of Surgeons: Chicago, IL, USA. 2018. p. 2-22.
- Liao CH, Hsieh FJ, Chen CC, Cheng CT, Ooyang CH, Hsieh CH, et al. The Prognosis of Blunt Bowel and Mesenteric Injury-the Pitfall in the Contemporary Image Survey. *J Clin Med.* 2019;8(9):1300.
- Prat NJ, Daban JL, Voiglio EJ, Rongieras F. Wound ballistics and blast injuries. *J Visc Surg.* 2017;154 Suppl 1:S9-S12.
- Phipps H, Mondello S, Wilson A, Dittmer T, Rohde NN, Schroeder PJ et al. Characteristics and Impact of U.S. Military Blast-Related Mild Traumatic Brain Injury: A Systematic Review. *Front Neurol.* 2020;11:559318.
- Güven HE, Bilge S, Aydın AA, Eryılmaz M. Comparison of the non-mortal gunshot and handmade explosive blast traumas during a low-intensity conflict on urban terrain. *Turk J Surg.* 2018;34(3):221-224.
- Ki YJ, Jo YG, Park YC, Kang WS. The Efficacy and Safety of Laparoscopy for Blunt Abdominal Trauma: A Systematic Review and Meta-Analysis. *J Clin Med.* 2021;10(9):1853.
- Hăisan A, Dumea M, Ursaru M, Bulat C, Cimpoeşu DC. A today victim of second world war. *Rev Med Chir Soc Med Nat Iasi.* 2015;119(2):437-40.
- Di Serafino M, Iacobellis F, Schillirò ML, Ronza R, Verde F, Grimaldi D, et al. The technique and advantages of contrast-enhanced ultrasound in the diagnosis and follow-up of traumatic abdomen solid organ injuries. *Diagnostics (Basel).* 2022;12(2):435.
- Cicuttin E, Sartelli M, Scozzafava E, Tartaglia D, Cremonini C, Brevi B, et al. Antibiotic prophylaxis in torso, maxillofacial, and skin traumatic lesions: a systematic review of recent evidence. *Antibiotics (Basel).* 2022;11(2):139.
- Goldberg SR, Anand RJ, Como JJ, Dechert T, Dente C, Luchette FA, et al. Prophylactic antibiotic use in penetrating abdominal trauma: an Eastern Association for the Surgery of Trauma practice management guideline. *J Trauma Acute Care Surg.* 2012;73(5 Suppl 4):S321-5.
- Jang JY, Kang WS, Keum MA, Sul YH, Lee DS, Cho H, et al. Antibiotic use in patients with abdominal injuries: guideline by the Korean Society of Acute Care Surgery. *Ann Surg Treat Res.* 2019;96(1):1-7.
- Savioli G, Ceresa IF, Macedonio S, Gerosa S, Belliato M, Iotti Ga et al. Trauma coagulopathy and its outcomes. *Medicina (Kaunas).* 2020;56(4):205.
- Davenport R, Manson J, De'Ath H, Platton S, Coates A, Allard S, et al. Functional definition and characterization of acute traumatic coagulopathy. *Crit Care Med.* 2011;39(12):2652-8.
- Thorn S, Güting H, Maegele M, Gruen RL, Mitra B. Early Identification of Acute Traumatic Coagulopathy Using Clinical Prediction Tools: A Systematic Review. *Medicina (Kaunas).* 2019;55(10):653.
- Schöchl H, Frietsch T, Pavelka M, Jámor C. Hyperfibrinolysis after major trauma: differential diagnosis of lysis patterns and prognostic value of thrombelastometry. *J Trauma.* 2009;67(1):125-31.
- Maegele M, Schöchl H, Cohen MJ. An update on the coagulopathy of trauma. *Shock.* 2014;41 Suppl 1:21-5.
- Maftei A, Dănilă O, Măirean C. The war next-door-A pilot study on Romanian adolescents' psychological reactions to potentially traumatic experiences generated by the Russian invasion of Ukraine. *Front Psychol.* 2022;13:1051152.