

Thoracic Penetrating Wounds with Cardiac Injury: A Single-Center Experience

Gheorghe Rojnoveanu^{1*}, Radu Gurghis^{1,2}, Ion Gagauz^{2,3}, Tatiana Malcova^{1,2}

¹"Nicolae Anestiadi" Department of Surgery no. 1, "Nicolae Testemitanu" State University of Medicine and Pharmacy, Chisinau, Republic of Moldova

²Laboratory of Hepato-Pancreato-Biliary Surgery, "Nicolae Testemitanu" State University of Medicine and Pharmacy, Chisinau, Republic of Moldova

³Institute of Emergency Medicine, Chisinau, Republic of Moldova

*Corresponding author:
Professor Rojnoveanu Gheorghe
Str. Toma Ciorba, no. 1, Chisinau
Republic of Moldova
Phone: +(373) 79467017
E-mail: gheorghe.rojnoveanu@usmf.md

Rezumat

Plăgi penetrante toracice cu leziuni cardiace: o experiență cu un singur centru

Introducere: În ultimile decenii protocoalele de management al pacienților cu leziuni cardiace penetrante au suferit o tranziție spectaculoasă. Cu toate acestea, leziunile cardiace penetrante (LCP), chiar și astăzi, reprezintă o problemă medicală importantă și o cauză de mortalitate semnificativă.

Metode: Studiu retrospectiv, 2005-2020, bazat pe analiza a 41 traumatizați cu plăgi toracice și leziuni cardiace, internați la IMSP Institutul de Medicină Urgentă, Chișinău. Vârsta medie 45.8 ± 8.9ani, B:F/19.5:1. Mecanismul traumei: plăgi prin împușcare (17.1%, n=7) și prin armă albă (82.9%, n=34). Preoperator s-a efectuat: ECG, Rx toracic, USG-FAST, pleurotomie, puncție pericardică, toracoscopie.

Rezultate: Hemodinamic instabili la spitalizare au fost 36(87.8%) pacienți, 19(52.8%) – transferați, imediat în sala de operație. S-au practicat următoarele tipuri de abord: toracotomie antero-laterală stângă – 26(63.4%), antero-laterală dreaptă – 13(31.7%), postero-laterală stângă – 2(4.9%). S-au constatat leziuni nepenetrante în 5(12.2%) și penetrante în 36(87.8%) cazuri, cel mai frecvent lezat ventriculul drept. Leziuni asociate intratoracice s-au înregistrat în 29(70.7%) cazuri: parenchim pulmonar – 25(86.2%), a.mamară internă – 3(10.3%), a.intercostală – 1(3.5%). Durata medie de spitalizare a fost 13.2±4zile, inclusiv ATI – 2.9±1.2. Letalitatea – 7(17.1%).

Concluzii: Cardiorafia aplicată în timp reușit, severitatea leziunii

Received: 30.03.2022
Accepted: 26.05.2022

cardiace și magnitudinea pierderii sangvine determină rata de supraviețuire de 82.9% în studiu. Letalitatea crește proporțional cu gradul severității leziunii, a șocului hipovolemic și lezarea compartimentelor drepte vs stângi.

Cuvinte cheie: plagă toracică, leziune cardiacă, stabilitatea hemodinamică, cardiorafie, tratament chirurgical

Abstract

Background: Management protocols for patients with penetrating cardiac injury have undergone a dramatic transition during the last decades. However, even today cardiac trauma remains a major medical problem.

Methods: Retrospective single-center case series study, 41 patients with precordial wounds hospitalized at the Institute of Emergency Medicine, Chisinau, period 2005-2020. Mean age - 45.8 ± 8.9 years, M:F/19.5:1. Traumatic event: stabbing (82.9%,n=34) or gunshot wound (17.1%,n=7). Preoperative paraclinical examinations: electrocardiography, chest X-ray, FAST, pleurotomy, pericardial puncture, and thoracoscopy.

Results: 36 (87.8%) patients were hemodynamically unstable on hospitalization, and 19 (52.8%) were immediately transferred to the operating room. Preferred surgical access: left anterolateral thoracotomy - 26 (63.4%), right anterolateral thoracotomy - 13 (31.7%), and left posterolateral thoracotomy - 2 (4.9%). Non-penetrating lesions were discovered in 5 (12.2%) while penetrating trauma in other 36 (87.8%) cases, most frequently the right ventricle being injured. Additional intrathoracic lesions discovered in 29 (70.7%) patients: pulmonary parenchyma rupture - 25 (86.2%), internal mammary artery injury - 3 (10.3%), and intercostal artery injury - 1 (3.5%). The average length of stay was 13.2 ± 4 days, including stay in the Intensive Care Unit - 2.9 ± 1.2. Mortality rate - 17.1% (n=7).

Conclusions: Successful cardiac suture determined the survival rate of 82.9%. Lethality increases proportionally to the severity of the cardiac injury, the volume of blood loss, and damage to the right vs left heart chambers.

Key words: thoracic wound, cardiac injury, hemodynamic stability, cardiac suture, surgical treatment

Introduction

During the last decades, management protocols for patients with penetrating cardiac injury (PCI) have undergone a dramatic transition from simple pericardiocentesis to emergent thoracotomy with myocardial defect suturing. However, even today PCIs remain a major medical problem and an important cause of mortality (1-3).

Good clinical management of patients with

cardiac injury requires the involvement of a multidisciplinary team, including an emergency physician, trauma surgeon, cardiologist, cardiac surgeon, medical imaging doctor, cardiovascular perfusionist, and anesthesiologist, the treatment result being dependent on initial resuscitation, wound characteristics and applied surgical technique (2,4). Even so, all the general surgeons involved in emergency medical care should be prepared to manage this group of victims, recognize the injury, and

be familiar with the actual diagnostic and therapeutic protocols if the specialist in the field is not immediately available (3).

Material and Method

A retrospective study was conducted, between 2005-2020, and a total of 41 patients with PCIs hospitalized in the Emergency Medicine Institute, Chisinau were included. The following variables were registered: patients' sex and age, trauma mechanism, clinical presentation, diagnostic procedures, surgical access, topography of cardiac lesion, applied procedure, associated injuries, morbidity, and mortality. The inclusion criteria were the presence of a cardiac wound confirmed during the surgery and patients' age > 18 years old.

All the procedures performed in the study were in accordance with ethical standards. Ethical approval for this study was obtained from the Research Ethics Committee of "Nicolae Testemitanu" State University of Medicine and Pharmacy of the Republic of Moldova (nr. 1 from 24.10.2022).

Results

The sex ratio M:F ratio was 19.5:1, and the mean age - 45.8 ± 8.9 years (range: 19-58 years).

Gunshot wounds were registered in 7 (17.1%) cases, while stab wounds - 34 (82.9%). The following items and weapons involved in injury were identified: construction nail - 1 (2.94%), spear - 1 (2.94%), and knife - 32 (94.12%).

Hemodynamic stability was the main parameter in determination of diagnostic and treatment strategy, the signs of instability being hypotension (BPs <90 mmHg), tachycardia (heart rate >120 beats/min), and absence of a positive clinical response to fluid resuscitation (bolus of 1000-2000 ml of crystalloids).

The initial fluid resuscitation was performed with max. 1.5 l bolus of intravenous crystalloid and subsequent slower fluid administration rate for maintenance of systolic blood pressure values. It is worth mentioning that no „massive” intravenous therapy was used; it

was demonstrated that this strategy might increase the volume of blood loss (4). In addition, aggressive early resuscitation with predominantly saline-based fluids may be associated with cardiac dysfunction, development of abdominal compartment syndrome, acute respiratory distress syndrome (ARDS), multiple organ dysfunction, and increased mortality.

According to hemodynamic stability, the patients were divided into two groups: group A - trauma patients hemodynamically unstable on admission, 36 (87.8%) cases, including 17 (41.5%) patients who were stabilized by fluid resuscitation and transfusion, and 19 (46.3%) patients who were immediately transferred to the operating room with no additional clinical and paraclinical investigations; and group B - trauma patients hemodynamically stable on admission, 5 (12.2%). In all the cases wounds were localized within the cardiac compartment, or precordium, on the anterior thoracic wall; through-and-through wounds were not registered (*Fig. 1*).

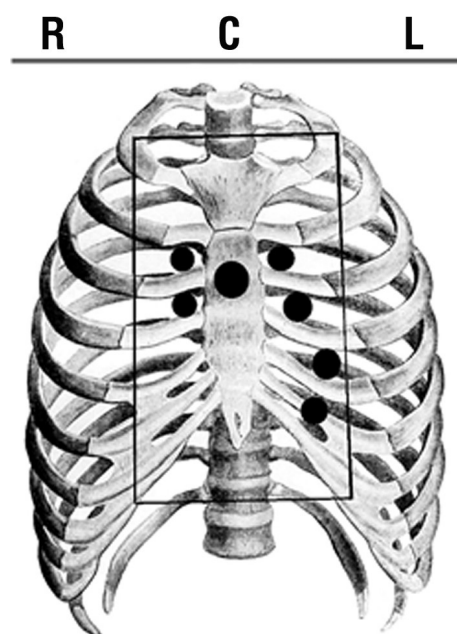


Figure 1. Location of heart wounds within the cardiac box in the patients from the lot of study: n=14(34.1%) on the right side; n=26(63.4%) on the left side; n=1(2.4%) through the sternum (R - right side; C - central part; L - left side)

Intraoperatively, in 5(12.2%) cases non-penetrating injuries were identified, specifically, in three patients only pericardial injury was found, and in two – myocardial injury. In 36 (87.8%) cases penetrating injuries were detected, the right ventricle was the most frequently injured, followed by the left ventricle; coronary artery lesions were not registered.

The set of performed paraclinical evaluation tests was not constant, it was dictated by the technical possibilities of the institution and the patient's hemodynamic stability. Therefore, 19 shock patients (systolic blood pressure \leq 90 mmHg after volume resuscitation or the presence of signs of cardiac tamponade on admission) underwent emergency thoracotomy. Twenty-two other patients underwent preoperative para-clinical investigations, including electrocardiography (ECG), chest radiography, and pericardiocentesis if required.

Electrocardiographic examination performed in 22 (53.7%) patients revealed sinus tachycardia in 7 (31.8%) cases, ST-segment elevation – 6 (27.3%), incomplete right bundle branch block – 4 (18, 2%), subepicardial ischemia – 3(13.6%), and decreased voltage – 2 (9.1%).

Chest radiography performed in 22(53.7%) patients revealed hemopneumothorax in 7(31.8%) cases and suspicion of cardiac tamponade in 11(50%) cases. In 4(18.2%) cases no pathological imaging changes within the cardiopulmonary area were detected.

Pericardiocentesis, as a diagnostic and therapeutic maneuver in patients suspected of cardiac tamponade, was performed in 7 (17.1%) cases. In all cases fresh blood was obtained; evacuation of the pathological fluid accumulated in the pericardial sac led to a temporary improvement of clinical vital parameters.

During the first years of the study, the hospital did not have a 24/24 echocardiography service, and later, after its introduction, it was not used in the evaluation of trauma patients in the emergency room. Therefore, none of the patients in this study were evaluated preoperatively by echocardiography. However, the investigation was used as part of the post-

operative evaluation in 100% of cases.

All trauma patients with thoracic wounds suspected of heart injury underwent surgery. Extracorporeal circulation was never used, and all injuries were repaired by general surgeons. The following surgical accesses were used: left anterolateral thoracotomy – 26(63.4%), right anterolateral thoracotomy – 13(31.7%) (in patients with thoracic wounds to the right side from the sternum), and left posterolateral thoracotomy – 2(4.9%).

Intraoperatively, penetrating cardiac injuries were found in 36 (87.8%) cases, the right ventricle was the most frequently injured (n = 16; 44.4%), followed by the left ventricle (n = 11; 30.6), the right atrium (n = 7; 17.1%), and left atrium (n = 1; 2.8%). In one case, a superior vena cava injury was found (2.8%). Coronary artery lesions were not detected.

In unstable patients who required emergency thoracotomy the volume of intrathoracic hemorrhage assessed intraoperatively was 1500-2000 ml. However, the volume of blood identified in the thoracic cavity in stable and responsive patients was less than 750 ml (p=0.0017). Hemorrhagic pericardial effusion was discovered intraoperatively in 21(51.2%) cases.

The main strategy for the intraoperative volume resuscitation of these critically injured patients was based on the transfusion of blood products, namely, packed red blood cells (PRBC) and fresh frozen plasma (FFP), on average, 4 units of PRBC and 2 units of FFP and limited use of crystalloids to avoid dilutional coagulopathy.

In all cases the digital occlusion of the myocardial injury was used as the method of temporary intraoperative homeostasis, while the final repair required performing cardiorrhaphy with non-absorbable suture: either interrupted simple or mattress suture or continuous suture was applied. The stitches were passed deep through the myocardium and successively passed under the finger providing the primary hemostasis and then knotted as the finger released the sutured area (*Fig. 2, Fig. 3*).

Massive bleeding determined by severe

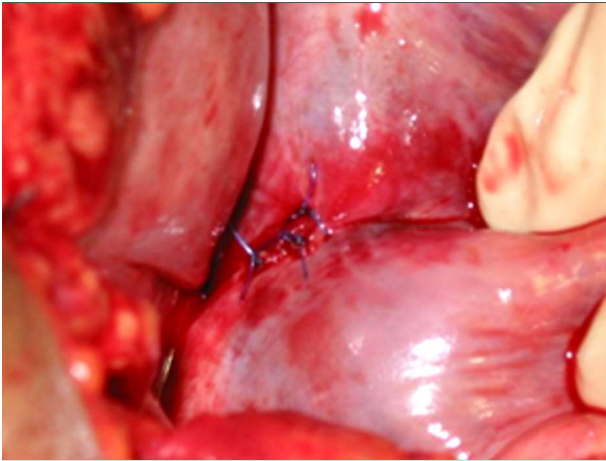


Figure 2. Cardiorrhaphy technique at the level of the right atrium: interrupted sutures

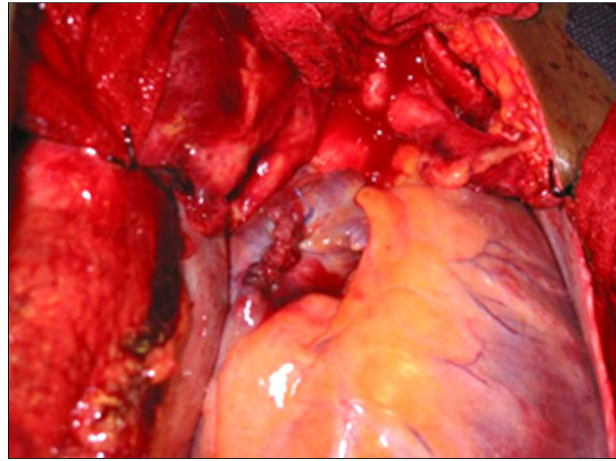


Figure 3. Cardiorrhaphy technique at the level of the right atrium: continuous sutures

cardiac injury caused cardio-respiratory arrest in 3 cases. Cardiopulmonary resuscitation maneuvers with direct cardiac massage were efficient in all cases. However, patients who suffered perioperative cardiac arrest had a high mortality rate (n=2, 66.7%).

In 12 (29.27%) cases isolated trauma was diagnosed, in other cases, the cardiac injury was associated with other intrathoracic lesions: pulmonary parenchymal lesion – 25 (86.2%), lesion of the internal mammary artery – 3 (10.3%) or of the intercostal artery – 1 (3.5%). Pericardial fenestration allowing drainage of the pericardial cavity and pleural drainage were performed in all cases.

In 65.6% (n=27) cases, pleural drainage was removed on the 4-5th postoperative day after radiological control. In all other cases because of the persistence of serous-hemorrhagic fluid, it was maintained for up to 12 days.

Uneventful clinical evolution was registered in 5 (12.2%) cases. Postoperative morbidity was 87.8% (n=36) due to pulmonary, cardiac, or systemic complications. Twenty-nine (70.73%) patients developed postoperative pneumonia and benefited from complex antibiotic therapy with two broad-spectrum antibacterial drugs (Cephalosporins + Nitroimidazoles), and in all cases, favorable outcome was registered. Other postoperative complications were also registered, such as pleural effusion (n=7),

acute respiratory distress syndrome (n=2), and persistence of the myocardial infarction area on the ECG (n=3). Overall mortality rate – 17.03% (n=7).

All trauma-related deaths occurred within the first 12 hours after the event due to bleeding and severe hypovolemic shock (n=4) and massive right ventricular laceration (n=3); six patients died in the operating room, and one was in the Intensive Care Unit (ICU). The median length of a hospital stay was 13.2 ± 4 days (range: 4-21 days), including the stay in ICU – 3.12 ± 0.7 days.

Clinical follow-up of the treatment results was performed until the patients were discharged from the hospital. The socio-economic conditions of the population and the limited availability of the echocardiography service did not allow the collection of prospective information about the presence of residual intracardiac lesions. The 30-day survival is, as well, not available due to the mentioned socio-economic reasons.

Discussions

Chronologically, a large number of heart injuries were recorded during the great military conflicts of the last century (5-7). At the same time, due to the acts of violence, traffic accidents, terrorist attacks and interpersonal conflicts that represent one of the faces of the

21st century; the incidence of heart wounds remains negligible today (8-10).

Abdominothoracic wounds with cardiac lesions are a major cause of lethality and are considered one of the most severe traumatic injuries. According to the latest statistics in the field, more than 90% of trauma patients die before they arrive at the hospital (pre-hospital mortality) (8,9), with a 50% in-hospital mortality among the initial survivors (10-13). The high level of general mortality is determined by the variable clinical presentation and the heterogeneity of the associated lesions, poor experience in recognizing this type of trauma, and defect management process (10). In addition, it was demonstrated there is a dependence between the mortality rate and the hemodynamic status of patients, the type of weapon used, the characteristics of the wound, the intraoperative findings, and the complexity of the surgical procedure (12,14).

The progress and improvement of the quality of medical services applied in the management of trauma patients are indisputable: the volume of pre-hospital care significantly increased; transportation time to the hospital decreased; new diagnostic methods are introduced; resuscitation measures, quality of the anesthesia and the surgical techniques boosted, all these contributing to the enhancement of the treatment results (1,3,9,12,15). However, PCIs remain a surgical challenge requiring maximum promptness in decision-making, high safety of applied surgical procedures (16), and continuous upgrade of management guidelines used in trauma centers (17).

Identification of the wound etiology is important, because the choice of successful treatment tactic depends on the identification of the lesion type and recognition of the cardiac dysfunction developed in this case (1-3). Cardiac trauma is caused primarily by stabbing and gunshot (18-22). It is worth mentioning that, due to major pericardial defects, massive myocardial damage and multicameral lesions mortality rate in gunshot injury of the heart remains high (70-90%) (19,20,22).

Cardiac wounds can be caused by bone

fragments in the case of ribs or sternum fractures too. Iatrogenic complications, for instance, during the installation of intracardiac devices (cardiac pacemaker, coronary stent, central venous catheter, pulmonary artery catheter) or those following treatment procedures for arrhythmias causing cardiac trauma are also described. Although rare, they should be included in illness etiology (3,23). Epidemiological observational studies have shown that people of any sex and age might suffer a heart wound. However, most cases are reported in males of 20-30 years (13,14,20,24).

Due to its specific and exclusive function, heart trauma is associated with unique physiological consequences, bleeding and pericardial tamponade being considered the most distinctive ones (14,18). From 30% to 80% of victims die instantly from tamponade or cataclysmic hemorrhage (16,20,22). Blood loss in heart trauma victims can range from a minor hemorrhage in the myocardium due to contusion to a massive hemorrhage in the pleural cavity with a massive hemothorax that causes death at the scene of tragedy before transportation to the hospital (3).

Cardiac tamponade is a true medical emergency that requires prompt recognition and immediate treatment for life-saving. Cardiac tamponade produced by pericardial effusion is a clinical syndrome characterized by the accumulation of fluid in the pericardial space, an inelastic sac with low compliance. This phenomenon occurs quickly; because the pericardial sac does not dilate enough, it can accumulate approximately 150–250 ml of blood. As a result, the intrapericardial pressure increases, determining the reduction of the venous return and preventing the diastolic filling of the heart chambers. It causes a decrease in ejection fraction, thus dramatically decreasing cardiac output and blood pressure. Under these conditions, by adrenergic stimulation the heart rate and cardiac contractility increase allowing temporary maintenance of cardiac function (3,11,14,22,23,25). However, as blood continues to accumulate in the pericardial space, decompensation occurs rapidly due to the increasing intrapericardial

pressure with compression of the ventricles and alteration of their filling. As a result, cardiac output decreases dramatically, causing progressive hypotension and subsequent cardiorespiratory arrest (23,26). Despite the existing fact that the pathophysiological effects of cardiac tamponade are obvious, there are several retrospective studies that have demonstrated some beneficial effects of this phenomenon. Probably, the protective effect of cardiac tamponade can be explained by the reduction of hemorrhage loss, thus preventing installation of irreversible shock and allowing the patient transportation to a trauma center in life (27). In any case, prospective multicenter studies are necessary to confirm the results outlined above regarding the greater survival rate of the trauma patients who develop cardiac tamponade; however, it is already clear that the pericardial tamponade may manifest both protective and damaging effects (28).

The clinical presentation of trauma patients with a cardiac wound is variable, including a wide range of cardiovascular signs from hemodynamic stability to catastrophic lesions, which affect one or all of the heart chambers and lead to acute cardiovascular collapse and cardiorespiratory arrest (14,23,27,29). As a result, on arrival at the hospital, all patients suspected of penetrating thoracic trauma require a rapid and careful physical examination to decide whether any intrathoracic organ is damaged. Physical examination of the patient with a potential heart injury should follow the protocols of Advanced Trauma Life Support (ATLS) of the American College of Surgeons (ACS). The primary assessment of the traumatized includes: a) observation of vital signs; b) estimation of respiratory function and ensuring airway permeability; and c) evaluation of the cardiovascular system. Secondary assessment involves inspection for obvious chest lesions, recognition of signs of cardiac tamponade (e.g., jugular venous distension), evaluation of pulse characteristics, and auscultation to determine decreased heart sounds and deafening murmur. Early clinical suspicion of a possible

cardiac injury should be based on: a) assessment of the site of penetration (visible trauma); b) detection of the signs of shock (agitation, weakness, dizziness, diaphoresis, cold extremities, tachypnea, tachycardia, hypotension); and c) cardiac tamponade recognition (Beck triad: hypotension, jugular venous distension, and deafening murmur) (30,31).

Examination of the lesion site is a very important component of the physical exam of a trauma patient. The probability of a heart injury is higher if the wound is localized within the limits of the cardiac compartment, or precordium (13,14,20,23). Thus, a penetrating wound within the boundaries of the cardiac box is considered to be predictive of heart damage (32). However, the definitive role of trauma mark assessment in the clinical examination of a patient with a penetrating chest wound remains unclear, as penetrating thoracic trauma from outside the precordium does not completely rule out this type of injury (13,32,33). We can conclude that any penetrating injury to the chest or upper abdomen should alert the doctor about the likelihood of a heart lesion (20,23,32,34).

Comparing the level of vulnerability of heart chambers in trauma patients, it seems that the right ventricle is most frequently affected. It can be explained by the specific projection of the chambers of the heart on the cardiac box (23). The right ventricle is injured in 43% of cases, followed by the left ventricle – 34%, the right atrium – 18%, and the left atrium – 5%; large vessels are affected in only 3.3% of cases (20,23,35-37). It is worth mentioning that we obtained the same final data in the present study. According to Kang et al (2009), multicameral involvement of the heart is recorded in 18% of cases, while coronary artery lesions in less than 5% (23).

Understanding the morphophysiological peculiarities of the cardiac muscle it seems obvious that due to the thin wall of the right ventricle its lesions tend to bleed more, while in the case of left ventricular lesions, especially in the case of small defects, bleeding may stop spontaneously (10,14,36). Atrial lesions can

bleed longer due to the thin wall and low pressure in these compartments (19, 33, 38).

Paraclinical investigations used for examination of trauma patients are selected strictly according to hemodynamic stability. In a patient suspected for cardiac wound and hemodynamically unstable, Focused Assessment with Sonography for Trauma (FAST) scan and emergent thoracotomy are the first and unique suitable treatment options. However, in the hemodynamically stable patients who present with chest wounds or those responsive to volume replenishment, additional diagnostic methods are used for evaluation (2,8,9,38).

A general assessment of a trauma patient suspected of cardiac injury usually includes non-invasive methods such as ECG, chest radiography, ultrasonographic examination, such as FAST or echocardiography, and computed tomography (CT) (21,24,39,40). According to Wu Y (2019), CT is considered the gold-standard imaging tool for the evaluation of hemodynamically stable victims suspicious of cardiac lesion due to its high sensitivity and noninvasive nature. It should be routinely used in all hemodynamically stable patients (21). However, because of service unavailability 24/24, it was not used in the evaluation of traumatized patients in the emergency room.

In cases when the ultrasonographic examination is not available or the obtained results are doubtful, a sub-xiphoid pericardial window can be recommended to discover hemopericardium (22,23). Sub-xiphoid pericardial window, described for the first time by Larrey in the 1800s (40), is an invasive technique for the diagnosis of cardiac injury. It requires the patient to be subjected to general anesthesia, the procedure being performed in an operating room. Numerous studies in the field have demonstrated the high diagnostic potential of this method, it is considered safe, quick, and precise in the examination of trauma patients (33,42,43). Unsurprisingly, for many decades it was considered the gold standard diagnostic tool. However, due to the large implementation of ultrasonographic examination, its role has diminished nowadays (30).

Pericardiocentesis, as an invasive procedure, is not currently recommended for diagnostic purposes due to ambiguous interpretation of the results, high probability of obtaining false-negative or false-positive results, recorded in about 50% of cases (44, 45), and risk of developing complications such as serious damage of the heart chambers or coronary arteries, lungs or liver lesion. However, this method is applied in surgical practice as a curative measure for the initial stabilization of patients with cardiac tamponade (3).

It is worth mentioning that the development of a specific diagnostic algorithm would greatly facilitate the decision-making process and choosing the optimal curative strategy.

Management of Cardiac Injury

All trauma patients should certainly benefit from routine examinations according to the ATLS protocol. The confirmation of a cardiac wound will require a special treatment strategy (13), the treatment approach being determined by the hemodynamic condition of the patient (12,19,34,35,37,46).

If the patient is hemodynamically unstable, pericardiocentesis may be recommended as the first treatment step; however, the surgery remains the „cornerstone” of the definitive cure in this case (44). Pericardiocentesis involves the placement of the catheter in the pericardial sac for the intermittent evacuation of accumulated blood, thus allowing hemodynamic stabilization and the improvement of vital clinical parameters. However, pericardiocentesis cannot serve as a definitive therapeutic measure (13,26,38,45).

Emergency department thoracotomy or resuscitative thoracotomy is another therapeutic measure that can be applied to stabilize the patient. However, the clinical results of the intervention are controversial with a survival rate of 1-30%, depending on the characteristics of the study group. According to the Western Trauma Association (WTA) guideline, this should only be considered for pulseless victims and those who received cardio-

pulmonary resuscitation for less than 15 minutes (1,10,13,14). Therefore, trauma patients with obvious signs of cardiac tamponade or hemodynamic instability should be transferred immediately to the operating room for thoracotomy or median sternotomy, while hemodynamically stable trauma patients should be transferred to the operating room after a full examination and definitive diagnosis of the cardiac lesion (8,9,13,26).

Foreign bodies suspected of penetration into major cardiovascular structures should be left in place temporarily and removed in conditions of the operating room under the guidance of specialized medical staff, as their „blind” removal increases the risk of cardiac tamponade developing (13,26,38).

Several surgical accesses, such as median sternotomy, bilateral anterior thoracotomy, and left anterolateral or posterolateral thoracotomy can be used as routes to the heart and mediastinum. Each access has its advantages and disadvantages, and the choice depends on the practical work experience of the surgeon (10,12,14,15,22).

The median sternotomy (Duval incision) provides the best access to the heart and large vessels, anatomical structures of the mediastinum, and pleural cavity. Moreover, it can be easily performed by both cardiothoracic surgeons or general surgeons (46). At the same time, it is the preferred approach in hemodynamically unstable patients (16,47) and stable ones, in whom the hemopericardium is confirmed by FAST or on echocardiography, while other lesions are excluded (23,48). Because bilateral transverse thoracosternotomy provides wide access to the anterior mediastinum and both pleural cavities, it is performed in hemodynamically unstable patients, when the probability of a transmediastinal lesion is very high (20,49). Left anterolateral thoracotomy (Spangaro's incision) with or without sternal transection is the preferred approach in emergency conditions, as it can be performed quickly by general surgeons, and, if necessary, can be extended to the right hemithorax, being transformed into bilateral anterolateral thora-

cotomy in this way (23,50,51). This approach is recommended in patients with cardiac tamponade or in extremis, as it provides rapid access to the right and left ventricles, pulmonary arteries, and facilitates the examination of anatomical structures in the posterior mediastinum (esophagus, descending aorta, and pulmonary hilum). However, in cases when examination of the right atrium, the superior or inferior vena cava, and the proximal portion of the aorta is necessary, it is less effective. Posterolateral thoracotomy allows limited cardiac revision. At the same time, this approach may exacerbate hemodynamic instability, so its use is not recommended in patients with the cardiac wound (14).

Taking into consideration the benefits of Spangaro's incision, it was used in 63.4% of cases. However, the choice of approach was dependent on the surgeon's experience and the suspected lesions, evaluated according to the direction of the wound canal.

When the access to the heart is obtained, examination of the pericardium for the presence of defects is performed (8,52); after reviewing it, the pericardial cavity should be opened. The opening of the pericardial cavity can be a real challenge, on the one hand the pericardium is a durable fibrous tissue, on the other hand, if the procedure is performed inappropriately the iatrogenic laceration of the underlying epicardium may occur (14,51).

When the wound is identified, temporary hemostasis should be achieved. Several techniques are proposed for the temporary control of the hemorrhage, such as digital control, the use of the Foley catheter, or the application of skin staples (47,53,54). The application of the Foley catheter, however, is associated with specific risks such as the risk of breaking the balloon, including it in the suture, or enlarging the wound (14). Skin staples are especially useful for closing large defects, thus allowing to reduce the risk of further damage to the heart (54,55). Unfortunately, this method is not always technically available, in addition, staples do not effectively control hemorrhage in all cases and

prove rather difficult to remove. According to O'Connor et al. (2009), digital control is the simplest and most effective method of controlling cardiac bleeding, in addition, it facilitates permanent repair of the cardiac wound (14).

The final repair of atrial wounds is performed with monofilament sutures, such as 3-0 or 4-0 polypropylene sutures (Prolene) using either simple or horizontal mattress sutures. Because of its thin wall, the utmost and gentle technique should be applied during repair to prevent enlargement of the original wound (47,48,50,55). The ventricular repair technique requires the usage of 2-0 or 3-0 Prolene either as a simple running suture or as interrupted horizontal mattress sutures. If necessary, special Teflon pledges can be used to strengthen the suture line and ensure an even distribution of tension when the suture is tied (14,51,56). The key points to remember when performing cardiac suturing are the following: a large myocardial bite will give a more secure repair and placing the suture during the ventricular contraction allows to minimize the risk of myocardial tearing and avoid accidental ligation of the coronary arteries. Posterior cardiac lacerations should be resolved with caution and patience, as lifting the heart for a long period to visualize the defect and applying sutures can cause hypotension and potentially cardiac arrest (55,56,57).

Injuries localized close to the coronary arteries require a special approach. In order to prevent arterial occlusion as well as to preserve the important branches the final repair will be performed only with interrupted sutures, however, small, peripheral branches can be sacrificed and ligated (49,57). In most cases, when the bleeding is stopped and the lesion is resolved, mediastinal and thoracic drains are placed, then thoracorrhaphy is performed.

Limitations of the Study

The limitations of the study are also worth mentioning: (i) it is a series of cases from a single medical center and (ii) the design of

the study did not allow to perform a more detailed statistical analysis.

Conclusions

Although the number of patients with PCIs is decreasing, and innovations in diagnosis, resuscitation, cardiothoracic surgery, and intensive care are evident, trauma management continues to be a modern medical challenge with a high mortality rate.

Successful management of trauma patients depends on the ability of clinicians to properly recognize this type of injury and to apply the most appropriate surgical techniques for definitive resolution. Nowadays, large implementation of standardized clinical guidelines in trauma centers describing correct steps for better management can make the difference between life and death.

Conflict of Interest

The authors declare no conflict of interest.

Ethical Statement

The authors assure the manuscript is not considered for publication elsewhere, the paper reflects original research, the results are appropriately placed in the context, and all the used bibliographic sources are correctly cited.

References

1. Arıkan AA, Selçuk ES, Bayraktar FA. Predicting outcomes of penetrating Cardiovascular injuries at a rural center by different scoring systems. *Braz J Cardiovasc Surg.* 2020;35(2):198-205.
2. Isaza-Restrepo A, Bolívar-Sáenz DJ, Tarazona-Lara M, Tovar JR. Penetrating cardiac trauma: analysis of 240 cases from a hospital in Bogota, Colombia. *World J Emerg Surg.* 2017;12:26.
3. Wani L, Ahangar A, Wani S, Ifat Irshad I, Ul-Hassan N. Penetrating cardiac injury: a review. *Trauma Mon.* 2012;17(1):230-2.
4. Cherkas D. Traumatic hemorrhagic shock: advances in fluid management. *Emerg Med Pract.* 2011;13(11):1-19;quiz 19-20.
5. Alexi-Meskishvili V, Böttcher W. Suturing of penetrating wounds to the heart in the nineteenth century: the beginnings of heart surgery. *Ann Thorac Surg.* 2011;92:1926-31.
6. Biocina B, Sutlić Z, Husedzinović I, Rudez I, Ugljen R, Letica D. Penetrating cardiothoracic war wounds. *Eur J Cardiothorac Surg.* 1997;11:399-405.
7. Dixon R, McEwan P. Notes on a case of penetrating wound of the heart. *Br Med J.* 1916; 2891(1):755-6.
8. Asensio JA, Murray J, Demetriades D, Berne J, Cornwell E, Velmahos G, Gomez H, Berne TV. Penetrating cardiac injuries: a prospective study of variables predicting outcomes. *J Am Coll Surg.* 1998;186:24-34.

9. Morse BC, Mina MJ, Carr JS, Jhunjunwala R, Dente CJ, Zink JU, et al. Penetrating cardiac injuries: A 36-year perspective at an urban, Level I trauma center. *J Trauma Acute Care Surg.* 2016;81(4):623-31.
10. Campbell N, Thomson S, Muckart D, Meumann C, Van Middelkoop I, Botha J. Review of 1198 cases of penetrating cardiac trauma. *Br J Surg.* 1997; 84(12):1737-40.
11. Dokoupil M, Marecova K, Uvira M, Joukal M, Mrázková E, Chmelová J, et al. Fatal delayed hemopericardium and hemothorax following blunt chest trauma. *Forensic Sci Med Pathol.* 2019;15(2):272-5.
12. Leite L, Gonçalves L, Vieira DN. Cardiac injuries caused by trauma: review and case reports. *J Forensic Legal Med.* 2017;52:30-4.
13. Warrington SJ, Mahajan K. *Cardiac Trauma.* In: StatPearls (Internet). Treasure Island (FL): StatPearls Publishing; 2020.
14. O'Connor J, Ditiello M, Scalea T. Penetrating cardiac injury. *J R Army Med Corps.* 2009;155(3):185-90.
15. Attar S, Suter C, Hankins JR, Sequeira A, McLaughlin J. Penetrating cardiac injuries. *Ann Thorac Surg.* 1991;51:711-6.
16. Asensio J, Soto S, Forno W, Roldan G, Petrone P, Salim A, et al. Penetrating cardiac injuries: a complex challenge. *Injury.* 2001;32(7):533-43.
17. Imbert N, Tacher V, Mounier R, Martin M. Suspicion of penetrating cardiac injury: curing or caring? *Ann Card Anaesth* 2020;23:361-3.
18. Kwall T, Seecheran RV, Seecheran VK, Persad SA, Jagdeo CL, Seecheran NA. "Short to the heart": case report and concise review of cardiac gunshot injury. *JIMHICR.* 2020;8:1-4.
19. Jaramillo P, Montoya J, Mejia D, Warr S. Nonoperative Management of Multiple Penetrating Cardiac and Colon Wounds from a Shotgun: A Case Report and Literature Review. *Case Rep Surg.* 2018;2018:7839465.
20. Mittal V, McAleese P, Young S, Cohen M. Penetrating cardiac injuries. *Am Surg.* 1999;65(5):444-8.
21. Wu Y, Qamar SR, Murray N, Nicolaou S. Imaging of cardiac trauma. *Radiol Clin North Am.* 2019;57(4):795-808.
22. Pezzella A, Silva W, Lancey R. Cardiothoracic Trauma. *Curr Probl Surg.* 1998;35(8):651-789. [https://doi.org/10.1016/s0011-3840\(98\)80022-1](https://doi.org/10.1016/s0011-3840(98)80022-1)
23. Kang N, Hsee L, Rizoli S, Alison P. Penetrating cardiac injury: overcoming the limits set by Nature. *Injury.* 2009;40(9):919-27.
24. Panicker AT, Nugent K, Mink J, Glaser J, Bradley K, Siric F, Nomura JT. Bedside ultrasonography in the management of penetrating cardiac injury caused by a nail gun. *J Emerg Med.* 2019;56(2):197-200.
25. Yarlagadda C. Cardiac tamponade. *Emedicine.* In: <https://emedicine.medscape.com/article/152083-overview>. Accessed 21 May 2018.
26. Hsia R, Mahadevan S., Brundage S. Penetrating cardiac injury from a wooden knitting needle. *J Emerg Med.* 2012;43(1):116-9.
27. Moreno C, Moore E, Majure J, Hopeman A. Pericardial tamponade: a critical determinant for survival following penetrating cardiac wounds. *J Trauma.* 1986;26(9):821-5.
28. Asensio JA, Stewart BM, Murray J, Fox AH, Falabella A, Gomez H, et al. Penetrating cardiac injuries. *Surg Clin North Am.* 1996;76(4):685-724.
29. RuDusky BM. Classification of myocardial contusion and blunt cardiac trauma. *Angiology.* 2007;58(5):610-3.
30. Hegde R, Lafayette N, Sywak M, Ricketts G, Otero J, Kurtzman S, et al. Isolated right atrial appendage rupture following blunt chest trauma. *Trauma Case Rep.* 2018;13:26-9.
31. Wedro B. Shock. In: *Emedicinehealth* (Internet). Cited 2018 May 19. Available from: https://www.emedicinehealth.com/shock/article_em.htm#facts_about_shock.
32. Kim JS, Inaba K, de Leon LA, Rais C, Holcomb J, David JS, et al. Penetrating injury to the cardiac box. *J Trauma Acute Care Surg.* 2020; 89(3):482-7.
33. Claassen C, O'Connor J, Gens D, Sikorski R, Scalca J. Penetrating cardiac injury: Think outside the box. *J Trauma.* 2010;68(3):E71-E73.
34. Trinkle JK, Marcos J, Grover FL, Cuello LM. Management of the wounded heart. *Ann Thorac Surg.* 1974;17:230-6.
35. Szentpetery S, Lower RR. Changing concepts in the treatment of penetrating cardiac injuries. *J Trauma.* 1977;17:457-61.
36. Kaljusto M, Skaga N, Pillgram-Larsen J. Survival predictor for penetrating cardiac injury; a 10-year consecutive cohort from a Scandinavian trauma center. *Scand J Trauma Resusc Emerg Med.* 2015;3(23):41-8.
37. Mishra B, Gupta A, Sagar S, Singhal M, Kumar S. Traumatic cardiac injury: Experience from a level-1 trauma centre. *Chin J Traumatol.* 2016;19(6): 333-6.
38. Karrel R, Shaffer M, Franaszek J. Emergency diagnosis, resuscitation, and treatment of acute penetrating cardiac trauma. *Ann Emerg Med.* 1982;11: 504-17.
39. Moss AJ, Bruhn F. The echocardiogram. An ultrasound technic for the detection of pericardial effusion. *N Engl J Med.* 1966;274(7):380-4.
40. Meyer DM, Jessen ME, Grayburn PA. Use of echocardiography to detect occult cardiac injury after penetrating thoracic trauma: a prospective study. *J Trauma.* 1995;39(5):902-7. discussion 907-9.
41. Jimenez E, Martim M, Krukenkamp I, Barrett J. Subxiphoid pericardiotomy versus echocardiography: a prospective evaluation of the diagnosis of occult penetrating cardiac injury. *Surgery.* 1990;108(4):676-80.
42. Duncan AO, Scalea TM, Sclafani SJ, Phillips TF, Bryan D, Atweh NA, et al. Evaluation of occult cardiac injuries using subxiphoid pericardial window. *J Trauma.* 1989;29(7):955-9; discussion 959-60.
43. Andrade-Alegre R, Mon L. Subxiphoid pericardial window in the diagnosis of penetrating cardiac trauma. *Ann Thorac Surg.* 1994;58(4):1139-41.
44. Symbas PN, Vlais-Hale SE, Picone AL, Hatcher CR. Missiles in the heart. *Ann Thorac Surg.* 1989;48:192-4.
45. Hirshberg A., Thomson S., Bade P., Huizinga W. Pitfalls in the management of penetrating chest trauma. *Am J Surg.* 1989;157(4):372-375.
46. Wood A, Graham T. The management of cardiac trauma by general surgeons in non-cardiothoracic units. *J R Coll Surg Edinb.* 1994;39(1):63.
47. Navid F, Gleason TG. Great vessel and cardiac trauma: diagnostic and management strategies. *Semin Thorac Cardiovasc Surg.* 2008;20:31 8.
48. Mitchell M, Muakkassa F, Poole G, Rhodes R, Griswold J. Surgical approach of choice for penetrating cardiac wounds. *J Trauma.* 1993;34: 17-20.
49. Asensio J, Garcia-Nunez L, Petrone P. Trauma to the heart. In: *Trauma 6th ed.* Eds: Feliciano DV, Mattox KL, Moore EE. Ed. New York: McGraw Hill; 2008. pp. 569-588.
50. Asensio J, Petrone P, Karsidag T, Ramos-Kelly J, Demiray S, Roldan G, et al. Penetrating cardiac injuries. Complex injuries and difficult challenges. *Ulus Travma Acil Cerrahi Derg.* 2003;9(1):1-16.
51. Degiannis E, Douglas M, Bowley D, Westaby S. Penetrating cardiac injury. *Ann R Coll Surg Engl.* 2005;87:61-3.
52. Plummer D, Brunette D, Asinger R, Ruiz E. Emergency department echocardiography improves outcome in penetrating cardiac injury. *Ann Emerg Med.* 1992;21(6):109-12.
53. Arbulu A, Thomas N. Control of bleeding from a gunshot wound of the inferior vena cava at its junction with the right atrium by means of a Foley catheter. *J Thorac Cardiovasc Surg.* 1972;63:427-429.
54. Macho J, Markison R, Schechter W. Cardiac stapling in the management of penetrating injuries of the heart: rapid control of hemorrhage and decreased risk of personal contamination. *J Trauma.* 1993;34(5):711-5.
55. Wall MJ, Mattox KL, Chen CD, Baldwin JC. Acute management of complex cardiac injuries. *J Trauma Inj Infect Crit Care.* 1997;42(5):905-12.
56. Tran HV, Charles M, Garrett RC, Kempe PW, Howard CA, Khorgami Z. Ten-year trends in traumatic cardiac injury and outcomes: a trauma registry analysis. *Ann Thorac Surg.* 2020;110(3):844-8.
57. Ingraham A, Sperry J. Operative management of cardiac injuries: diagnosis, technique, and postoperative complications. *Curr Trauma Rep.* 2015;1(4): 225-31.