

Cytoreductive Surgery and Hyperthermic Intraperitoneal Chemotherapy for the Treatment of Peritoneal Carcinomatosis: Our Initial Experience

Adrian Bartoș¹, Dana Bartoș^{1,2}, Stoian Raluca^{1,2}, Călin Mitre³, Adina Hadade³, Ioana Iancu¹, Cristian Cioltean¹, Cornel Iancu^{1,4}, Claudia Militaru⁵, Angela Părău⁶, Caius Breazu³

¹Regional Institute of Gastroenterology and Hepatology, Department of Surgery, Cluj – Napoca, Romania

²“Iuliu Hațieganu” University of Medicine and Pharmacy, Anatomy and Embryology Department, Cluj – Napoca, Romania

³Regional Institute of Gastroenterology and Hepatology, Department of Anesthesiology and Intensive Care, Cluj – Napoca, Romania

⁴“Iuliu Hațieganu” University of Medicine and Pharmacy, Department of Surgery, Cluj – Napoca, Romania

⁵“Iuliu Hațieganu” University of Medicine and Pharmacy, Pharmacology, Toxicology and Clinical Pharmacology Department;

Medisprof Clinic, Cluj – Napoca, Romania

⁶Regional Institute of Gastroenterology and Hepatology, Department of Oncology, Cluj – Napoca, Romania

Corresponding author:

Dana Bartoș, MD, PhD.

Anatomy and Embryology Department

University of Medicine and Pharmacy

“Iuliu Hațieganu”, 3-5 Clinicilor street

Cluj – Napoca, Romania

E-mail: bartosdanamonica@gmail.com

Rezumat

Chirurgia citoreductivă asociată cu chimioterapie intraperitoneală hipertermică în tratamentul carcinomatozei peritoneale: experiența noastră inițială

Introducere: Carcinomatoza peritoneală reprezintă un stadiu avansat al cancerelor abdominale în general și a cancerului colorectal în particular. Singurele metode de tratament disponibile la momentul actual pentru această patologie sunt chimioterapia sistemică (caracter paliativ) și chirurgia citoreductivă (CR) asociată cu chimioterapie intraperitoneală hipertermică (HIPEC). După revizuirea literaturii și a ghidurilor de specialitate, putem afirma că procedura CR+HIPEC trebuie luată în considerare în managementul pacienților cu carcinomatoză peritoneală de origine colorectală, ovariană și mucocel apendicular.

Material și metodă: În lucrarea de față am analizat prospectiv rezultatele imediate postoperatorii obținute de către echipa noastră la primii 50 de pacienți operați pentru carcinomatoză peritoneală de diferite origini. Am descris protocolul de selecție, caracteristicile pacienților care au fost incluși în programul nostru de CR+HIPEC și am analizat incidența complicațiilor și a deceselor.

Rezultate: Din ianuarie 2015 până în decembrie 2018 am evaluat pentru tratament 98 de pacienți cu carcinomatoză peritoneală.

Received: 15.02.2019

Accepted: 19.03.2019

Dintre aceștia, doar 51 au beneficiat de tratament radical (CR+HIPEC); 33 nu au fost potriviți pentru intervenția chirurgicală datorită criteriilor de excludere și la 15 s-a practicat doar laparotomie exploratorie. În ceea ce privește originea histopatologică, 30 de paciente au avut cancer ovarian; 19 pacienți au avut carcinomatoză cu origine colorectală sau pseudomixom peritoneal de origine apendiculară. Nu a existat mortalitate la 30 de zile. Incidența complicațiilor postoperatorii semnificative a fost de 15%.

Concluzii: Chirurgia citoreductivă urmată de chimioterapie intraperitoneală hipertermică este o procedură complexă însoțită de o incidență acceptabilă a complicațiilor și a deceselor postoperatorii, rezultatele putând fi optimizate prin management perioperator standardizat și selecția atentă a pacienților. Rezultatele inițiale obținute de echipa noastră subliniază fezabilitatea acestei proceduri, cu rezultate imediate bune, obținute ca rezultat a respectării unui protocol standardizat de selecție a pacienților și a managementului perioperator.

Cuvinte cheie: carcinomatoză peritoneală, cancer colorectal, cancer ovarian, pseudomixom peritoneal, chimioterapie intraperitoneală hipertermică, rezecții multiorgan.

Abstract

Introduction: Peritoneal carcinomatosis represents an advanced stage of tumor dissemination of abdominal cancers in general and colorectal cancer in particular. The only therapeutic methods currently available for the treatment of this pathology are systemic chemotherapy (palliative character) and cytoreductive surgery (CR) with intraperitoneal chemotherapy. After evaluation of evidence-based medical literature and current guide lines we can state that CR + HIPEC procedure is considered to be the treatment of choice in case of patients with peritoneal carcinomatosis of colorectal, ovarian and mucinous appendicular origin.

Material and method: In the present study we prospectively analyzed the immediate postoperative results obtained in the first 50 patients that were treated by our team for peritoneal carcinomatosis of different origin. We described the protocol of selection, the patients characteristics that were included in our CR+HIPEC program and analyzed the complications and death rate.

Results: From January 2015 till Dec 2018 we evaluated 98 patients with peritoneal carcinomatosis. From them, 51 received radical CR+HIPEC treatment, 33 were not suitable for surgery because of the exclusion criteria's and 15 had only exploratory laparotomies. In regard with the histopathological diagnosis, 30 patients had ovarian cancer and 19 had colorectal cancer or peritoneal pseudomyxoma of appendicular origin. There was no 30 days postoperative mortality. The incidence of significant postoperative complications was 15%.

Conclusions: Cytoreductive surgery followed by hyperthermic intraperitoneal chemotherapy is a complex technique accompanied by an acceptable rate of complications and postoperative deaths, the results being optimized by a standardized perioperative management and patient selection. The initial results obtained by our team emphasize the feasibility of this procedure, with immediate good results, as a result of a standardization protocol of patient selection and perioperative care.

Key words: peritoneal carcinomatosis, colorectal cancer, ovarian cancer, pseudomyxoma peritonei, hyperthermic intraperitoneal chemotherapy, multiorgan resections

Introduction

Of the patients diagnosed with colorectal cancer, 7% have peritoneal carcinomatosis at

the time of diagnosis, survival at 5 years being null in these cases. (1) Furthermore, 56% of patients receiving radical colorectal resection will develop peritoneal carcinomatosis; in 25%

of the cases, the recurrence will be limited to the peritoneum (1,2). For these patients, if the treatment involves only palliative systemic chemotherapy, the median survival rate will not exceed 15 months (2).

Cytoreductive surgery (CR) and hyperthermic intraperitoneal chemotherapy (HIPEC) have proven their feasibility since 1987-1993, period in which Sugarbaker has repeatedly reported favorable outcomes for patients with peritoneal pseudomixoma (3,4). Since then, the technique has been applied with promising results for patients diagnosed with peritoneal carcinomatosis of ovarian, gastric and appendicular origin as well as for malignant peritoneal mesothelioma (2). In the case of colorectal cancer, literature reports indicate that CR surgery followed by HIPEC may lead to an increase of median survival rate of up to 62 months, with a 5-year survival ranging from 17 to 51% (2) (Table 1). Starting from year 2017, international guidelines recommends applying this treatment in experienced centers, on selected cases but only when a complete cytoreduction (R0) can be obtained (5-7).

Taking into account the favorable results reported in the literature and the high incidence of advanced colorectal pathology diagnosed and treated in the "Professor Dr. Octavian Fodor" Institute of Gastroenterology and Hepatology, starting 2015 we began a selection and treat-

ment program for patients with peritoneal carcinomatosis; all these in order to implement CR surgery and HIPEC as standard treatment in our institution (8).

Definitions. Principles

The Peritoneal Carcinomatosis Index (PCI) represents a quantification score for the extent of peritoneal neoplastic lesions, described for the first time by Sugarbaker (9). It involves the evaluation of 13 abdominal-pelvic regions (central, right hypochondrium, epigastrium, left hypochondrium, left flank, right flank, right iliac fossa, pelvis, left iliac fossa, proximal jejunum, distal jejunum, proximal ileum, distal ileum) and the scoring, depending on the size of the peritoneal neoplastic deposits. Thus, the PCI can be between 0 and 39, this score being designed to predict the likelihood of a complete cytoreduction (10).

The success of cytoreduction is evaluated and graded at the end of the surgical procedure by establishing the "completeness of cytoreduction" (CC) score (11,12). Thus, we are talking about a CC-0 score in cases where there are no macroscopically visible tumoral deposits after cytoreduction. A CC-1 score is given when nodules smaller than 2.5 mm remain in the peritoneal cavity but, they are still considered

Table 1. Surviving rate of patients with CR + HIPEC for colorectal cancer. After Kitayama et al. (47) and Kulu et al. (2)

Author, year of study publication, bibliographic reference	Number of patients	Median survival rate (months)	Survival (years %)		
			1	2	5
Yonemura, 2013 (58)	142	24.4	NR	NR	23.4
Hompes, 2012 (59)	48	NR	97.9	88.7	NR
Cashin, 2012 (21)	69	34	NR	NR	40
Quenet, 2011 (60)	103	47	NR	NR	42.4
Elias, 2010 (13)	359	NR	NR	NR	33
Elias, 2010 (28)	523	30.1	81	41	27
Franko, 2010 (61)	67	34.7	NR	NR	NR
Elias, 2009 (48)	48	62.7	NR	81	51
Verwaal, 2005 (62)	117	42.9	94	56	43
Quenet, 2018 (49)	133	41.7	NR	NR	NR

HIPEC sensitive. A CC-3 score is given in cases when the remnant tumors are bigger than 2.5 cm or when there is an unresectable tumor mass in the abdomen and pelvis. In the case of colorectal cancer with peritoneal carcinomatosis, a complete CR (CC-0) achieved with the cost of multiorgan resections and extended peritonectomies is the only option able to provide optimal results, the CC score being the main prognostic factor (13-17).

Intraperitoneal chemotherapy consists of an extended lavage of the peritoneal cavity with cytotoxic drugs. The main advantage of intraperitoneal administration of chemotherapeutic agents is the low systemic toxicity that allows prolonged exposure in higher doses of the intra-abdominal tumors with antineoplastic agents.

Regarding the temperature of intraperitoneal administration of cytotoxic agents, it has been shown that above 41°C they have selective cytotoxicity on tumor cells, activating protein degradation, inhibiting the oxidative metabolism, increasing the pH, activating the lysosomes and the cellular apoptosis. Moreover, temperatures above 41°C lead to augmentation of the cytotoxic effect of cytotoxic agents as well as increased absorption and penetration of the tumor tissue (2, 18-20).

The role of hyperthermia was highlighted in studies indicating the superiority of HIPEC versus "early postoperative intraperitoneal chemotherapy" (EPIC) or "sequential postoperative intraperitoneal chemotherapy" (SPIC), both normothermic lavage methods. The benefits of HIPEC have been translated through prolonged survival with a lower rate of recurrence and postoperative complications (21).

Achieving the optimal temperature (41-43°C) and maintaining it are conditioned by the presence of an increased flow of the intraperitoneal lavage, which is possible thanks to dedicated devices (22).

The role of systemic chemotherapy remains particularly important, essentially contributing in completing the correct treatment through its neoadjuvant or adjuvant character, case depending. Furthermore, concomitant intraoperative administration of systemic cytotoxic

agents leads to an enhancement of the cytotoxic intraperitoneal effect by reaching a bidirectional diffusion gradient. Typically, 30-60 minutes before HIPEC, intravenous 5-fluorouracil and folinic acid are administered (19,23).

Material and Method

Starting January 2015, we began using this treatment on patients histopathologically diagnosed with peritoneal carcinomatosis from colorectal adenocarcinoma, appendicular mucoceles, ovarian adenocarcinoma and gastric adenocarcinoma.

To establish the opportunity for surgery, we followed a standard protocol with routine multidisciplinary meetings: surgeon, anesthesiologist, oncologist.

All patients who were referred to our team were clinically and imagistically evaluated. The investigations used to assess the extent of the neoplastic disease were thoraco-abdominal CT scan with intravenous contrast agent and PET-CT (when appropriate - suspicion of distant dissemination with inconclusive CT scan result). The presence of hepatic or extraperitoneal metastases was a contraindication for CR + HIPEC. When imaging indicated the presence of carcinomatosis limited to the abdominal cavity but with a degree of uncertain organ involvement, exploratory laparoscopy/laparotomy was indicated. Except for patients with peritoneal pseudomyxoma, a PCI greater than 20 contraindicated the surgery.

In order to optimize the perioperative results, we build up a team of 3 specialists dedicated to CR and HIPEC: 2 surgeons and one ATI physician. The surgical procedure has also been standardized.

The resection time meant the excision of all tumor deposits "in block" with the invaded organs (multiorgan resections - MOR)(12,24), the goal being to obtain a CC-0 score for all patients (*Fig. 1*). For this purpose, when needed, vascular or urogenital resections with consecutive reconstructions were performed. (*Figs. 2-3*).

In order to minimize the septic risks, the sectioning of the digestive tract was done

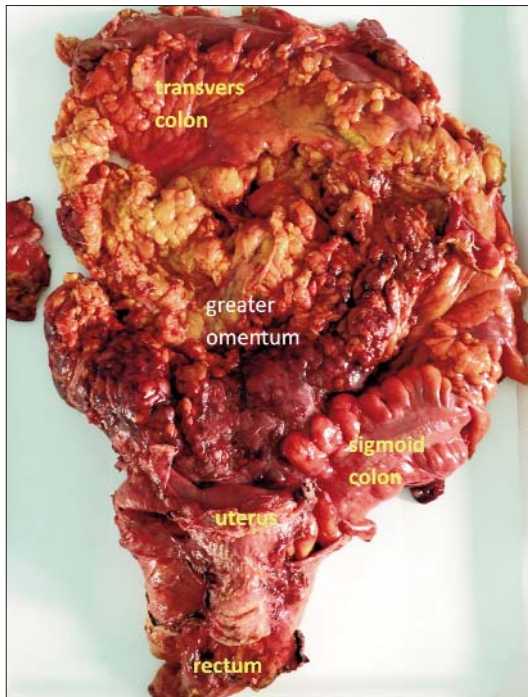


Figure 1. “En block” multiorgan resection during cytoreductive surgery (from the personal archive of the authors)

using mechanical suture devices (staplers).

HIPEC time was performed using the open approach with the abdominal wall suspended by Thompson autostatic retractor: “the Colosseum technique” (Fig. 4A).

Considering the importance of maintaining hyperthermia and high intraperitoneal flow during HIPEC, the device used to perform the procedure was a dedicated one: ThermoChem HT-2000® from Therma Solutions (Fig. 4B).

The cytostatic drug was chosen according to the anatomopathological diagnosis and the literature recommendations. For colorectal carcinomatosis, the standard protocol applied was HIPEC with Oxaliplatin, 460 mg/m² in 2 L/m².

Reconstruction time (digestive anastomoses) was performed after HIPEC in order to minimize the risk of recurrence at the level of digestive and/or anastomotic stumps. In patients with extensive digestive resections, those with gastric resections or those with poor nutritional status, jejunostomy was routinely performed. Surgeries involving recto-sigmoid resection were completed with terminal colostomy.

The discharge of the patients was done

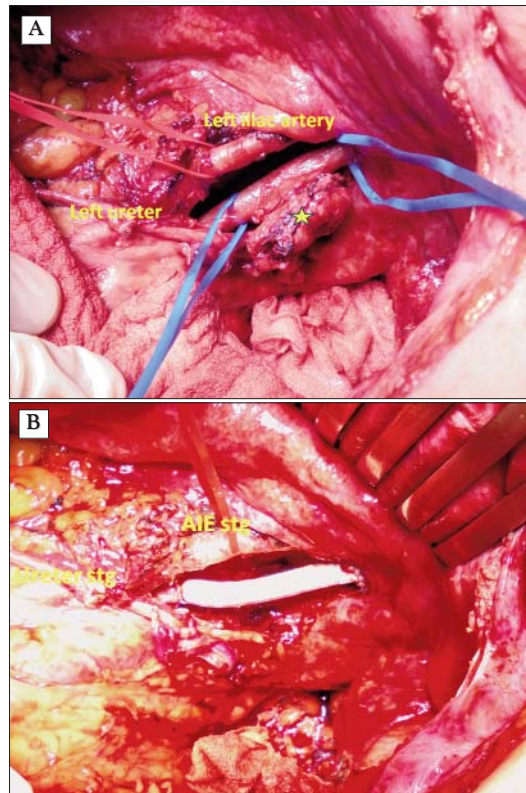


Figure 2. Segmental left iliac vein resection for tumoral invasion (*) (A) with PTFE graft reconstruction (B). (form the personal archive of the authors)

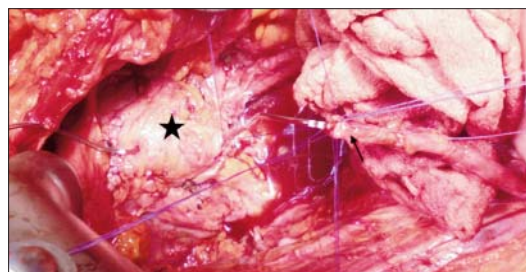


Figure 3. Reimplantation of the left ureter (arrow) at the bladder dome (star), after distal ureteral resection for tumoral invasion. (form the personal archive of the authors)

according to standard protocols, in the absence of complications and when the patient could feed and take care of itself alone. Postoperative follow-up required 1-month follow-up and then from 3 to 3-month periodical examinations, including clinical examination, blood count, blood biochemistry, tumor markers (CEA, CA125, as appropriate), quality of life questionnaires (EuroQol 5-D) (25). Depending on the

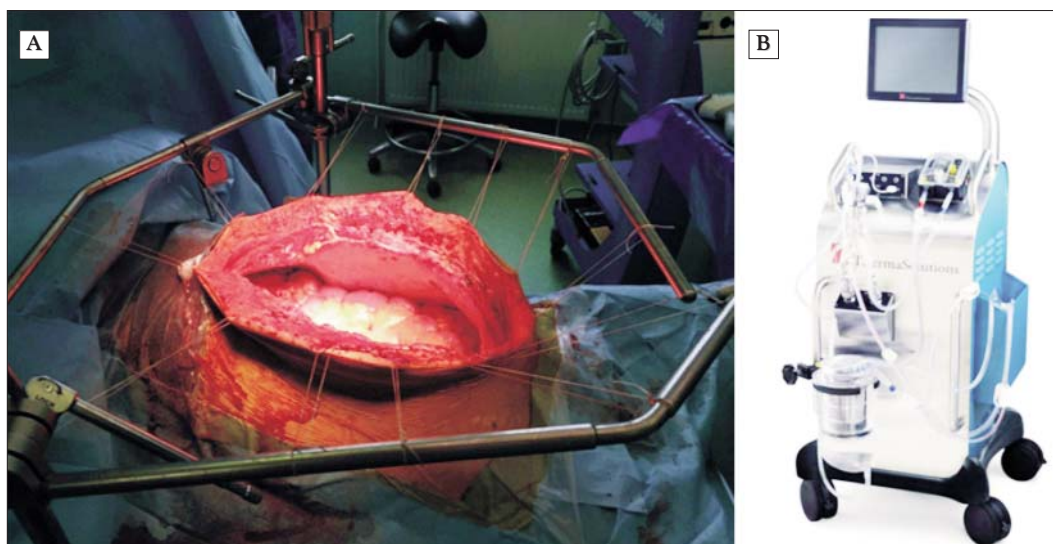


Figure 4. Abdominal wall preparation for HIPEC, "Colosseum" technique (A); HIPEC Device, HT-2000® (images from the manufacturer's brochure, Thermo Solutions) (B)

situation (elevated tumor markers), control postoperative CT scan was performed.

Considering that the surgical procedure (CR) and the intraperitoneal chemotherapy (HIPEC) are similar for all of the above-mentioned diagnoses (the procedure generally being applied on patients with peritoneal carcinomatosis), we included in our study all the patients with this diagnosis, regardless of the origin of their primary tumor.

Thus, we included in our analysis the first 50 consecutive patients diagnosed with peritoneal carcinomatosis, following immediate postoperative outcomes. Postoperative complications were classified using the Clavien-Dindo classification and were quantified up to 60 days postoperatively (26). The quality of life form was completed at routine post-operative checks, according to the protocol.

Results

Between January 2015 and December 2018, we evaluated 98 patients for CR and HIPEC. 33 did not have surgery due to associated comorbidities, Karnovsky performance status < 60 or major anesthetic risk. In 15 patients, surgery was limited to exploratory laparotomy, intraoperative exploration indicating an exten-

sion of neoplastic disease that was not suitable for cytoreduction.

CR and HIPEC technique have been successfully applied to 50 patients: 14 with peritoneal carcinomatosis of colorectal etiology, 5 with peritoneal pseudomyxoma of appendicular origin, 30 of ovarian origin and 1 of gastric origin.

The median age was 58.5 years (24-69 years). Median body mass index (BMI) was 30.39 (23.19-37.47).

40 patients had a history of abdominal surgery, 24 of whom had relapse after previous radical surgeries. All patients had comorbidities (Table 2).

The carcinomatosis index ranged between 1 and 22. The median operating time was 450 minutes (min 240 - max 900). Blood loss was between 0 and 1500 ml with a median of 150 ml. Complete cytoreduction (CC0) was obtained in all patients.

Taking into account the Clavien-Dindo classification, 3 of the patients experienced grade IIIb complications (ischemic digestive perforations and intestinal occlusion) requiring surgical reintervention. One of these died 51 days postoperatively (developing grade V complication). One patient developed a grade IV complication (adverse effects of intraperitoneal and systemic

Table 2. Associated diseases. Personal pathological history

Associated pathologies	N	Associated pathologies	N
Cardiovascular diseases (EHBP, Cardiac failure, Valvular insufficiency, Sinus node disease, Atrio-ventricular block)	20	Endocrine pathology (goiter)	5
Peripheral vein pathology (hydrostatic varices)	15	Chronic liver disease (chronic hepatitis B or C, liver cirrhosis)	3
Diabetes	3	Pancreatic pathology (pancreatic pseudocyst)	1
Chronic pulmonary pathology (CBPO)	2	Moderate cystoectocele	1
Chronic renal pathology (chronic renal insufficiency)	2	Psychiatric disorder (depressive disorder, dissociative disorder)	2
History of neoplastic disease (other than the one currently diagnosed)	2 *, **	Infectious disease (syphilis)	1
Paraneoplastic anemic syndrome	12	Drug allergies	1
Thrombocytopenia	2	Adrenal gland adenoma	1
Neurological pathology (epilepsy, disc hernia)	2	Right renal angiomyolipoma	1

* Operated clear cell kidney carcinoma (nephrectomy); ** Operated breast cancer (mastectomy)

chemotherapy), with favorable outcome under intensive care therapy. Overall morbidity (including minor complications, grade I-II) was 41%, with an incidence of grade III-V complications of 15% (Table 3).

No 30 days postoperative mortality was recorded. One patient died 51 days after surgery, after developing late postoperative necrosis of the aponeurosis and 2 intestinal ischemic perforations, complications that led to septic and multiple organ failure. Thus, the 60-day mortality was 1.9% (n = 1).

The median stay in the intensive care unit was of 5 days (min 2 - max 30). Median

hospitalization was 18.5 days (minimum 11 - maximum 42).

The median follow-up was of 689 days. Currently, 40 patients are alive, 4 of them having neoplastic recurrence: lymphatic (n=1), loco-regional (n=2), adrenal gland (n=1). 10 patients died, 4 of them from peritoneal or lymphatic recurrence, 2 from pulmonary metastases and 4 from hepatic metastases.

In terms of quality of life, according to the EuroQoL questionnaire, applied at 3, 6 and 9 months, most patients had a score of 7 or 8 (n = 20 patients, respectively n = 17). 6 patients reported a score of 11.

Table 3. Postoperative complications (Clavien-Dindo)

Grade	N (no of patients)	N/complications	N/complications	N/complications
I	9	7/Wound infections	1/Transitory leucopenia	1/Delayed gastric emptying
II	4	2/Transitory acute renal failure	1/Central vestibular syndrome	1/ Psychoactive Delirium
IIIa	2	1/Pleuresia, ascites	1/Pancreatic abcess	-
IIIb	3	2/Ischemic digestive perforations	1/Bowell occlusions	-
IV	1	1/Severe leucopenia	1/Acute hepatic failure	1/Peripheral neuropathy
V	1	1/MOF* + Death	-	-

* MOF = Multiple organ failure

Discussions. Perspectives

Favorable results after CR and HIPEC were previously highlighted by 1 randomized study (27), 2 multicentric studies (28,29), several Phase II-III studies and numerous other literature reports (30,31), CR and HIPEC being considered as "standard of care" for the treatment of peritoneal malignancies in excellence centers from USA, Canada, Belgium, Germany, the Netherlands.

The selection of patients who can benefit from this treatment is essential. The mandatory diagnosis algorithm for CR and HIPEC candidates will include: anamnesis, clinical examination, CEA tumoral marker (for non-mucous pathology), total colonoscopy, thoraco-abdominal-pelvic imaging (CT, PET-CT).

One of the first things that have to be taken in consideration at a candidate for CR + HIPEC is that he should not have major comorbidities. The patient's biological status must be acceptable, with a proper performance status. Thus, according to the Karnofski score, ideal patients should have a score between 60 and 100. The Canadian guidelines use a different rating system, the "Eastern Cooperative Oncology Group Performance Status", only patients achieving a 0 score (2 possible, 0 being the best) are suitable for HIPEC (32).

Also, patient age should be an important selection criterion. The Canadian guidelines indicate 65 years as 'cut off'. Over this age, surgery is recommended only for carefully selected patients without co-morbidity, low IC and less aggressive histopathology (32-34).

A body mass index above 35 is a relative contraindication for CR and HIPEC (35,36).

In our initial experience, we have complied with the international recommendations on the patient's selection, not including in the CR/HIPEC program patients with major comorbidities (*Table 2*), performance status below 60 years, age below 70 (patients that had over 65 and were included had a very good biological and performance status) and ICM over 35. We had a female patient with a ICM of 37, limited carcinomatosis, age <60 and no

comorbidities, reasons why we selected her for CR / HIPEC.

Knowing the extent of neoplastic disease is essential in the selection of cases. The presence of extraperitoneal metastases, diagnosed by CT, PET-CT or MRI, is a contraindication of the procedure (32). Intraoperative assessment (laparoscopy or laparotomy) of the extension of peritoneal carcinomatosis is the only procedure that can ultimately evaluate the opportunity and the possibility of performing a surgical procedure with a radical, oncological intend. Thus, PCI can estimate the extent to which complete cytoreduction can be performed, with a direct impact on survival. It is considered that a PCI > 20 should be a contraindication for surgery, except for peritoneal pseudomixoma of appendicular origin (32). The final assessment of PCI can be done only by laparotomy (37).

Unfortunately, a large number of patients that were evaluated for CR + HIPEC did not meet the selection criteria mentioned above. We also had a not neglected number of patients, on which we performed only exploratory laparotomies (n = 15), this highlighting the limits of preoperative imaging explorations in detecting small peritoneal implants (<0.5 cm = miliary carcinomatosis). An alarm signal is also represented by the large number of patients in whom peritoneal carcinomatosis was a recurrence of previous oncological radical surgeries (n = 24). This problem emphasizes the importance of a national network of specialized centers that can closely monitor patients at risk and could be able to provide optimal treatments, including CR+HIPEC. In the same idea, HIPEC prophylaxis is also under discussion in patients considered at risk (T3-T4 tumors), especially when peritoneal lavage with histopathological extemporaneous examination is positive. This topic is highly discussed in the literature; the ongoing studies will determine whether this attitude is justified or not (38,39).

Tumor invasion at the level of vital, unresectable structures (aorta, vena cava) contraindicate the surgery. The presence of hepatic metastases is a relative contraindication, segmental resections being accepted. The need for major liver resections, duodenopancrea-

tectomy or pelvic exenteration will contraindicate the intervention, with rare exceptions (limited disease, very good biological status, well differentiated histopathological forms) (32, 40-42).

The histopathological origin of the tumor must be known before surgery; the biopsy can be taken by endoscopy, percutaneous ultrasound guided or laparoscopic approach. Moderate and /or well differentiated adenocarcinoma have been proved to have the best results. As a guide line, the indication of CR and HIPEC in patients with poorly differentiated or undifferentiated tumors should be established with caution, in these cases the benefits being poor. By modest results, presence of signet ring cell, associated with other relative contraindications, limits the applicability of this technique (43). Mucinous tumors of appendicular origin (peritoneal pseudomyxoma) have by default an indication for CR and HIPEC (32).

Analyzing our data, we also noticed a much more modest outcome in relation to the presence of signet cell adenocarcinoma, the only patient that we had with this histopathology developing lymph node metastases at 6 months and died at 14 months after surgery. Because of the small number of patients with this histopathological origin (in our study), we were not able to draw statistical conclusions.

The absolute contraindications of this intervention are: extra-abdominal extension (certified through biopsy), extraperitoneal neoplasia (more than 3 liver metastases or N3 by lymphatic ganglia assessment) and/or a cancer with unknown origin (32,44).

In general, the surgery will not be performed in case of bowel occlusion, although there are reports that indicate CR and HIPEC under emergency conditions as feasible (32,45).

The surgical team, the anesthetic and intensive care physician and the oncologist play an important role in CR + HIPEC procedure, a multidisciplinary approach being mandatory for optimal results.

The surgeon must have a good expertise in oncologic surgery, most of the time tumor-resections leading to MOR, required in order

to achieve R0 resection margins. Current guidelines do not state the number of such interventions a surgeon should undertake annually, but underline that a center or a team should have about 20 interventions/year in order to be considered a referral center. For a newly established center, it is recommended to treat at least 1 patient/month with the goal of reaching 20 patients/year (32,46).

In concern of colorectal cancer, literature reports indicate that cytoreductive surgery (CR) followed by intraperitoneal chemotherapy (HIPEC) is associated with a reported incidence of complications ranging between 20% -50% and a mortality between 1% -10% (2,47-49). Among the postoperative complications, the infectious type ranges first (50). In our study, most patients who developed postoperative complications experienced parietal wound infection (n = 7), with no significant impact on subsequent outcome (Clavien-Dindo grade I complications). Intraperitoneal chemotherapy per se can cause systemic toxicity with consecutive side effects (51,52). 3 patients developed such adverse drug related effects with complete remission under specific intensive care therapy. A possible complication after HIPEC is ischemic intestinal perforation (52). Two of the patients operated by our team developed such a complication.

The literature shows a learning curve in the CR and HIPEC of at least 200 cases (53). There are also studies showing that the learning curve for CR+HIPEC can be shortened by training in specialized centers that have already exceeded the same curve (42). In this idea, in order to optimize the immediate and remote results, we started the CR+HIPEC program in our service with a dedicated team, trained in specialized high-volume centers. As a result, the analysis of our initial experience (the first 50 cases) indicates a morbidity and mortality that falls within the limits reported by centers with high experience in the field. Of course, the final validation of the results will also come with the analysis of the survival curves and the factors that influence the long outcomes, a project that is progress in our service.

Although the literature indicates the feasibility of reintervention with repeated CR and HIPEC procedure (for intraperitoneal tumor recurrence) (54), in the two cases with intra-abdominal tumor recurrence, we failed to repeat the procedure due to the intense adhesion syndrome and extent of neoplastic disease.

Although highly complex procedures, indicated for a very advanced stage of neoplastic disease, postoperative controls at 3-9 months have shown a surprisingly good quality of life, most patients succeeding in reintegrating themselves rapidly into the family-social environment.

Future research in the field are dedicated to the improvement of the cytostatic drugs with the help of nanotechnology (55), as well as research in the field of hyperthermia, the standardization of temperature curves and chemotherapeutic concentrations being essential (56,57).

Conclusions

The good initial results obtained after the implementation of the CR and HIPEC technique in our institution emphasize the feasibility of this procedure as a standard treatment for patients diagnosed with peritoneal carcinomatosis of colorectal, appendicular and ovarian origin. Furthermore, we consider that these results underline the fact that applying a standardized protocol in case selection, operative technique and perioperative care and working with dedicated multidisciplinary teams (surgeons, ATI physician, oncologist, nurse), specialized in abdominopelvic oncological surgery will lead to optimal immediate results, even before the completeness of the literature stated learning curve of CR and HIPEC.

Acknowledgment

Part of the data presented in this article is part of the first author's PhD research (Adrian Bartoș).

Stoian Raluca has the same contribution as the first author, therefore being considered main author as well.

Authors' Contributions

Adrian Bartoș, Dana Bartoș, Raluca Stoian, Caius Breazu equally contributed to this article (see below the contributions) so for that, they are all main authors:

- conception and design of the article and the acquisition of data;
- drafting the article;
- final approval of the version to be published.

Ioana Iancu, Cristian Cioltean, Cornel Iancu had substantial contributions to conception, design of the review and acquisition of data.

Mitre Călin, Adina Hadade, Părău Angela and Claudia Militaru had substantial contributions in regard with drafting the article and revising it critically.

Conflict of Interest

The authors declare no conflicts of interests.

References

1. Koppe MJ, Boerman OC, Oyen WJ, Bleichrodt RP. Peritoneal carcinomatosis of colorectal origin: incidence and current treatment strategies. *Annals of surgery*. 2006;243(2):212-22.
2. Kulu Y, Muller-Stich B, Buchler MW, Ulrich A. Surgical treatment of peritoneal carcinomatosis: current treatment modalities. *Langenbeck's archives of surgery / Deutsche Gesellschaft fur Chirurgie*. 2014; 399(1):41-53.
3. Sugarbaker PH, Kern K, Lack E. Malignant pseudomyxoma peritonei of colonic origin. Natural history and presentation of a curative approach to treatment. *Diseases of the colon and rectum*. 1987;30(10):772-9.
4. Sugarbaker PH, Zhu BW, Sese GB, Shmookler B. Peritoneal carcinomatosis from appendiceal cancer: results in 69 patients treated by cytoreductive surgery and intraperitoneal chemotherapy. *Diseases of the colon and rectum*. 1993;36(4):323-9.
5. National Comprehensive Cancer Network Guidelines version 2.2018. Ovarian Cancer. 2018 [Available from: www.nccn.org].
6. National Comprehensive Cancer Network Guidelines version 4.2018. Colon cancer. 2018 [Available from: www.nccn.org].
7. Van Cutsem E, Cervantes A, Adam R, Sobrero A, Van Krieken JH, Aderka D, et al. ESMO consensus guidelines for the management of patients with metastatic colorectal cancer. *Annals of Oncology*. 2016;27(8):1386-422.
8. Bartos A, Bartos DM, Breazu C, Hosu M, Stoian R, Iancu C. Cytoreductive surgery (CR) followed by hyperthermic intraperitoneal chemotherapy (HIPEC): a chance of survival for patients

- with advanced colorectal cancer. *Journal of gastrointestinal and liver diseases* : JGLD. 2015;24(3):392-3.
9. Sugarbaker PH. Intraperitoneal chemotherapy and cytoreductive surgery for the prevention and treatment of peritoneal carcinomatosis and sarcomatosis. *Seminars in surgical oncology*. 1998;14(3):254-61.
 10. Merlini M, Dusmet M. Surgical Indications. In: Merlini M, editor. *Multiorgan Resections for Cancer Advanced Surgical Techniques*. Stuttgart. New York: Thieme; 2006. p. 3-7.
 11. Current indications for cytoreductive surgery and intraperitoneal chemotherapy
[Available from: <http://www.surgicaloncology.com/gpmindic.htm>.
 12. Bartos A, Bartos D, Stoian R, Szabo B, Cioltean C, Iancu I, et al. Short-term outcome and survival after multiorgan resection for locally advanced colo-rectal cancer. Identification of risk factors. *Ann Ital Chir*. 2018;89:229-36.
 13. Elias D, Gilly F, Boutitie F, Quenet F, Bereder JM, Mansvelt B, et al. Peritoneal colorectal carcinomatosis treated with surgery and perioperative intraperitoneal chemotherapy: retrospective analysis of 523 patients from a multicentric French study. *Journal of clinical oncology* : official journal of the American Society of Clinical Oncology. 2010;28(1):63-8.
 14. Weber T, Roitman M, Link KH. Current status of cytoreductive surgery with hyperthermic intraperitoneal chemotherapy in patients with peritoneal carcinomatosis from colorectal cancer. *Clinical colorectal cancer*. 2012;11(3):167-76.
 15. Araújo RC, Lopes G, Aisen M. Role of Cytoreduction Surgery With HIPEC in the Management of Peritoneal Carcinomatosis From Colorectal Cancer and Pseudomyxoma Peritonei. *Curr Colorectal Cancer Rep*. 2015:1-6.
 16. Cavaliere F, De Simone M, Virzi S, Deraco M, Rossi CR, Garofalo A, et al. Prognostic factors and oncologic outcome in 146 patients with colorectal peritoneal carcinomatosis treated with cytoreductive surgery combined with hyperthermic intraperitoneal chemotherapy: Italian multicenter study S.I.T.I.L.O. *Eur J Surg Oncol*. 2011;37(2):148-54.
 17. Chua TC, Morris DL, Saxena A, Esquivel J, Liauw W, Doerfer J, et al. Influence of modern systemic therapies as adjunct to cytoreduction and perioperative intraperitoneal chemotherapy for patients with colorectal peritoneal carcinomatosis: a multicenter study. *Annals of surgical oncology*. 2011;18(6):1560-7.
 18. Rettenmaier MA, Mendivil AA, Gray CM, Chapman AP, Stone MK, Tinnerman EJ, et al. Intra-abdominal temperature distribution during consolidation hyperthermic intraperitoneal chemotherapy with carboplatin in the treatment of advanced stage ovarian carcinoma. *International journal of hyperthermia* : the official journal of European Society for Hyperthermic Oncology, North American Hyperthermia Group. 2015:1-7.
 19. Van der Speeten K, Stuart OA, Sugarbaker PH. Pharmacology of perioperative intraperitoneal and intravenous chemotherapy in patients with peritoneal surface malignancy. *Surgical oncology clinics of North America*. 2012;21(4):577-97.
 20. Bartos A, Bartos D, Herdean A, Szabo B, Militaru C, Raluca S, et al. Hyperthermic intraperitoneal chemotherapy (HIPEC). Mechanisms of action and the role of HIPEC in the treatment of peritoneal carcinomatosis. *Ann Ital Chir*. 2018;89:513-27.
 21. Cashin PH, Graf W, Nygren P, Mahteme H. Cytoreductive surgery and intraperitoneal chemotherapy for colorectal peritoneal carcinomatosis: prognosis and treatment of recurrences in a cohort study. *Eur J Surg Oncol*. 2012;38(6):509-15.
 22. Furman MJ, Picotte RJ, Wante MJ, Rajeshkumar BR, Whalen GF, Lambert LA. Higher flow rates improve heating during hyperthermic intraperitoneal chemoperfusion. *Journal of surgical oncology*. 2014;110(8):970-5.
 23. Fujiwara K, Armstrong D, Morgan M, Markman M. Principles and practice of intraperitoneal chemotherapy for ovarian cancer. *International journal of gynecological cancer* : official journal of the International Gynecological Cancer Society. 2007;17(1):1-20.
 24. Bartos A, Bartos D, Dunca F, Mocanu L, Zaharie F, Iancu M, et al. Multi-organ resections for colorectal cancer: analysis of potential factors with role in the occurrence of postoperative complications and deaths. *Chirurgia*. 2012;107(4):476-82.
 25. Sharma D. Health-related quality of life and its assessment in GI Surgery. *Indian Journal of Surgery*. 2004;66(6).
 26. Clavien PA, Barkun J, de Oliveira ML, Vauthey JN, Dindo D, Schulick RD, et al. The Clavien-Dindo classification of surgical complications: five-year experience. *Annals of surgery*. 2009;250(2):187-96.
 27. Verwaal VJ, van Ruth S, de Bree E, van Sloothen GW, van Tinteren H, Boot H, et al. Randomized trial of cytoreduction and hyperthermic intraperitoneal chemotherapy versus systemic chemotherapy and palliative surgery in patients with peritoneal carcinomatosis of colorectal cancer. *Journal of clinical oncology* : official journal of the American Society of Clinical Oncology. 2003;21(20):3737-43.
 28. Elias D, Glehen O, Pocard M, Quenet F, Goere D, Arvieux C, et al. A comparative study of complete cytoreductive surgery plus intraperitoneal chemotherapy to treat peritoneal dissemination from colon, rectum, small bowel, and nonpseudomyxoma appendix. *Annals of surgery*. 2010;251(5):896-901.
 29. Glehen O, Kwiatkowski F, Sugarbaker PH, Elias D, Levine EA, De Simone M, et al. Cytoreductive surgery combined with perioperative intraperitoneal chemotherapy for the management of peritoneal carcinomatosis from colorectal cancer: a multi-institutional study. *Journal of clinical oncology* : official journal of the American Society of Clinical Oncology. 2004;22(16):3284-92.
 30. Cao C, Yan TD, Black D, Morris DL. A systematic review and meta-analysis of cytoreductive surgery with perioperative intraperitoneal chemotherapy for peritoneal carcinomatosis of colorectal origin. *Annals of surgical oncology*. 2009;16(8):2152-65.
 31. van Driel WJ, Koole SN, Sikorska K, Schagen van Leeuwen JH, Schreuder HWR, Hermans RHM, et al. Hyperthermic Intraperitoneal Chemotherapy in Ovarian Cancer. *The New England journal of medicine*. 2018;378(3):230-40.
 32. Dubé P, Sideris L, Law C. Guidelines on the use of cytoreductive surgery and hyperthermic intraperitoneal chemotherapy in patients with peritoneal surface malignancy arising from colorectal or appendiceal neoplasms. *Curr Oncol*. 2015;22:100-12.
 33. Votanopoulos KI, Newman NA, Russell G, Ihemelandu C, Shen P, Stewart JH, et al. Outcomes of Cytoreductive Surgery (CRS) with hyperthermic intraperitoneal chemotherapy (HIPEC) in patients older than 70 years; survival benefit at considerable morbidity and mortality. *Annals of surgical oncology*. 2013;20(11):3497-503.
 34. Tabrizian P, Jibara G, Shrager B, Franssen B, Yang MJ, Sarpel U, et al. Outcomes for cytoreductive surgery and hyperthermic intraperitoneal chemotherapy in the elderly. *Surgical oncology*. 2013; 22(3):184-9.
 35. McPartland SJ, Goodman MD. The effect of elevated body mass index on outcomes following cytoreductive surgery with hyperthermic intraperitoneal chemotherapy. *Annals of surgical oncology*. 2014;21(5):1463-7.
 36. Votanopoulos KI, Swords DS, Swett KR, Randle RW, Shen P, Stewart JH, et al. Obesity and peritoneal surface disease: outcomes after cytoreductive surgery with hyperthermic intraperitoneal chemotherapy for appendiceal and colon primary tumors. *Annals of surgical oncology*. 2013;20(12):3899-904.
 37. Koh JL, Yan TD, Glenn D, Morris DL. Evaluation of preoperative computed tomography in estimating peritoneal cancer index in colorectal peritoneal carcinomatosis. *Annals of surgical oncology*. 2009;16(2):327-33.
 38. Arjona-Sanchez A, Barrios P, Boldo-Roda E, Camps B, Carrasco-Campos J, Concepcion Martin V, et al. HIPECT4: multicentre, randomized clinical trial to evaluate safety and efficacy of Hyperthermic intra-peritoneal chemotherapy (HIPEC) with Mitomycin C used during surgery for treatment of locally advanced

- colorectal carcinoma. *BMC cancer*. 2018;18(1):183.
39. Passot G, Mohkam K, Cotte E, Glehen O. Intra-operative peritoneal lavage for colorectal cancer. *World J Gastroenterol*. 2014;20(8):1935-9.
 40. Elias D, Sideris L, Pocard M, Ouellet JF, Boige V, Lasser P, et al. Results of R0 resection for colorectal liver metastases associated with extrahepatic disease. *Annals of surgical oncology*. 2004;11(3):274-80.
 41. Molnar C, Vlad-Olimpiu B, Marian B, Cornelia T, Simona G. Survival and functional and oncological outcomes following intersphincteric resection for low rectal cancer: short-term results. *The Journal of international medical research*. 2018;46(4):1617-25.
 42. Russu PC, Molnar C, Gurzu S, Jung I, Voidazan TS, Copotoiu C. The role of clinical and pathological assessment in choosing the best therapeutic management to improve survival in rectal cancer. *Romanian journal of morphology and embryology = Revue roumaine de morphologie et embryologie*. 2016;57(4):1253-9.
 43. Van Oudheusden TR, Braam HJ. Poor Outcome After Cytoreductive Surgery and HIPEC for Colorectal Peritoneal Carcinomatosis With Signet Ring Cell Histology. *Journal of surgical oncology*. 2014.
 44. Elias D, Benizri E, Pocard M, Ducreux M, Boige V, Lasser P. Treatment of synchronous peritoneal carcinomatosis and liver metastases from colorectal cancer. *Eur J Surg Oncol*. 2006;32(6):632-6.
 45. van Oudheusden TR, Braam HJ, Nienhuijs SW, Wiezer MJ, van Ramshorst B, Luyer MD, et al. Cytoreduction and hyperthermic intraperitoneal chemotherapy: a feasible and effective option for colorectal cancer patients after emergency surgery in the presence of peritoneal carcinomatosis. *Annals of surgical oncology*. 2014;21(8):2621-6.
 46. Kuijpers AM, Hauptmann M, Aalbers AG, Nienhuijs SW, de Hingh IH, Wiezer MJ, et al. Cytoreduction and hyperthermic intraperitoneal chemotherapy: The learning curve reassessed. *Eur J Surg Oncol*. 2015.
 47. Kitayama J. Intraperitoneal chemotherapy against peritoneal carcinomatosis: current status and future perspective. *Surgical oncology*. 2014;23(2):99-106.
 48. Elias D, Lefevre JH, Chevalier J, Brouquet A, Marchal F, Classe JM, et al. Complete cytoreductive surgery plus intraperitoneal chemotherapy with oxaliplatin for peritoneal carcinomatosis of colorectal origin. *Journal of clinical oncology : official journal of the American Society of Clinical Oncology*. 2009;27(5):681-5.
 49. Quenet F, Elias D, Roca L, Goere D, Ghouti L, Pocard M, et al. A UNICANCER phase III trial of hyperthermic intra-peritoneal chemotherapy (HIPEC) for colorectal peritoneal carcinomatosis (PC): PRODIGE 7. *Journal of Clinical Oncology*. 2018;36(18_suppl):LBA3503-LBA.
 50. Capone A, Valle M, Proietti F, Federici O, Garofalo A, Petrosillo N. Postoperative infections in cytoreductive surgery with hyperthermic intraperitoneal intraoperative chemotherapy for peritoneal carcinomatosis. *Journal of surgical oncology*. 2007;96(6):507-13.
 51. Terzi C, Arslan NC, Canda AE. Peritoneal carcinomatosis of gastrointestinal tumors: Where are we now? *World Journal of Gastroenterology : WJG*. 2014;20(39):14371-80.
 52. Canda AE, Sokmen S, Terzi C, Arslan C, Oztop I, Karabulut B, et al. Complications and toxicities after cytoreductive surgery and hyperthermic intraperitoneal chemotherapy. *Annals of surgical oncology*. 2013;20(4):1082-7.
 53. Andreasson H, Lorant T, Pahlman L, Graf W, Mahteme H. Cytoreductive surgery plus perioperative intraperitoneal chemotherapy in pseudomyxoma peritonei: aspects of the learning curve. *Eur J Surg Oncol*. 2014;40(8):930-6.
 54. Wong JF, Tan GH, Wang W, Soo KC, Teo MC. Repeat Cytoreductive Surgery and HIPEC for Peritoneal Surface Malignancy and Peritoneal Carcinomatosis. *World journal of surgery*. 2015;39(6):1578-83.
 55. Bartos A, Bartos D, Szabo B, Breazu C, Opincariu I, Mironiuc A, et al. Recent achievements in colorectal cancer diagnostic and therapy by the use of nanoparticles. *Drug Metabolism Reviews*. 2016;48(1):27-46.
 56. Cesna V, Sukovas A, Jasukaitiene A, Naginiene R, Barauskas G, Dambrauskas Z, et al. Narrow line between benefit and harm: Additivity of hyperthermia to cisplatin cytotoxicity in different gastrointestinal cancer cells. *World J Gastroenterol*. 2018;24(10):1072-83.
 57. Lemoine L, Thijssen E, Carleer R, Cops J, Lemmens V, Eyken PV, et al. Body surface area-based versus concentration-based intraperitoneal perioperative chemotherapy in a rat model of colorectal peritoneal surface malignancy: pharmacologic guidance towards standardization. *Oncotarget*. 2019;10(14):1407-24.
 58. Yonemura Y, Canbay E, Ishibashi H. Prognostic factors of peritoneal metastases from colorectal cancer following cytoreductive surgery and perioperative chemotherapy. *ScientificWorldJournal*. 2013;2013:978394.
 59. Hompes D, D'Hoore A, Van Cutsem E, Fieus S, Ceelen W, Peeters M, et al. The treatment of peritoneal carcinomatosis of colorectal cancer with complete cytoreductive surgery and hyperthermic intraperitoneal perioperative chemotherapy (HIPEC) with oxaliplatin: a Belgian multicentre prospective phase II clinical study. *Annals of surgical oncology*. 2012;19(7):2186-94.
 60. Quenet F, Goere D, Mehta SS, Roca L, Dumont F, Hessissen M, et al. Results of two bi-institutional prospective studies using intraperitoneal oxaliplatin with or without irinotecan during HIPEC after cytoreductive surgery for colorectal carcinomatosis. *Annals of surgery*. 2011;254(2):294-301.
 61. Franko J, Ibrahim Z, Gusani N. Cytoreductive surgery and hyperthermic intraperitoneal chemoperfusion versus systemic chemotherapy alone for colorectal peritoneal carcinomatosis. *Cancer*. 2010;116:3756-62.
 62. Verwaal VJ, van Ruth S, Witkamp A, Boot H, van Slooten G, Zoetmulder FAN. Long-Term Survival of Peritoneal Carcinomatosis of Colorectal Origin. *Annals of surgical oncology*. 2005;12(1):65-71.