

General Report

Chirurgia (2016) 111: 463-475
No. 6, November-December
Copyright© Celsius

<http://dx.doi.org/10.21614/chirurgia.111.6.463>

The Importance of Preoperative Staging of Rectal Cancer Using Multiparametric MRI *Part II: TNM Cancer Staging*

Ferdinand Bauer

Director of Radiology Clinics in Kaufbeuren - Landsberg - Füssen, Germany

The reason a A) classic staging, B) modern staging or C) restaging is performed must be taken into consideration in order to have an appropriate staging. In general, staging is performed histopathologically after surgery, and offers information about the pTNM prognosis. The introduction of neoadjuvant therapy placed staging to the foreground and modified its base conditions: from the postoperative to the preoperative. Histological examination was replaced with imaging. The role of staging became decisive when choosing an optimal individual treatment, which reflects in high requirements as to its quality. Is it possible that imaging methods offer the same quality and safety of staging? The current answer is a decisive "yes" because in MRI "what you see is what you get". If the measured depth is for example 5 mm in MRI, it also will be 5 mm in the histological result (Fig. 23). Consequently, MRI result is equivalent with the histological one. Therefore, it is logical to switch from anatomopathological staging to the imaging one.

Classic staging

In classic staging the reference point is the rectal wall and neither the mesorectal fascia nor the T3 tumour heterogeneity is taken into consideration. Note that EUS can only use classic staging. (Fig. 24)

Corresponding author: Ferdinand Bauer, MD
Radiology Specialist
Director of Radiology Clinics in Kaufbeuren -
- Landsberg - Füssen, Germany
E-mail: Ferdinand.Bauer@radiologie-kaufbeuren.de

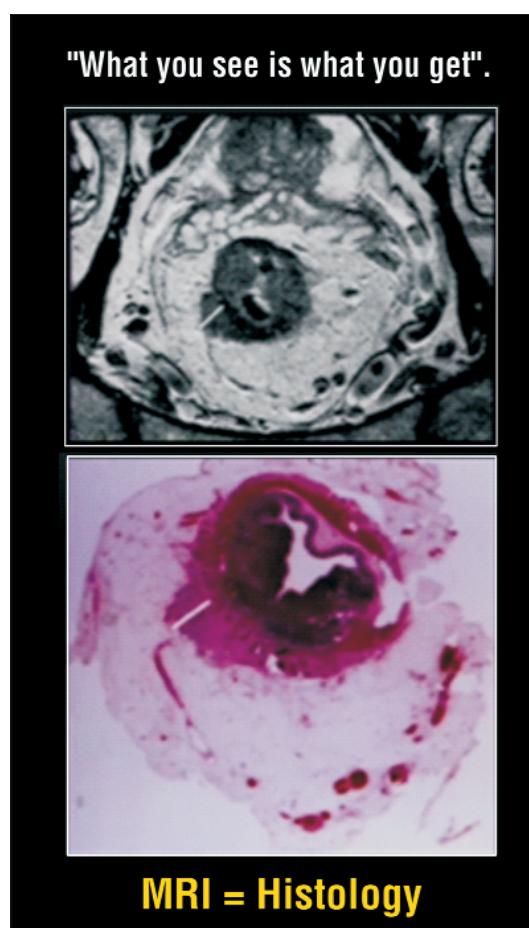


Figure 23. (A) MRI image of a rectal carcinoma. (B) Histopathological preparation of the same rectal carcinoma. Note that: MRI images (A) show exactly the same tumour extension in the mesorectum as the histopathological preparation (B) (white line)

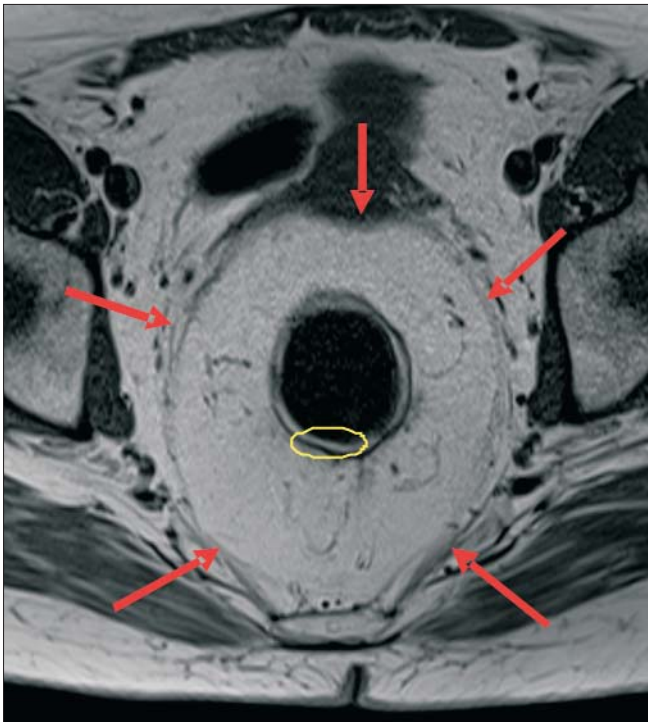


Figure 24. Yellow circle (rectal wall): the rectal wall is the main reference point in classic staging; Arrows (MRF): Mesorectal fascia (MRF) is the reference point in modern staging

1. Local excision
(Transanal Endoscopic Microsurgery = TEM);
2. TME (Total Mesorectal Excision);
3. TME with short term RCT;
4. TME with long term RCT.

TNM staging: T stages

T1 stage

T1 tumour is characterized by the invasion of the submucosal layer to the muscularis propria (Fig. 26). The best diagnostic method for early initial staging of incipient tumours is endoscopic ultrasonography (EUS). MRI does not have the same diagnostic performance in the case of superficial tumours (35), however our experience shows that very good results can be obtained with 3T phased array, after an adequate preparation of the patient: miniclistier (Microlax) 30 minutes prior to the examination, enema with maximum 100 ml of water depending on the tumour localization and Buscopan 20-40 mg IV. We deliberately renounced the gel due to the compression resulted on the rectal wall and mesorectum, which leads to the modification of the distance to the MRF (36).

T1 tumours are often treated by local excision or by transanal endoscopic microsurgery (TEM). The optimal method for a differentiation between T1 and T2 tumours is the endorectal ultrasound (37,38).

Modern staging

In modern staging, the reference point is the space where the surgeon actions, namely the avascular space between mesorectal fascia and pelvic fascia. Additional to this basic issue, the following elements are considered in modern staging: the subdivision of T3 tumours, assessing lymph nodes, their number and location and the existence of extramural venous invasion (EMVI).

Modern staging makes available different therapeutic options (Fig. 25):

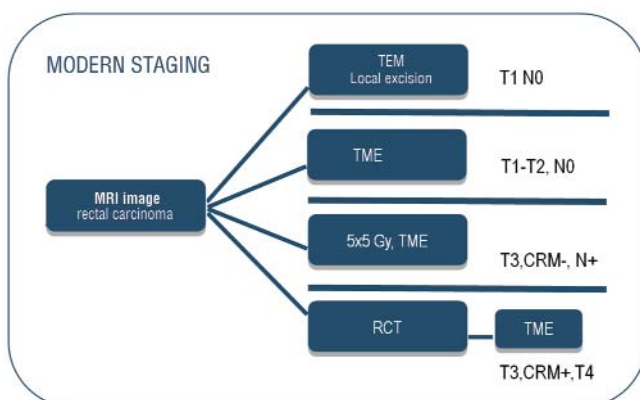


Figure 25. Treatment options depending on the result of preoperative staging

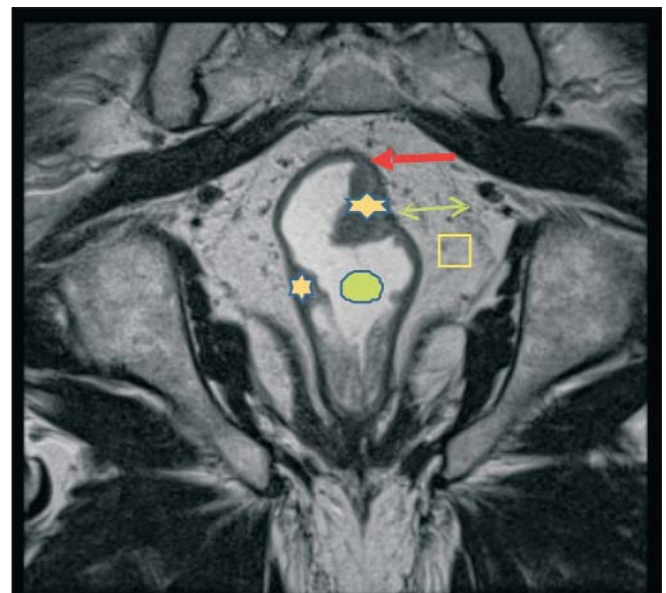


Figure 26. HD paracoronar MRI, stage T1: Rectal carcinoma has an average signal intensity (star), is well delimited after the water enema (white substance in the rectum - green circle). We notice that the tumour invades the submucosal layer without the infiltration of muscularis propria. The black strip (red arrow), namely muscularis propria is intact, the mesorectum is intact (square). Great distance to MRF (green arrow), there are no suspect lymph nodes in the mesorectum

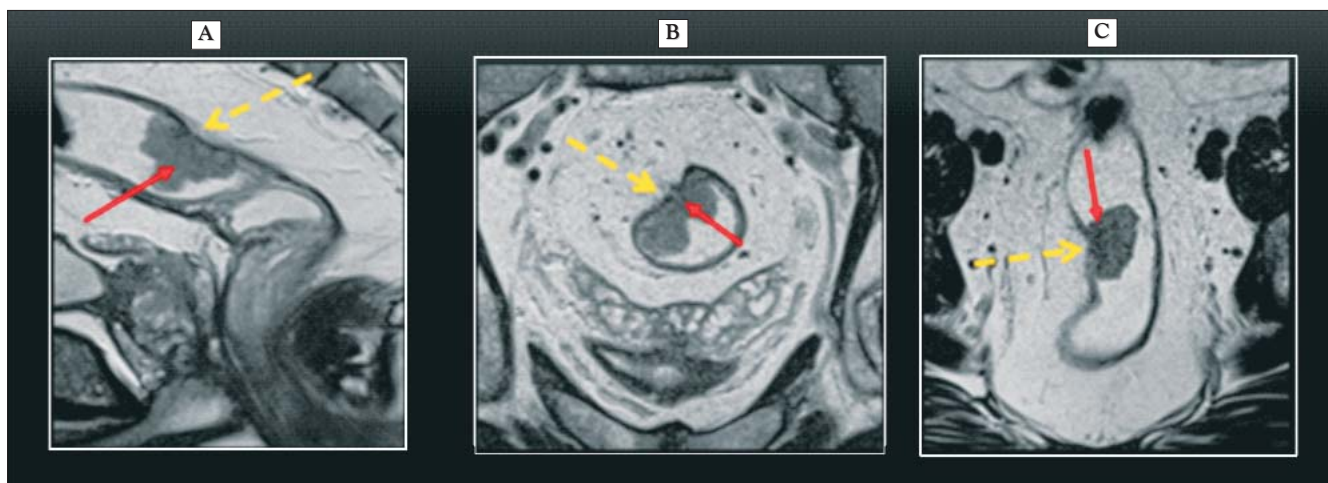


Figure 27. T2 stage a. sagittal, b. paraxial, c. paracoronar HD MRI, 3 mm, presenting a histologically confirmed rectal carcinoma (red arrow) in the upper third, which infiltrates the muscular wall (black strip) without exceeding its outer margin. One can observe the retraction of the rectal wall at the level of the tumour front (yellow arrow)

T2 stage

T2 tumours are characterized by the invasion of muscular layer.

While T1 lesions are limited to the submucosa, T2 lesions infiltrate muscularis propria without exceeding its outer margin. The fact that MRI does not help to differentiate between T1 and T2 has a minor importance, since these lesions have the same therapeutic approach and a good prognosis. The key element of the imaging result is an intact hypodense line (black strip) which surrounds the rectal wall (Fig. 27), an integrity sign of the outer margin of the muscular layer (35).

T3 stage

The T3 tumour diagnosis is established when muscularis propria is penetrated by a solid tumour which infiltrates the mesorectal fat. (Fig. 28)

The degree of extramural growth (the infiltration of the mesorectum) is an important prognostic factor for local recurrence and it is mandatory to be mentioned in millimetres in the radiology report!

Special case: "Borderline T3 lesions" or the problem of T2 tumour overstaging

T2 tumours having a desmoplastic reaction can simulate the invasion of mesorectal fat due to hypointense spiculations. These tumours are named "borderline T3 lesions" (39). The discontinuity of the external muscular layer does not always indicate its involvement. The perirectal infiltration can be both the result of tumoral growth to T3 and a desmoplastic reaction surrounding the tumour, the two being hard to differentiate (Fig. 29) (39,40). This appearance can also be created by small transmural vessels. In this case, MRI can lead to overstaging. From the therapeutic point of view the

differentiation between T2 and T3 stages is not important (41,42), since the treatment of these lesions is identical: TME alone or short term RCT followed by TME. For safety and for avoiding the subclassification of a tumour it is recommended to have a classification of T3 tumours with uncertain infiltration of the right mesorectum.

Special case: Desmoplastic reactions and the differentiation between T2 and T3

Sometimes it is impossible to differentiate between the tumoral invasion in the mesorectum and desmoplastic reactions (Fig. 29). Desmoplastic reactions are tissular reactive modifications which occur around a tumour, resulting

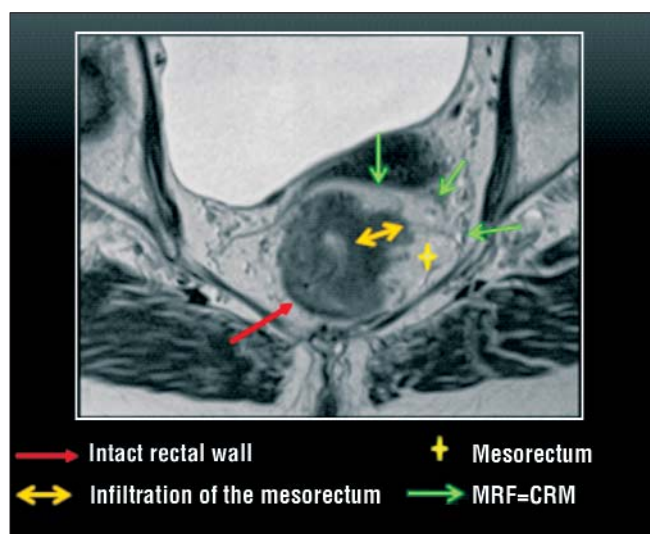


Figure 28. T3 stage T2 paraaxial MRI, presenting a solid tumour invading the mesorectal fat - a typical appearance of T3 tumours

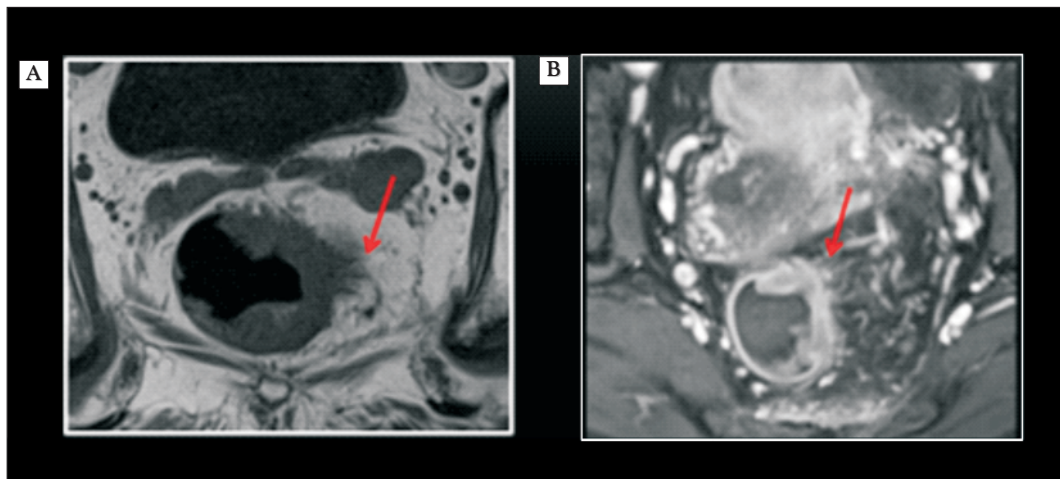


Figure 29. MRI (A) native axial and (B) axial T1-weighted FS with radiocontrast agents presenting a rectal tumour with fine spiculations (arrow) towards the mesorectum. None of the images shows very clear the nature of these spiculations (T3 tumoral extension vs. T2 with desmoplastic reaction)

in the majority of cases in dense fibrosis which may contain tumoral cells. The incapability of differentiating between desmoplastic reactions and real tumoral extensions is not typical for MRI, but it is a well known problem in EUS examinations (41). For this differentiation it is more important to have an exact description of the relation between the tumour and mesorectal fascia, namely with the anticipated TME resection plan, in order to evaluate the possibility of a free CRM (41,43,44).

In principle, if fine spiculations can be observed from the tumour towards the mesorectum, the most probable cause is a desmoplastic reaction. (Fig. 29)

Subdivision of T3 tumours

The subdivision of T3 tumours is much more important than the differentiation between T2 and early-stage T3. The stratification of T3 tumours is capital for the therapeutic decision consisting of an immediate surgical procedure (TME) or of a preoperative RCT followed by a surgical procedure, depending on the a, b, c or d subcategory of T3 (45).

Early-stage T3 tumours (Fig. 30), hence a and b subcategories, present a minimal infiltration of the mesorectum (< 5 mm) and have the same treatment and survival rate as T2 tumours (40). Therefore, the therapeutic option in this case is TME. T3 advanced tumours (Fig. 31), c and d subcategories (> 5 mm), react like T4 tumours. The therapeutic option in this case is preoperative long-term RCT followed by TME! (39).

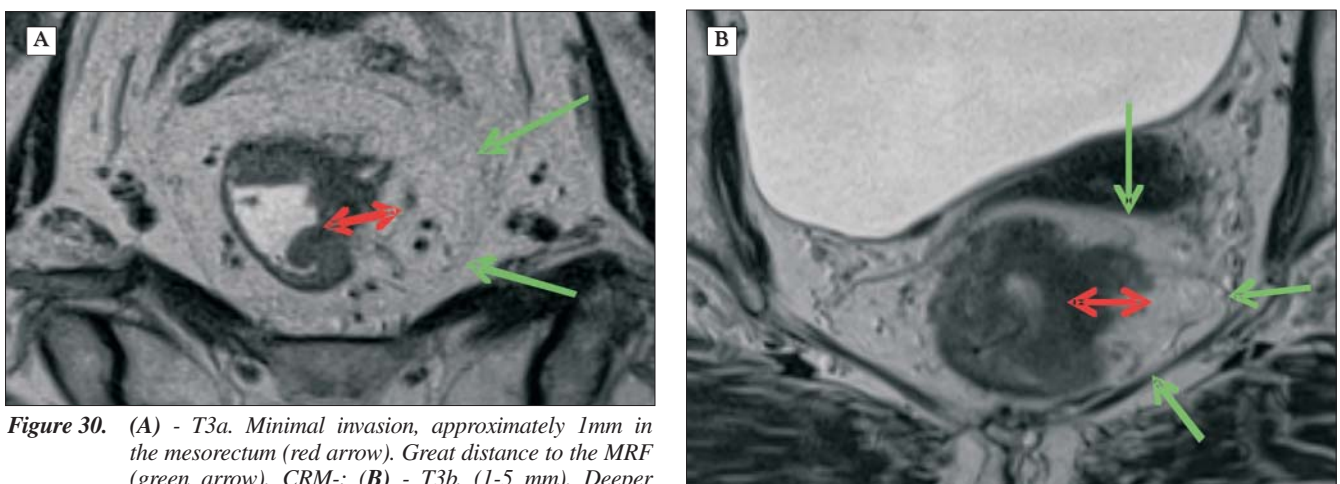


Figure 30. (A) - T3a. Minimal invasion, approximately 1mm in the mesorectum (red arrow). Great distance to the MRF (green arrow), CRM-; (B) - T3b. (1-5 mm). Deeper invasion of the mesorectum. Great distance to MRF, CRM-

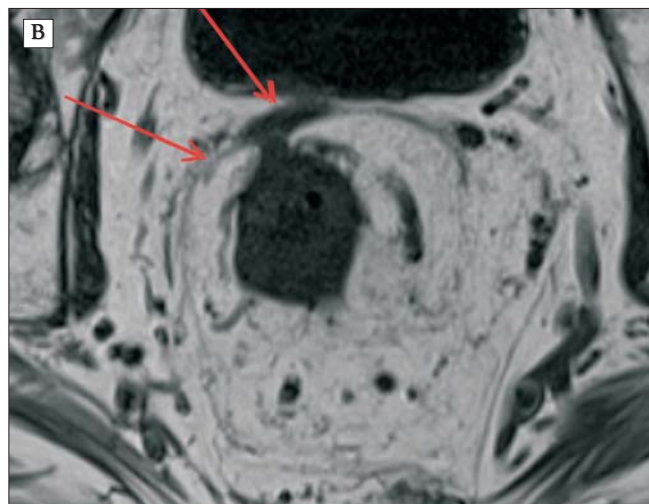
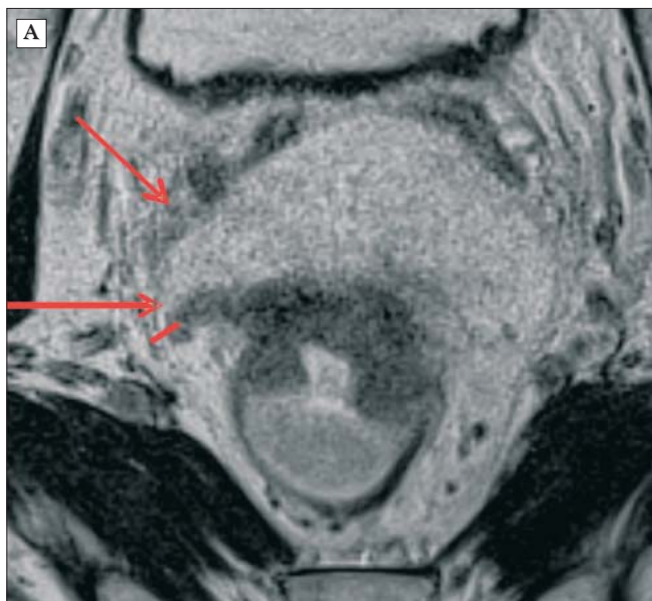


Figure 31. (A) - T3c (5-15 mm) Extensive invasion of the mesorectum. Small distance to MRF, CRM+ (B) - T3d (>15 mm) Complete invasion of the mesorectum with MRF infiltration, CRM+

The infiltration of the perirectal fat can be: minimal, limited, extended or complete

The infiltration of the mesorectum

- a. Minimal invasion
- b. Limited invasion
- c. Extended invasion
- d. Complete invasion

The stratification of T3 tumours refers to the same T3 tumoral stage. However, the treatment and the prognosis are totally different!

In the case of T3 lesions, the degree of their extramural extension is an independent prognostic factor which is mandatory to be evaluated during MRI. T3 tumours with extramural invasion less than 5 mm (T3a and T3b) have a better prognosis, with a specific 5-year survival rate of 85% (43). These patients do not have great advantages after preoperative RCT. T3 tumours with extramural invasion greater than 5 mm have a specific survival rate of 54%. If the treatment is surgical, it is recommended to be associated with a preoperative long-term RCT. (35).

Anglo-American literature uses "good", "bad" and "ugly" in order to define rectal cancer prognosis (46). This is in fact the prognosis of T3 subcategories. These denominations can sometimes be confusing, but the basic idea is simple: the closer the tumour to the rectal wall, the better the prognosis - "good". The more extensive the invasion in the mesorectum, the worse the prognosis - "bad". If the process reaches or out-reaches the mesorectal fascia the prognosis is "ugly".

T4 stage

A T4 tumour is an advanced tumour which invades the adjacent structures as the pelvic floor, vagina, prostate, bladder or the seminal vesicles. The infiltration of adjacent organs can be seen very well with magnetic resonance (Fig. 32) (47). Much better than with CT or endosonography. These patients need a long term radiochemotherapy and an extensive surgical treatment.

T4 tumours are divided into T4a if there is an invasion of the anterior peritoneal reflection, and T4b if other pelvic structures are invaded (ESAGR072).

T staging specific to low rectal tumours: anal complex

Low rectal tumours are associated with higher rates of positive resection margins (CRM+), of local recurrences and lower survival rates (48). This is due to anatomical considerations and to the fact that the mesorectal layer gets narrower and almost disappears distally.

The initial MRI examination must allow defining the tumour position in relation to the sphincterian complex in order to identify patients who need preoperative RCT (49). Early-stage tumours traced through MRI, primary surgical treatment and avoiding sphincter irradiation lead to a better postoperative sphincterian function and to lower rates of anastomotic insufficiency (50). In the case of advanced low rectal tumours it was proven that preoperative radiochemotherapy increases the conservation rate of the sphincter and the survival rate without recurrences (51,52,53). Tumours which would have needed an abdominoperineal excision can be treated after RCT with ultra-low resection and coloanal anastomosis (54).

Shihab et al (55,56) recently proposed a T staging specific to low rectal tumours in order to better define the free margin

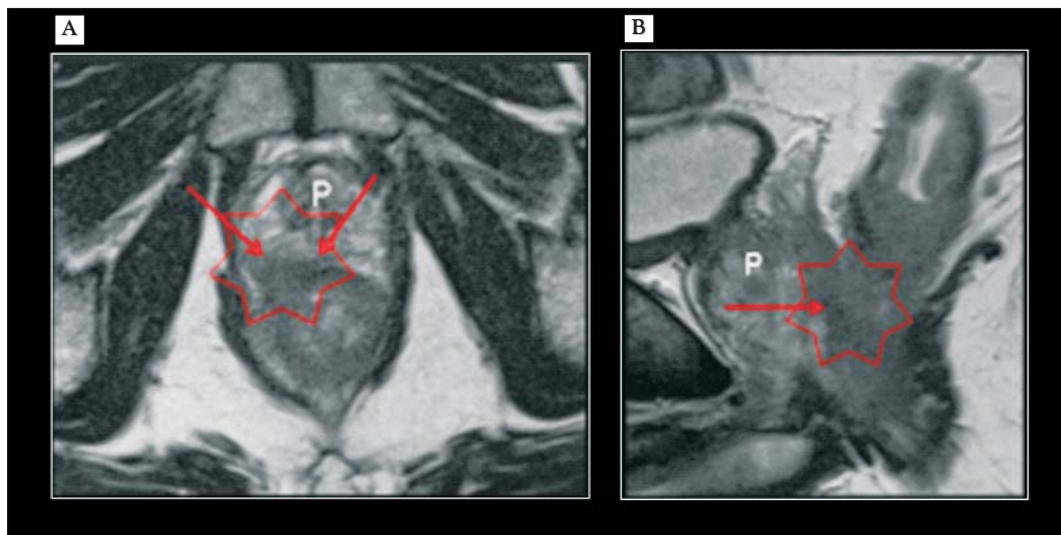


Figure 32. T4 stage MRI: (A) - sagittal, (B) - axial, presenting a T4 tumour which invades the prostate (P)

from the tumour (CRM-). This staging is based on paracoronaral T2-weighted images and is resumed in Fig. 33.

It permits surgeons to choose the resection plan. Indeed, in the case of low rectal tumours there are three major types of surgery depending on the tumour stage (49).

1. Low anterior resection is the en bloc resection of the rectum and mesorectum (TME) to the level of the pelvic floor with negative, distal and lateral resection margin (CRM-, Fig. 34 A). This technique can be performed for

low rectal tumours without sphincterian complex invasion. Thus, we can successfully avoid the sphincter morbidity associated with preoperative radiotherapy.

2. Low anterior resection with intersphincteric resection. If the tumour extends to the internal sphincter, low anterior resection can be continued into the intersphincteric plane (green line in Fig. 34 B). To obtain uninvolved margins, the intersphincteric plane must be tumour-free and the tumour should not extend to with-

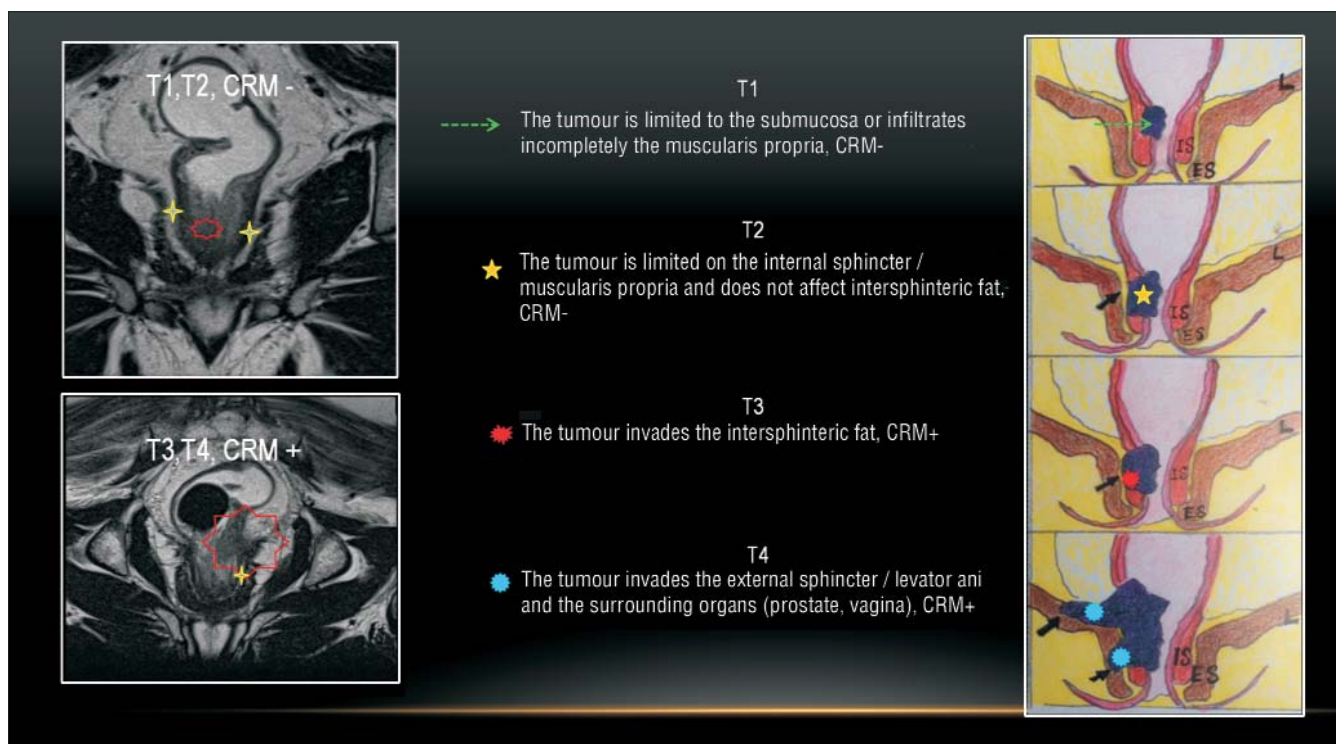


Figure 33. T staging specific to low rectal tumours with the infiltration of anal canal

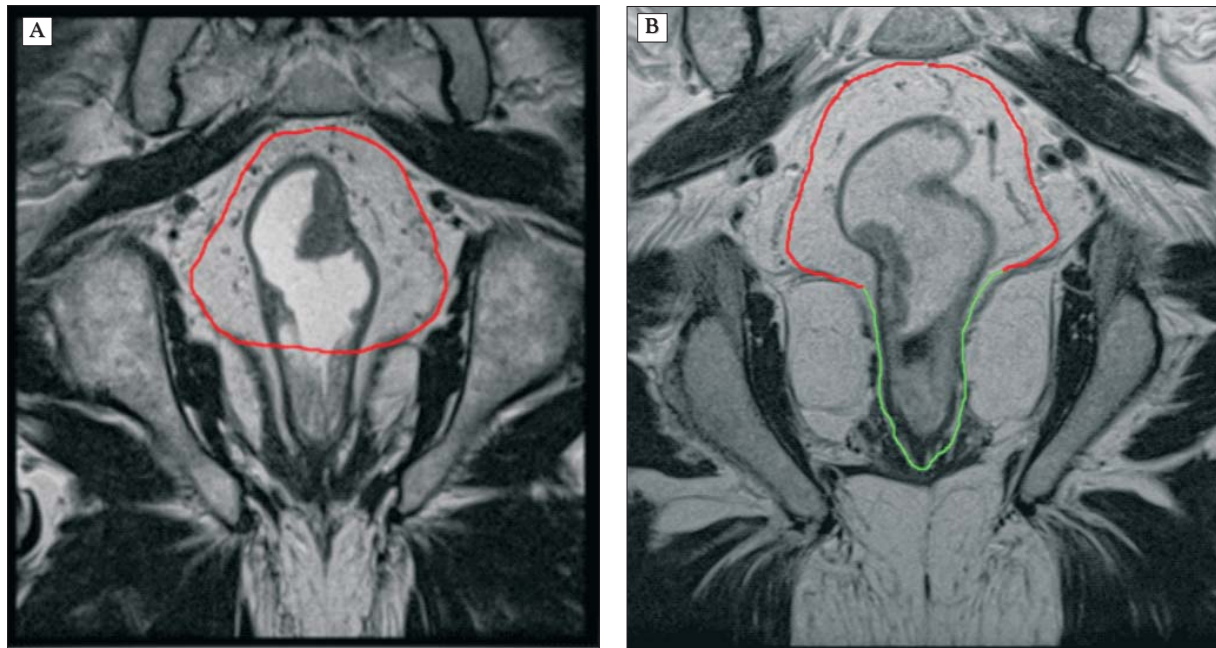


Figure 34. (A) The red contour marks the low anterior resection margin. (B) The resection margin extended to the end of intersphincteric plane (green line)

- in 1 mm of the outer border of the internal sphincter.
3. Extralevator abdominoperitoneal resection (APR):
 - a. Conventional APR (conventional abdominoperitoneal resection) - dashed line (Fig. 35 A). The oncologic outcome is poor due to the high rate of positive margins CRM+ (48).
 - b. Extralevator APR (extralevator abdominoperineal

resection) – Fig. 35 B: is a recent approach proposed by Holm et al (57). The main difference as against conventional APR is that the mesorectum is not dissected off the levator muscle; the levator muscle is resected en bloc with the lower rectum and anal canal. This creates a cylindrical specimen with more tissue surrounding the tumour with the benefit of a low rate

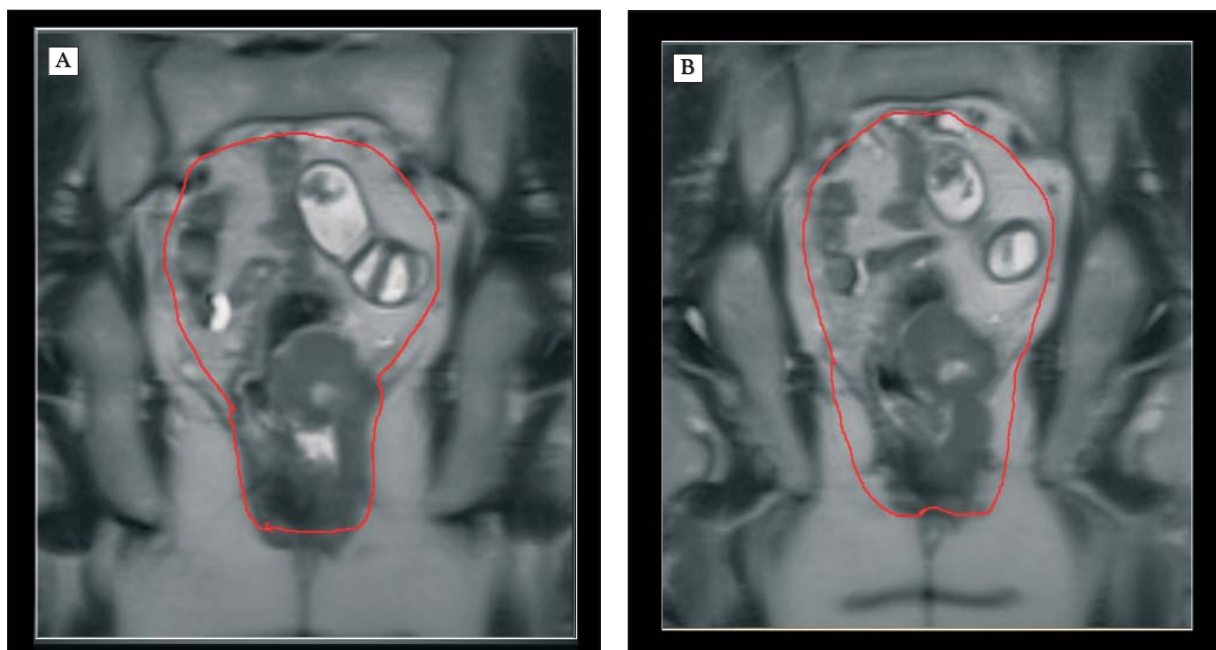


Figure 35. (A) conventional APR; (B) extralevator APR.

of positive resection margins, leading to a low rate of local recurrence (57).

This procedure is performed when the tumour extends into the full thickness of muscularis propria, into or beyond the levator muscles, and/or involves the intersphincteric space (stage 2, 3, or 4 on MRI images, Fig. 33).

Diagnostic clues at the workstation for staging low-lying tumours using MRI (49):

1. High-spatial-resolution T2weighted fast spin-echo coronal imaging must be added to optimally depict the tumour relationship with the levator and puborectal muscles, sphincter complex, and intersphincteric plane.
2. On coronal T2-weighted images, the beginning of the puborectalis sling marks the start of the narrowest part of the mesorectum; below lies the anal canal (comprised of mucosa, submucosa, internal sphincter, intersphincteric plane (1–2 mm), and external sphincter). The first question to answer in the case of low-lying tumours is where the lower edge of the tumour is located in relation to the puborectalis sling. If the tumour is located above the puborectalis sling, sphincter involvement can be easily excluded.
3. If the tumour extends below the puborectalis sling: Three areas will be evaluated and reported (Fig. 33): (a) muscularis propria — is it invaded partially or at its full thickness (stage 1 vs 2) (b) Is there an extension into the intersphincteric plane (stage 3) (c) Is there an extension into the external sphincter (stage 4).
4. The involvement of levator, puborectalis muscles, or external sphincter is considered stage 4.

Nodal staging: N stages

Detection, localization, characterization

Exact nodal staging is important because the number of metastatic nodes has been shown to affect the prognosis (Table 1) (49). The involvement of nodes in the proximity of mesorectal fascia is associated with a higher local recurrence risk. In the case of patients having metastatic nodes outside the mesorectal fascia, an extended node resection with removal of internal iliac nodes is necessary. This lymph node group is not removed when a regular TME is performed.

Three aspects have to be systematically analysed in nodal staging:

1. detection,
2. localization and
3. node characterization.

Table 1. N classification depending on positive nodes

Stage	Stage interpretation
Nx	The nodes cannot be evaluated
N0	Without nodal metastases
N1	1-3 endangered nodes
N2	Metastases \geq 4

1. Detection

Detection is most easily performed with DWI. Also, it helps to count more easily the endangered nodes. Depending on their number one can establish the stage: N1 – 1-3 endangered nodes, N2 – more than 4 endangered nodes.

DWI has a high sensitivity in detection (58), but a low sensitivity in description (benign vs. malignant). Low specificity is due to the high cellularity of normal node, which gives a hyperintense signal. The same hyperintense signal is also given by a normal size metastatic node (Fig. 36).

2. Localization

Localization is performed with multiplanar (axial, coronal sagittal) high resolution T2 or T1 weighted images. Lymph node localization has a very important role for surgical decision (classic TME vs. extended lymphadenectomy) and for individual therapeutic decisions (preoperative vs. postoperative RCT). Localization can be (Fig. 37):

- A. Intramesorectal: without problems since it is removed in a regular TME (Fig. 37 A).
- B. In the proximity of MRF: important prognostic factor for local recurrence. It must be mentioned in the radiological report because the involvement of nodes in the proximity of MRF is associated with a higher risk of local recurrence (Fig. 37 B).
- C. Extramesorectal: mandatory to be mentioned in order to be included in radiological and surgical treatment planning, since their resection is not included in standard TME. Thus, a considerable high risk of local recurrence is resulting (Fig. 37 D,C, Fig. 38 A). In this situation, there is the need for an extended surgical approach in order to remove all tumoral deposits or for an extended radiotherapy in the risk areas.

3. Characterization: benign vs. malignant

The characterization of metastatic lymph nodes is a true challenge for rectal cancer preoperative staging, no matter the modality chosen. NL characterization is performed A) by size and B) by morphology.

A. The lymph nodes size

A major problem for lymphatic invasion evaluation is that node size is not a reliable criteria (40), since micrometastasis in normal-sized lymph nodes is common (Fig. 39) (41,49).

There is a great risk of lymphatic metastasis even in T1 and T2 tumours (see Table 2). Table 3 presents the risk of metastasis depending on the node size: approximately 9% of 1-2mm nodes and 17% of 2-5mm nodes are malignant.

In conclusion, the size of a lymph node is not a reliable criterion for the evaluation of metastatic invasion, because we frequently find micrometastasis in very small nodes, under 5 mm.

Also, neither DWI is useful for differentiating subcentimetric benign or malignant nodes (35). DWI is very useful for

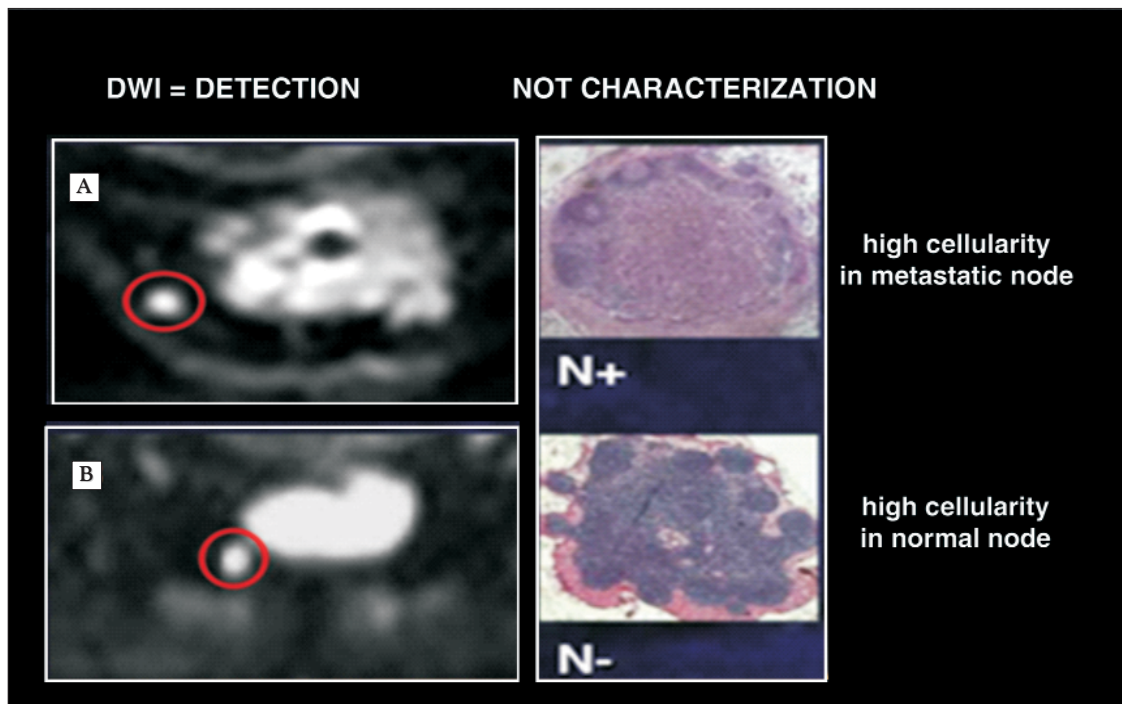


Figure 36. Two different cases which have the same DWI image, with high signal intensity. In the first case (A), the histology found a lymph node infiltration (N+). In the second case (B), there is a normal lymph node (N-). DWI MRI cannot differentiate between normal and pathological nodes because both cases present a high cellularity

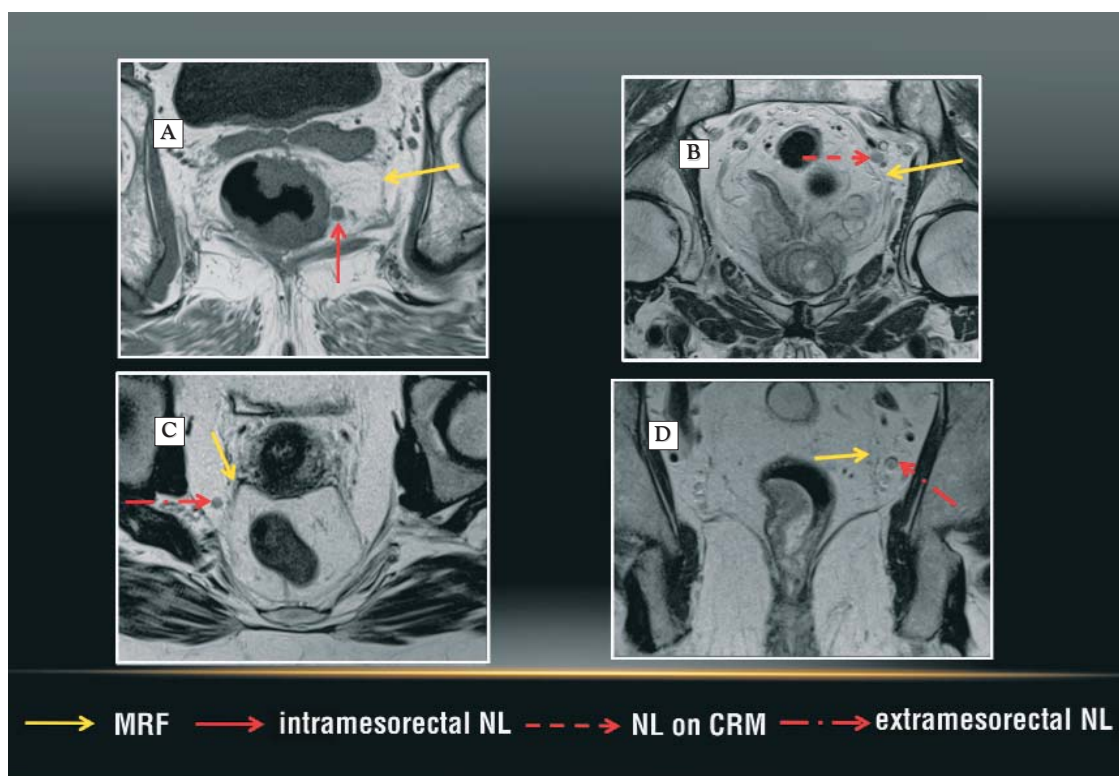


Figure 37. Lymph node localization using MRI

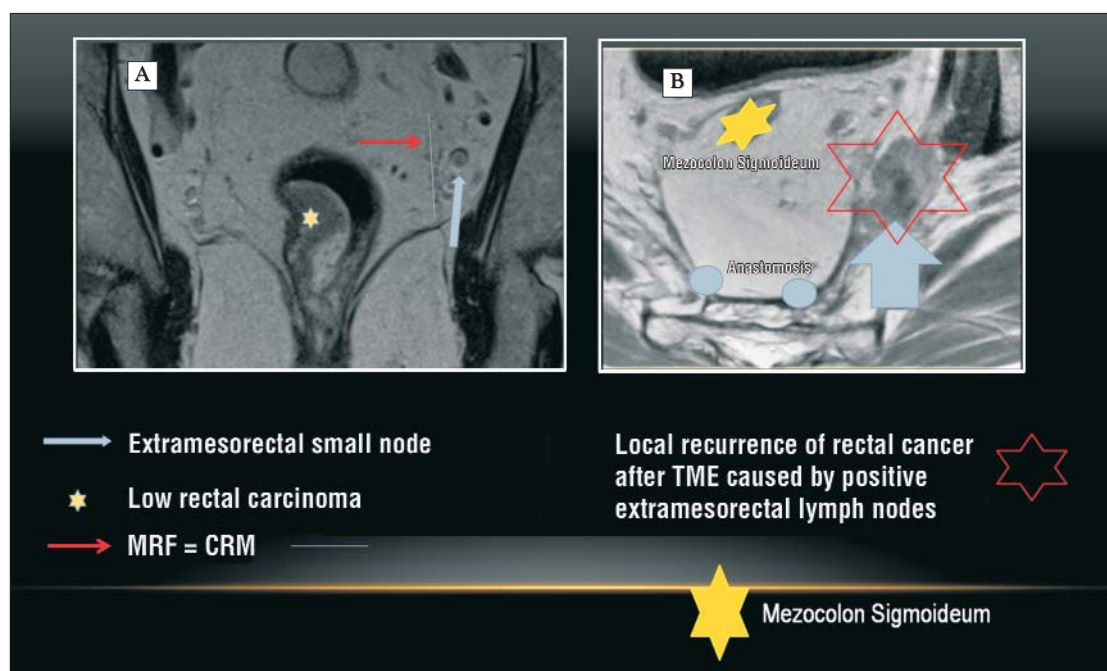


Figure 38. (A) T2w MRI before TME: Right T2 weighted lower rectal carcinoma. CRM- (yellow star) small NL on the left at 3 o'clock. The node was not removed through standard TME. (B) After 1 year after TME (without RCT). We see the same ganglion increased considerably as a sure sign of metastasis LG, (big blue arrow)

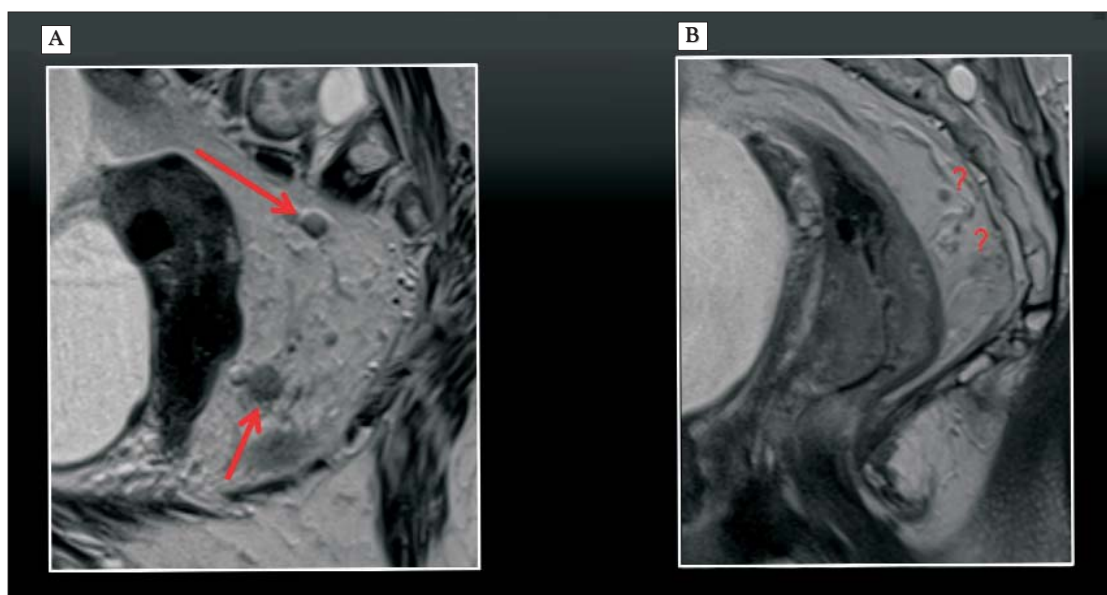


Figure 39. (A) NL > 5 mm surrounding the tumour are almost always infiltrated (N+) (B) The infiltration is harder to establish for small nodes, < 5 mm

detection but not for characterization (benign vs. malignant).

In general, in regular clinical practice (usually T4, T4 tumours) we can easily characterize lymph nodes using HD MRI, especially if they are over 5mm and surround the tumour (Fig. 39 A), since they are infiltrated for certain. As we mentioned before, small mesorectal nodes < 5 mm could create problems (Fig. 39 B), because some of them could include micrometastasis (59). In order to avoid a subclassifica-

tion of patients, we consider that all detected nodes have a malignant potential. Rectal cancer is renowned for small metastatic nodes.

B. The lymph nodes morphology

If the size is not a reliable criterion, then we must evaluate supplementary criteria, as the morphology (59,60) (Fig. 40):

- nonhomogeneous signal;

Table 2. The risk of lymphatic metastasis depending on the T tumour stage

Risk for N+	
T1	5-10%
T2	15-20%
T3	> 30%
T4	> 50%

- spiculated, irregular contour.

By using these supplementary morphological criteria, the diagnostic safety in evaluating lymphoganglionic infiltration increases considerably (60,61,62). Using these criteria, MRI can be used for evaluating nodal involvement with an accuracy of 85%, comparing to histological evaluation which is the reference standard (49). However, a negative MRI result cannot completely exclude lymphatic metastases, because imaging techniques cannot trace micrometastasis inside lymph nodes. Promising results for differentiating between N0 and N1/2 stages were obtained in MRI by using specific radio-contrast agents (63); radiocontrast agents based on superparamagnetic iron oxide were not approved in the USA by the Food and Drug Administration (FDA), nor in Europe by the European Medicines Agency. Consequently, they will be not used in clinical practice in the following years.

Diagnostic clues in terms of diagnosis for nodal staging using MRI (49):

Table 3. The risk of lymphatic metastasis depending on the node size

The criteria of size for N+		
Size	Positive	Total of nodes
< 0.5 mm	2%	of 169 nodes
0.5 – 1 mm	5%	of 145 nodes
1 – 2 mm	9%	of 268 nodes
2 – 5 mm	17%	of 327 nodes
5 – 10 mm	62%	of 54 nodes
> 10 mm	100%	of 9 nodes

1. Uniform nodes smaller than 10 mm with homogeneous signal intensity are not suspicious.
2. Nodes with irregular borders, mixed signal intensity, or both are considered to be suspicious.
3. Presence of one to three suspicious nodes is stage N1 and presence of four or more is stage N2.
4. Any lymph node lying within 1 mm of the CRM must be reported because it is highly suspicious of CRM involvement.
5. Recording the location and size of any suspicious pelvic sidewall lymph nodes is critical (61). Using this information, the radiation therapy team can change and adjust the therapy to obtain optimal results. Secondly, the surgeon will need to perform an extended lymph node resection with additional removal of the internal iliac nodes. This lymph node group is not removed when a regular TME is performed.

Extramural vascular invasion (EMVI)

Identifying extramural vascular invasion is an extremely important criterion for rectal cancer staging, its discovery indicating a systemic dissemination. EMVI is defined as the presence of malignant cells within blood vessels located beyond the muscularis propria (40). It can be identified in tumours that are at least category T3, and it represents an independent risk factor for local and especially distal recurrence, associated with low survival rates. Signs suggestive for EMVI are vessel with irregular contour or vessel with intermediary signal inside the lumen, situated close to the tumour (Fig. 41).

Histopathological studies show an EMVI incidence of 17-70%. Vascular invasion is associated with a quadruple risk of distal metastasis. EMVI can be visualized only with HD MRI with fine sections (3 mm). Bill Heald (64) characterizes EMVI as an important "tumoral marker" as to the unfavourable prognosis of advanced rectal carcinoma (> T3). As we mentioned before, vascular invasion is a systemic dissemination of cancer, which supposes an extremely high possibility of distal metastasis (liver, lungs). Thus, if EMVI is present, the prognosis remains bad due to distant metastases, even if the TME performed was of high quality. The death will occur not because of local complications or local recurrence, but because

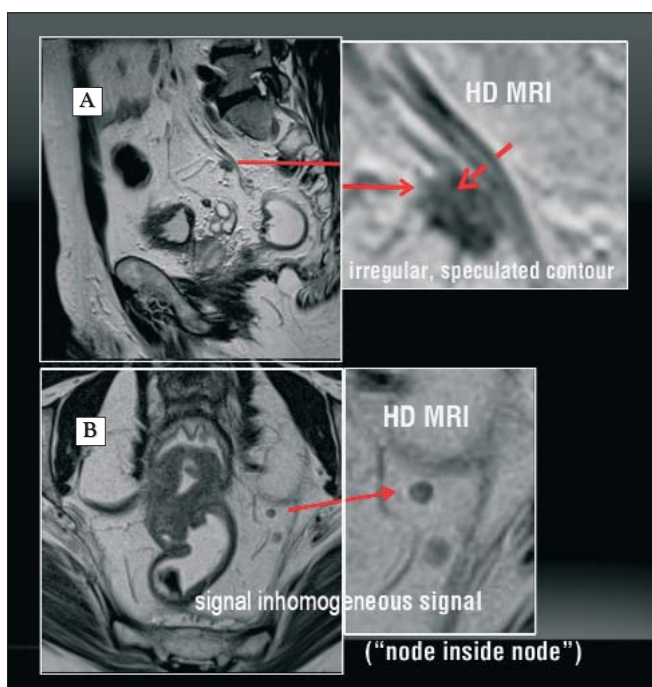


Figure 40. Additional morphological criteria for the evaluation of lymphatic infiltration using MRI. If lymph nodes have (A) an unclear and spiculated margin or (B) a heterogeneous appearance (node inside a node), we can be sure that they have metastases

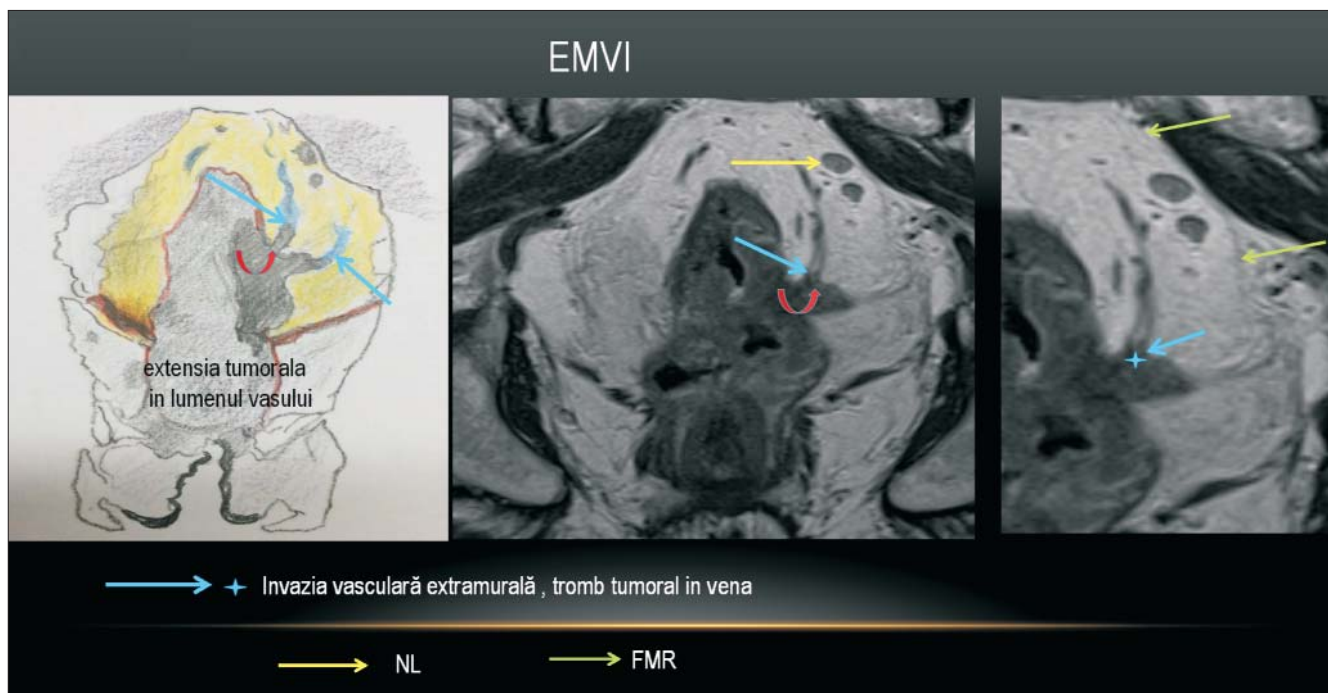


Figure 41. (A) Schematic representation and (B, C) MRI presenting extramural vascular invasion caused by a T3 tumour with mesorectal moderate infiltration at 3 o'clock and great distance to MRF, CRM- (blue arrows), with two intramesorectal NL (yellow arrow). The tumoral extension can be seen very well in the vessel lumen (red marks). Hence, there is a nodular and vascular dissemination. The last one has a powerful impact on the unfavourable prognosis of rectal carcinoma, even if the tumour is not extended (possible distance metastases via superior rectal vein, inferior mesenteric vein, portal vein, liver). The deep invasion is much more important than craniocaudal extension

of distant metastases. Therefore, EMVI has a more important prognostic value than lymphoganglionic local dissemination.

Used acronyms

APR	Abdominoperineal Resection
CRM	Circumferential Resection Margin
DWI	Diffusion weighted Imaging
EMVI	Extramural vascular invasion
EUS	Endoscopic Ultrasonography
FDA	Food and Drug Administration (USA)
MRF	Mesorectal fascia
HD	High-definition
MRI	Magnetic resonance imaging
NL	Lymph node
RT	Radiotherapy
RCT	Radiochemotherapy
RMN	Magnetic resonance
TEM	Transanal Endoscopic Microsurgery
TME	Total Mesorectal Excision

References

35. Araujo B, Costa FR, Correia R, Cunha RG. MR Imaging in rectal cancer - an essential and preferably universal tool in loco-regional staging. Congress: ESGAR 2015, e-Poster: EE-072.
36. Slater A, Halligan S, Taylor SA, Marshall M. Distance between the rectal wall and mesorectal fascia measured by MRI: effect of rectal distension and implications for preoperative prediction of a tumour-free circumferential resection margin. Clin Radiol. 2006; 61(1):65-70.
37. Beets-Tan RG, Lambregts DM, Maas M, Bipat S, Barbaro B, Caseiro-Alves F, et al. Magnetic resonance imaging for the clinical management of rectal cancer patients: recommendations from the 2012 European Society of Gastrointestinal and Abdominal Radiology (ESGAR) consensus meeting. Eur Radiol. 2013;23(9): 2522-31. doi: 10.1007/s00330-013-2864-4. Epub 2013 Jun 7.
38. Arya S, Das D, Engineer R, Saklani A. Imaging in rectal cancer with emphasis on local staging with MRI. Indian J Radiol Imaging. 2015;25(2):148-61. doi: 10.4103/0971-3026.155865.
39. Beets-Tan RG, Beets GL, Vliegen RF, Kessels AG, Van Boven H, De Bruine A, et al. Accuracy of magnetic resonance imaging in prediction of tumour-free resection margin in rectal cancer surgery. Lancet. 2001;357(9255):497-504.
40. Wietek BM, Kratt T. Current MRI staging of rectal cancer. Rofo. 2012;184(11):992-1001. doi: 10.1055/s-0032-1313051. Epub 2012 Aug 14. German
41. Klessen C, Rogalla P, Taupitz M. Local staging of rectal cancer: the current role of MRI. Eur Radiol. 2007 Feb;17(2): 379-89. Epub 2006 Sep 29.
42. Taylor FG, Quirke P, Heald RJ, Moran B, Blomqvist L, Swift I, et al. Preoperative high-resolution magnetic resonance imaging can identify good prognosis stage I, II, and III rectal cancer best managed by surgery alone: a prospective, multi-center, European study. Ann Surg. 2011;253(4):711-9. doi: 10.1097/SLA.0b013e31820b8d52.
43. Smith N, Brown G. Preoperative staging of rectal cancer. Acta Oncol. 2008;47(1):20-31.

44. Quirke P, Durdey P, Dixon MF, Williams NS. Local recurrence of rectal adenocarcinoma due to inadequate surgical resection. Histopathological study of lateral tumor spread and surgical excision. *Lancet*. 1986;2(8514):996-9.
45. Schäfer AO. Local imaging of rectal cancer--update 2015: MRI as imaging biomarker. *Radiologe*. 2015 Nov;55(11):1015-26; quiz 1027-8. doi: 10.1007/s00117-015-0030-5. German
46. Blomqvist L, Glimelius B. The 'good', the 'bad', and the 'ugly' rectal cancers. *Acta Oncol*. 2008;47(1):5-8.
47. Taylor FG, Swift RI, Blomqvist L, Brown G. A systematic approach to the interpretation of preoperative staging MRI for rectal cancer. *AJR Am J Roentgenol*. 2008;191(6):1827-35. doi: 10.2214/AJR.08.1004.
48. Nagtegaal ID, van de Velde CJ, Marijnen CA, van Krieken JH, Quirke P; Dutch Colorectal Cancer Group; Pathology Review Committee. Low rectal cancer: a call for a change of approach in abdominoperineal resection. *J Clin Oncol*. 2005;23(36):9257-64.
49. Nougaret S, Reinhold C, Mikhael HW, Rouanet P, Bibeau F, Brown G. The use of MR imaging in treatment planning for patients with rectal carcinoma: have you checked the "DISTANCE"? *Radiology*. 2013;268(2):330-44. doi: 10.1148/radiol.13121361.
50. Chamlou R, Parc Y, Simon T, Bennis M, Dehni N, Parc R, et al. Long-term results of intersphincteric resection for low rectal cancer. *Ann Surg*. 2007;246(6):916-21; discussion 921-2.
51. Gerard JP, Chapet O, Nemoz C, Hartweg J, Romestaing P, Coquard R, et al. Improved sphincter preservation in low rectal cancer with high-dose preoperative radiotherapy: the Lyon R96-02 randomized trial. *J Clin Oncol*. 2004;22(12):2404-9.
52. Kao PS, Chang SC, Wang LW, Lee RC, Liang WY, Lin TC, et al. The impact of preoperative chemoradiotherapy on advanced low rectal cancer. *J Surg Oncol*. 2010;102(7):771-7. doi: 10.1002/jso.21711.
53. Weiser MR, Quah HM, Shia J, Guillem JG, Paty PB, Temple LK, et al. Sphincter preservation in low rectal cancer is facilitated by preoperative chemoradiation and intersphincteric dissection. *Ann Surg*. 2009;249(2):236-42. doi: 10.1097/SLA.0b013e318195e17c.
54. Rouanet P, Saint-Aubert B, Lemanski C, Senesse P, Gourgou S, Quenet F, et al. Restorative and nonrestorative surgery for low rectal cancer after high-dose radiation: long-term oncologic and functional results. *Dis Colon Rectum*. 2002;45(3):305-13; discussion 313-5.
55. Shihab OC, How P, West N, George C, Patel U, Quirke P, et al. Can a novel MRI staging system for low rectal cancer aid surgical planning? *Dis Colon Rectum*. 2011;54(10):1260-4. doi: 10.1097/DCR.0b013e31822abd78.
56. Shihab OC, Moran BJ, Heald RJ, Quirke P, Brown G. MRI staging of low rectal cancer. *Eur Radiol* 2009;19(3):643-650.
57. Holm T, Ljung A, Häggmark T, Jurell G, Lagergren J. Extended abdominoperineal resection with gluteus maximus flap reconstruction of the pelvic floor for rectal cancer. *Br J Surg*. 2007;94(2):232-8.
58. Albarello F, Lambregts DMJ, Lahaye MJ, Bakers FCH, Martens MH, Heijnen LA, et al. Addition of diffusion-weighted imaging for the clinical MR assessment of rectal cancer: effect on staging and interpretation time, Congress: ESGAR 2014, e-Poster: SE-029.
59. Brown G, How P. Magnetic resonance imaging staging of rectal cancer. In: Brendan Moran, R.J. Heald eds, *Manual of Total Mesorectal Excision*. 2013. p. 59-61.
60. Brown G, Richards CJ, Bourne MW, Newcombe RG, Radcliffe AG, Dallimore NS, et al. Morphologic predictors of lymph node status in rectal cancer with use of high-spatial-resolution MR imaging with histopathologic comparison. *Radiology*. 2003;227(2):371-7.
61. MERCURY Study Group, Shihab OC, Taylor F, Bees N, Blake H, Jeyadevan N, Bleehe R, et al. Relevance of magnetic resonance imaging-detected pelvic sidewall lymph node involvement in rectal cancer. *Br J Surg*. 2011;98(12):1798-804. doi: 10.1002/bjs.7662. Epub 2011 Sep 16.
62. Kim JH, Beets GL, Kim MJ, Kessels AG, Beets-Tan RG. High-resolution MR imaging for nodal staging in rectal cancer: are there any criteria in addition to the size? *Eur J Radiol* 2004; 52(1):78-83.
63. Koh DM, George C, Temple L, Collins DJ, Toomey P, Raja A, et al. Diagnostic accuracy of nodal enhancement pattern of rectal cancer at MRI enhanced with ultrasmall superparamagnetic iron oxide: findings in pathologically matched mesorectal lymph nodes. *AJR Am J Roentgenol*. 2010;194(6):W505-13. doi: 10.2214/AJR.08.1819.
64. Heald RJ. *Manual of Total Mesorectal Excision*. CRC Press, Taylor & Francis Group; 2013.