

General Report

Chirurgia (2016) 111: 102-114
No. 2, March - April
Copyright© Celsius

Oesophageal Foreign Bodies - from Diagnostic Challenge to Therapeutic Dilemma

Dragoș Predescu¹, Irina Predescu², Codruț Sarafoleanu², Silviu Constantinoiu¹

¹Esophageal and General Surgery Clinic, St. Mary Hospital, Carol Davila University of Medicine and Pharmacy Bucharest, Romania

²ENT Department, St. Mary Hospital, Carol Davila University of Medicine and Pharmacy Bucharest, Romania

Rezumat

Corpii străini esofagieni - de la provocare diagnostică la dilemă terapeutică

Ingestia de corpi străini, frecvent întâlnită în serviciile de urgență, rămâne o provocare pentru medici în ciuda măsurilor preventive și a progreselor tehnice datorită frecvenței și complicațiilor posibile, complicații grave ce pot întuneca prognosticul vital sau pot fi sursă de morbiditate la distanță. Experiența clinicii "Sf. Maria" raportează în intervalul 2000-2015, 39 de pacienți diagnosticați cu ingestie de FB, din care 26 fixați la nivelul esofagului iar restul de 13 au trecut în aval spontan (5 recuperați din stomac, 6 evacuați natural, 2 cazuri cu perforație colică). Corpri străini esofagieni survin consecutiv ingestiei (in)voluntare, marea lor majoritate trecând neobservați. Cel mai frecvent sunt monezi, baterii, ace, obiecte ascuțite diverse, alimente, eschile osoase, cartilagi, bucați de plastic, sticlă, etc, de obicei blocarea FB la nivelul esofagului fiind condiționată cel mai adesea de cele 3 strâmtoări anatomice. Obișnuit, ingerarea FB survine la vârste extreme, 60% dintre pacienți fiind copii preșcolari (< 6 ani), procentul fiind chiar mai ridicat - între 70-80% la o vârstă între 6 luni și 2 ani - și doar la 15% dintre persoanele în vârstă, frecvent edentați. Semnele clinice uzuale de apel, în absența complicațiilor, sunt: disfagie, hipersialoree, jenă cervicală joasă și/sau toracică, uneori vomismente. Deloc rar (30%!), se remarcă lipsa oricărui semn.

Manifestările de alertă, care indică apariția complicațiilor sunt: stare febrilă, alterarea stării generale, durere (proiecție vertebrală /interscapulară), împăstare, emfizem cervical subcutanat. Diagnosticul imagistic prin variantele sale (Rx simplă, tranzit baritat, CT, RMN) rămâne veriga esențială în identificarea lezională și decizia terapeutică. Evaluarea endoscopică (rigidă sau flexibilă) este obligatorie, permițând și gesturi terapeutice. Evolutiv (80-90%) FB migrează în stomac fiind eliminați pe căi naturale, la cca 10-20% este necesară extracție pe cale endoscopică și doar la 1% din cazuri se impune un gest chirurgical. Tratamentul cazurilor necomplicate este esențial endoscopic fie, de excepție, intervenție chirurgicală pentru extragerea corpului străin. În fața complicațiilor, chirurgia este singura resursă terapeutică credibilă. Corpri străini esofagieni reprezintă o urgență frecventă, cu simptomatologie funcțională caracteristică ce contrastează cu semnele clinice sărace, necesitând ca tratament extracția pe căile naturale în marea majoritate a cazurilor. Cel mai eficace "tratament" rămâne prevenția și informarea părinților cu copii ≤6 ani iar cel mai important element în managementul FB este preservarea căilor aeriene libere.

Cuvinte cheie: corpi străini esofagieni (FB), impactare esofagiană FB, management diagnostic și terapeutic FB

Corresponding author:

Dragoș Predescu, MD
Carol Davila University of Medicine and
Pharmacy, Department of Esophageal and
General Surgery, St. Mary Hospital
Bucharest, Romania
E-mail: drpredescu@yahoo.com

Abstract

Ingestion of foreign bodies, common in the emergency services, remains a challenge for physicians despite preventive measures and technical progress due to the frequency and possible complications, serious complications that can darken vital prognosis or may be a source of remote morbidity. Clinical

experience at "St. Mary" Hospital included, between 2000-2015, 39 patients diagnosed with FB ingestion, of which 26 fixed in the oesophagus, with the remaining 13 having spontaneously progressed along the digestive tract (5 recovered from the stomach, 6 naturally evacuated, and 2 cases with colic perforation). Oesophageal foreign bodies occur consecutively to (in)voluntary ingestion, the vast majority of them passing unnoticed. The most frequently encountered types are coins, batteries, needles, various sharp objects, food, bone fragments, cartilages, pieces of plastic, glass, etc., FB impaction at oesophageal level being usually conditioned by the 3 anatomical narrowings. Typically, FB ingestion occurs at extreme ages, 60% of patients being pre-school children (<6 years), with an even higher percentage - between 70-80% between 6 months and 2 years of age - and only 15% elderly, frequently edentulous. Usual clinical signs, in the absence of complications, are: dysphagia, hypersialorrhoea, low cervical and / or chest strain, sometimes vomiting. Not at all infrequently (30%), we notice the absence of any sign. Alarming manifestations, which indicate the development of complications, are pyrexia, general physical health deterioration, pain (with vertebral / interscapular projection), pulsing, subcutaneous cervical emphysema. Diagnosis via various imaging methods (simple radiography, barium swallow, CT, MRI) remains the essential link in identifying the lesion and establishing a therapeutic approach. Endoscopic evaluation (rigid or flexible) is mandatory, also allowing therapeutic gestures. In terms of progression, 80-90% of FB pass into the stomach, being eliminated naturally, about 10-20% require endoscopic extraction, and only 1% of cases require surgical intervention. Treatment of uncomplicated cases is essentially endoscopic, surgery to extract the foreign body being necessary in exceptional cases. In case of complications, surgery is the only reliable therapeutic resource. Oesophageal foreign bodies frequently represent an emergency, with symptomatic functional features contrasting with the poor clinical signs present, requiring extraction via the natural pathways as treatment in most cases. The most effective "treatment" remains prevention and raising awareness in parents with children ≤ 6 years, while the most important element in the management of FB is to maintain the airways free.

Key words: oesophageal foreign body (FB), FB oesophageal impaction, FB diagnostic and therapeutic management

Introduction

Ingestion of foreign bodies (FB), common in the emergency services, remains a challenge for physicians despite preventive measures and technical progress due to the frequency and possible complications, serious complications that can obscure vital prognosis or can be a source of morbidity at a distance.

Oesophageal foreign bodies occur consecutively to voluntary or involuntary ingestion and, usually, are 5 times more frequent

than those of the airways, mostly going unnoticed. Most frequently - 80-90% - they migrate in the stomach and are eliminated naturally, through faeces, approximately 10-20% require endoscopic extraction, while only 1% of cases require a surgical act (1-3).

Clinical experience at "St. Mary" Hospital included, between 2000-2015, 39 patients diagnosed with FB ingestion, of which 26 fixed in the oesophagus, with the remaining 13 having spontaneously progressed along the digestive tract (5 recovered from the stomach, 6 naturally evacuated, and 2 cases with colic perforation). Impacted oesophageal foreign bodies were most often bone fragments, dentures, various metal objects, and food. All 26 patients were adults, most over 65 years old (21 cases) and without psychiatric history. Of the 26 FBs fixed at oesophageal level, 22 were fixed at the level of the 3 anatomical narrowings: 14 at the mouth of the oesophagus, 3 at the level of the aortic impression, and 5 cases below the cardia. In 4 cases the impaction site was atypical. A number of 11 patients out of the total 26 reported a pre-existing oesophageal pathology. Clinical diagnosis was suggested by the anamnesis and, eventually, by the inability of normal swallowing, occurring recently. Complications involving perforation were rare, 3 at cervical level and 1 mid-thoracic, resulting in abscesses and sepsis resistant to treatment. Standard investigations performed were thoracic-pulmonary radiography, barium swallow, endoscopy in all its variants (rigid, especially during the onset years of the study, ENT fibroscopy, gastrofibroscopy). Presence of complications determined the necessity for CT and MRI imaging to assess lesions. Uncomplicated cases (22 cases) were treated via endoscopic approach, extraction being carried out by rigid oesophagoscopy in 2 cases, and gastrofibroscopy in the remaining ones. In 7 cases, the FBs were pushed into the stomach, where they could be more easily manipulated, possibly triturated (in cases of impacted food), and extracted. The 3 cervical suppurations required a surgical gesture, left lateral cervicotomy, the FBs being identified and extracted by direct approach in 2 cases, and via endoscopic approach in the third case. Wound toilet and effective drainage, abstention from oral feeding and ensuring feeding through an underlying approach (gastrostomy) led to resolution of the cases. Medio-thoracic oesophageal perforation was approached by right thoracotomy, with FB extraction, parietal suture and lining with mediastinal pleura, lavage and multiple drainage. Progression was slowly favourable. We did not use prosthetic stents for oesophageal perforation due to FBs.

Food habits determine different types of ingested FB, as well as the patient's age. (Table 1) The most common are coins, batteries, needles, various sharp objects, food, bone, cartilage, pieces of plastic, glass, alloys, etc. In terms of age (4), FB ingestion occurs most frequently in extreme ages, 60% of patients being pre-school children less than 6 years old (5-9), the percentage becoming even higher - between 70-80% for ages 6 months to 2 years old - conditioned especially by children's tendency to mouth objects, and only 15% of the elderly, most often edentulous (10-14). In the latter case, one must differentiate between retention of a partially masticated food and the impaction of a foreign body that is not food. Also,

Table 1. Foreign body and oesophageal impaction – aetiology and risk factors for ingestion

Childhood – peak between 6 months to 6 years
Impaired vision
Neuro-psychiatric disorders (dementia, drug-induced, etc.)
Edentulous
Prisoners
Drug dealers
Pathology of oesophagus
- Narrowing – rings, strictures (caustic, peptic, anastomotic, post-oesophageal surgery, post-radiation, etc.)
- Others – eosinophilic oesophagitis, oesophageal motility disorders, etc.
Caustic pills
Large foreign body

ingesting can be secondary to a voluntary or accidental mechanism; if in the first case the patient's profile is that of an instable person, with psychiatric disabilities, or in prison, in the second case it is an occasional, isolated, ingestion type incident specific to any age. In 97% of ingestion cases there is a single FB but, in exceptional circumstances of voluntary ingestion or in psychiatric patients, there may be several.

Usually, the oesophagus may be involved in its upper 1/3 as well as in the lower 2/3 (3), FB blockage at the level of the oesophagus is most often conditioned by the 3 anatomical narrowings: a superior one at the mouth of the oesophagus (68%), a middle one at the level of the aortic impression (13%), and an inferior one at the cardia (18%). In case of impaction at the mouth of the oesophagus (Killian), it is mandatory to seek a pre-existing distal oesophageal pathology, usually conditions resulting in an organic or functional stenosis of the oesophagus (6-9, 15-19). External compression causes leading to impaction are most often congenital, such as left atrium dilation, a dilated aortic arch, *dysphagia lusoria*, etc. ... (20-22) and, more rarely, mediastinal tumours. An atypical site of impaction is suggestive of intrinsic oesophageal diseases, acquired, that may cause or facilitate impaction by altering lumen dimensions or by dysfunctions in oesophageal peristalsis: diverticula (23), various types of oesophagitis (e.g. eosinophilic type), different types of luminal stenosis, peptic (e.g. Schatzki ring), caustic or even neoplastic (10-13,7-9,18,19). A special class at high risk of impaction are former patients (24), children and adults, who have a history of oesophageal surgery, with the further development of pathologies such as secondary motor disorders of the oesophagus or peptic / alkaline stenosis through an iatrogenically induced or postradiation GERD, iatrogenic atresia, etc.

Common clinical signs, in the absence of complications (3, 25) are: dysphagia, hypersialorrhoea, low cervical and / or chest strain, and sometimes vomiting in cases with large, obstructive objects. Not infrequently, in about 30% (!) of patients, the lack of any sign is noted. The symptomatic area or region are not synonymic with the site of impaction. The presence of dyspnoea - type respiratory phenomena, accompanied by stridor, can be revealing for the ingestion of a foreign body, most often impacted at the mouth of the oesophagus, but retention of a foreign body can just as well mimic signs of a respiratory infection or croup (26,27). Alarming manifestations, indicating

the occurrence of complications, are: pyrexia, general physical health deterioration, pain (vertebral and interscapular projection), pulping, subcutaneous cervical emphysema. Obstruction is the most common immediate complication, being relatively well-tolerated in adults, but in children, subsequent to lumen occlusion, a state of dehydration may occur (for bulky foreign bodies causing total dysphagia). Suction-type phenomena are a consequence of luminal obstruction (21), having inadequate management of oesophageal-pharyngeal swallowing as an aetiological substrate, with a defective downward passage and accumulation of the digestive contents above the obstacle. Given that in the general population aspiration phenomena are insignificant or, in any case, generate only minor symptoms, their sudden occurrence without any serious history mainly suggests foreign body retention. For the practitioner, food aspiration can therefore be a signal of a foreign body impaction, especially located in the proximal segment of the oesophagus. Parietal perforation is extremely rare as an immediate consequence, usually occurring several days after ingestion. Septic phenomena with general health deterioration suggest a complication (28). Oesophageal strictures, oesophageal-tracheal fistula and oesophageal-bronchial fistula can occur remotely (29). Rarely, massive hematemesis due to aortic-oesophageal fistulas with fatal bleeding can occur (30-32).

In children, symptoms are more atypical (21,24,27), presenting hypersialorrhoea, vomiting, dysphagia. One should also be put on guard by respiratory signs that manifest with fits of coughing, dyspnoea, wheezing, their frequency increasing with the duration of FB persistence.

ENT clinical examination must be precise, by direct inspection, exploring the tonsil lodges, of the base of the tongue, the valleculas looking for FBs or mucosal wounds, with a mandatory association of fibroscopic examination of the larynx / pharynx and piriform sinuses. Nasal and auricular evaluation for detection of additional FB is standard. Examining the quality of the respiratory act and of the sounds emitted during inhale / exhale manoeuvres is of paramount importance, some FB oscillating at the level of the aero-digestive crossroads, intermittently blocking a lumen or another, or in the presence of an increased number of FB, some can be aspirated and others swallowed. In such situations, the risk of respiratory obstruction with acute respiratory failure is significant, and failure to recognize the lesion can lead to the death of the patient. Pain at mobilization of the laryngeal skeleton and cervical level crepitations should also be identified. Lung auscultation must be performed, as well as palpation of the abdomen and temperature measurement.

The multiplicity and variety of possible toxicity in terms of quality and properties of the material, of size and shape of the FB ingested, explain the diverse and polymorph lesion picture, rendered specific by way of the physico-chemical properties of the FB. The maximum size that makes the passage possible is up to 2.5 cm. Above this size limit there is a risk of impaction, most likely not in the oesophagus, but at pyloric level (6, 33 - 35). If the FB "passes" the pyloric barrier, crossing through the entero-colonic lumen is slow, sometimes up to 4 weeks (15) !. The risk of impaction anywhere on this route exists, but the election area

is the ileocecal valve. During this period, radiological follow-up is mandatory, and persistence for more than a week in a fixed position requires surgical intervention (36).

In case of FBs larger than 2.5 cm, especially compact, and relatively uniform, oesophageal retention occurs as a rule, and transcordial passage is the exception. If, however, passage to the stomach occurs, they become fixed at this level, with specific complications. On the other hand, elongated foreign bodies, longer than 6 cm, cross the oesophagus and cardia relatively easy, sometimes even the pylorus, blocking most often the duodenal curvatures, with significant risk of perforation (37).

A series of events, usually systemic, are assigned to toxic compounds in the ingested foreign bodies. Zinc, nickel or copper intoxication has been reported sporadically (38-40) in cases of ingestion of coins or galvanically treated FB. Circular batteries ("button") contain mercury oxide, and in the presence of an altered capsule, possibly through mastication, can release inorganic mercury in the lumen. Apart from transient increases in the level of mercury in the blood or urine no specific symptoms of mercury poisoning have been reported (41-44).

Histopathological lesions (45-48) caused by a blunt foreign body, without sharp edges or ends, initially induce more or less severe ischemia through direct compression of the mucosa, dependent on the size of the FB, followed by a phase of congestion of the perilesional mucosa, followed in 1-2 days by oedema. Persistence of the compression by failure to extract the FB will lead to dilacerations by ischemo-necrosis of the parietal stratigraphy, with the advent of bleeding ulcers and secondary superinfection by local microbial spread. Progression can be towards oesophageal perforation and, depending on the level of impaction, periesophageal phlegmon \pm suppurative mediastinitis; fistulisation in the tracheobronchial or aortic tree is exceptionally rare (30-32). Sharp foreign bodies are reputed for sharp punching wounds. There are multiple versions, with some regional profiles. Thus, in the United States (6) the most common injuries reported are those due to toothpicks and dodge bones, in Asia (Korea, Japan) due to fish bones, and in Romania the causes can be found somewhere in between all of the above. Ingestion of glass fragments frequently determines perforation wounds, especially in cases of voluntary ingestion, consequence of a substantial size of the pieces swallowed. An interesting fact is that ingestion of shaving blades (49) can result in them crossing the lower digestive tract without difficulty, once past the pyloric-duodenal barrier. Also interesting is the case of pins, often swallowed by tailors and which, thanks to peristaltic activity as well, position themselves with the pin head forward, often relieving the patient of perforated injuries.

A particular situation (41) is given by circular type "button" batteries. Their small size, weight and modest adherent ability explain on the one hand their property to adhere anywhere along the oesophagus and, on the other hand, the rapid emergence of necrotic parietal lesions followed by perforation within hours of ingestion (!) as a result of electrical discharge due to contact between both poles of the battery with the wall of the collapsed oesophagus. This is why urgent recognition of the type of FB present is required, followed by its extraction, and subsequent radiological follow-ups.

Diagnostic imaging through its variants (simple X-ray, Barium X-ray, CT, MRI) remains an essential link in identifying the lesion and establishing the therapeutic approach.

Chest radiographic examination (front, profile and oblique incidence) is of utmost importance to confirm the diagnosis (15,50), allowing easy identification of radiopaque FB in terms of location, size, shape, number and differential diagnosis with FB aspirated in the tracheobronchial tree. Lateral and oblique incidence are mandatory (15,51,52), as they distinguish between oesophageal and tracheal location (on the profile X-ray an oesophageal FB is projected behind the trachea and in front of the vertebrae), enabling discovery of multiple bodies (53) overlapping on a frontal incidence X-ray, therefore providing information which is vital in establishing the therapeutic method, and also presents high accuracy in identifying the foreign body type. Association with an abdominal X-ray and a cervical one when in doubt between inhalation and ingestion is again mandatory. For example (Fig. 1), on a chest X-ray if a coin is round in frontal incidence and linear in the profile incidence it is positioned in the oesophagus, while if it is the other way around it is engaged in the trachea, being oriented thusly because of the vocal cords (54,55). Standard radiography, with its variants, is an essential element in detecting "button" type batteries, known for the risks and complications determined at oesophageal level (previously mentioned), being a quick and reliable method, with an extremely high diagnostic index (56).

In the case of bodies with reduced opacity, a useful method

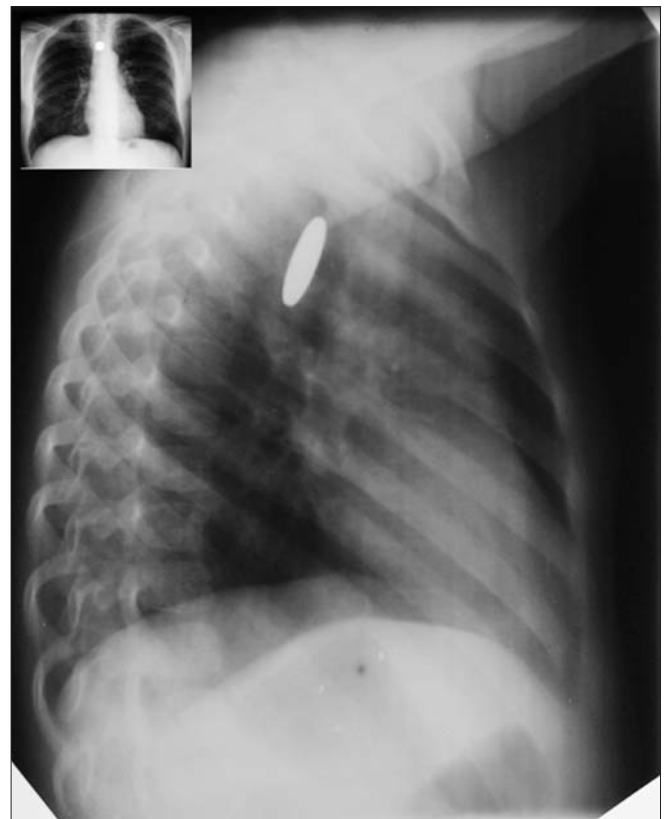


Figure 1. Chest X-ray - anterior and lateral view - showing coin in oesophagus, upper $\frac{1}{3}$ thoracic

would be low voltage radiology (65-70 kVp), allowing increased contrast between them and neighbouring tissues. The limits of standard radiology in diagnosing radiolucent bodies are evident, their failure to appear on X-ray films forcing the physician to resort to the radiological low voltage method (modest diagnostic rate) or to oesophageal contrast-swallowing studies (57,58).

A significant role of simple radiology is that in screening of complications, usually punctured and subsequently septic. In the proximal portion, thickening of the soft cervical-mediastinal tissues, presence of a gas effusion or prevertebral emphysema are characteristic signs (59) of perforation, in the same way that in the chest region, identification of pneumomediastinum, pneumothorax, hydrothorax or hydro-pneumothorax are obvious signs for oesophageal parietal intrusion. It is essential to mention whether there is any mediastinal involvement - mediastinitis, with or without any spread, any possible mediastinal abscess formation, etc (60, 61). The role of standard radiology in follow-up and subsequent screening after extraction should not be neglected.

Barium swallow is a complement method to standard diagnostic radiology (20) and, although there are opponents of the method due to the risk of aspiration (15,16), as well as a number of false negative results (36,37) and interferences with endoscopy (62-64), its value is undoubted. If we also take into account the existence of cases with formal contraindication for endoscopy, we must consider the method as being an essential one. We have used it sparingly and our expectations were rewarded, but on one condition: strict observance of the rules and conditionality of the method. Barium administration should be performed in a thin layer, sequentially following its progression, (Fig. 2) otherwise there is a non-diagnosis risk by "drowning" the FB in the barium column (36). Any suspicion of a possible oesophageal perforation contraindicates the use of barium (65,66) due to granulomatous reaction secondary to its penetration into the mediastinum. Another unpleasant effect is that of tampering exploration results in subsequent imaging (e.g. CT). Under these circumstances the use of contrast substances soluble in water (67-69) (e.g. Gastrografin) is recommended whenever we suspect a parietal effraction, even though the diagnostic rate is low (70) - 15-25% failure rate for thoracic fistulae and approximately 50% for cervical ones!. In exceptional situations, such as identifying the site of impaction of a small dodge bone, with reduced radiological contrast, we used barium paste fixed in a ball of cotton, which was "hanged" and blocked in the oesophagus at the site of FB retention. (Fig. 3)

The special diagnostic sensitivity of CT exam in the detection of oesophageal FB makes this method a great one, especially for the cranial portion of the oesophagus (57,58), even if failure rates are reported for radiolucent bodies (15). In other words, the detection rate of FBs is directly proportional to their opacity. To this one can add the importance of the retention site and of the proximity of bony structures that can alter the result. Beyond its efficacy in detecting FBs and their characteristics strictly dependent on their physicochemical radio-behaviour, CT allows a three-dimensional evaluation of the oesophagus' relations with adjacent structures and the impact determined by

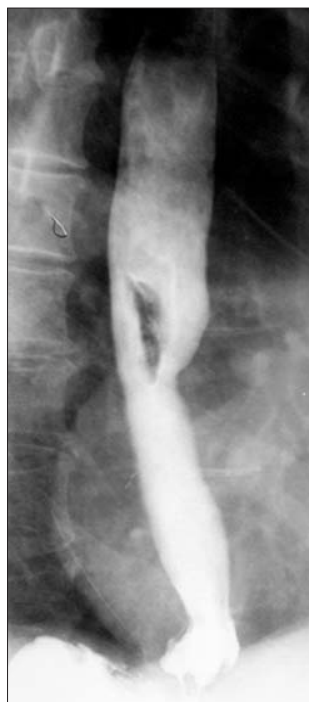

Figure 2. Barium swallow showing removable partial dentures impacted in the medium oesophagus

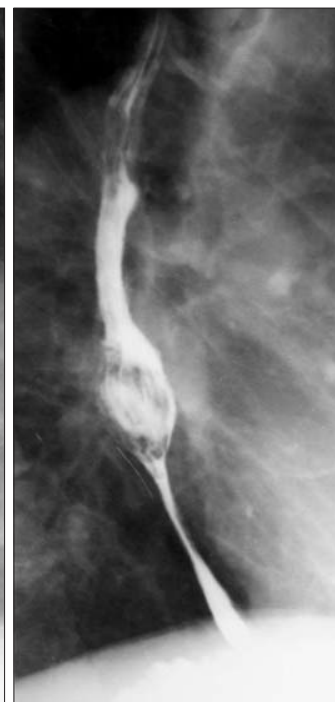


Figure 3. Barium swallow - cotton ball with barium fixed at impacted bone in medium oesophagus

perforation-fistular complications. Common type CT (71) has the disadvantage of a moderate resolution, detecting objects larger than one centimetre, and a relatively high rate of artefacts due to respiratory movements, a consequence of the prolonged time necessary to perform the investigation. The technical development of tomographic equipment allowed the development of spiral CT, which has a higher working speed and superior quality imaging (72,73). For example, a scan of the entire thorax in ranges 1.25 mm apart can be achieved in about 19 seconds, in a single period of apnoea, the result not being influenced in any way by respiratory movements. If a 3D computer-generated reconstruction of the oesophagus is also performed, under these conditions, CT sensitivity is reported as 100%, with a specificity of 92.6%, a positive predictive value rate of 97.9% and a negative one of 100% (72, 74 - 76). Administration of an IV contrast medium has no direct diagnostic role in terms of the object ingested, but it is absolutely necessary in order to identify complications of perforation. *Per oral* contrast substances do not present an obvious diagnostic benefit compared to a barium lunch. A variant of CT exam, in addition to the use of an orally administered contrast medium with low osmolality, is the use of effervescent granules (77), greatly increasing the rate of identification of perforation wounds.

A customized version for use in pregnant women or children is low dose CT, for foreign bodies with low contrast (51,78-81).

Beyond identifying FB, CT is of paramount importance (77,82,83) in the evaluation of the mediastinum, its involvement through oesophageal perforation having diagnostic

value by detecting an inflammatory status, extraluminal air, peri-oesophageal liquid or contrast substance, various instances of parietal thickening, etc....

CT is recommended to be carried out as early as possible (73, 75), within the first 24 hours, whenever there is suspicion or diagnostic confirmation by other methods of ingestion of FB.

MRI evaluation is an exception, its role being still subject to discussion (21,84,85). If we take into account the limitations concerning metal bodies, the long manoeuvre time with the induction of artefacts, the possibly necessary sedation of patients and the costs, it becomes obvious why MRI maintains a restricted indication, most often in situations in which the diagnosis remains uncertain after investigation through other evaluation techniques, being useful in evaluating complications, especially perforations, and possible secondary collections. (Fig. 4)

Alternative methods, used exceptionally, are ultrasound and metal detectors. Soft tissue ultrasound is recommended especially for the diagnosis of inflammation in oesophageal perforation, and abdominal ultrasound can detect FBs that migrated and were fixed in the stomach (86). Manual metal detectors are required due to several advantages, rendering the method increasingly efficient in the diagnosis and accurate identification of the impaction site (87,88): the device is cheap, the method fast and easily reproducible, non-invasive (no ionizing radiation), malleable due to the smaller size of the detector, it can be used anywhere, requires no difficult training, and is easily endured by patient. Optimum results are obtained from the detection of metal objects reasonably large of course, with a sensitivity and specificity rate exceeding 90%. Beyond diagnosis, the essential purpose of metal detectors remains to

specify the site of impaction, above the diaphragm (oesophageal) or subdiaphragmatic respectively (migrated in the stomach or small bowel). For a proper evaluation a few rules to follow are mandatory: the patient is stripped, placed away from any neighbouring sources of metal and removing those owned by the patient (buttons, chains, rings, earrings, etc.), the scan is performed slowly, progressively, starting at cervical level and then descending over the chest, abdomen, perineum, from the front, side and in the end the back, passing the device several times over the patient's body (87,89). Correlation with other diagnostic methods is mandatory.

Endoscopic assessment

Endoscopic examination recognizes two diagnostic, and often therapeutic, assistance techniques: rigid and flexible oesophagoscopy. In terms of equipment used the following are described:

- Rigid endoscopy:
 - Haslinger or Chevalier "light endoscope";
 - Hopkins (Storz or Wolf) oesophoscope with cold light.
- fibro-endoscopy:
 - ENT type fibro-endoscope;
 - gastrofibroscope and videoendoscope.

Since its introduction in medical practice (Kussmaul 1870; Mikulicz 1881), the method of rigid oesophagoscopy has been used in dual manner: diagnostic and therapeutic. The technique retains its authenticity and allows great diagnostic success under the following conditions: good knowledge of the endoscopic method by the performing doctor (both flexible and rigid), thorough examination, knowledge of oesophageal anatomy and morphological pathology. The performer should be able to view the initial imagistic data and be alarmed if the circumstances requires a delicate investigation: various initial pathologies of the oesophagus, perforation wounds or other complications with acute character, erosive esophagitis, etc. ... Typically, the failure of the method is associated to an incomplete investigation, on average between 0.8 - 2% of the cases (90). The most redoubtable complication of the investigation is oesophageal perforation, a reason for which Jackson's aphorism (90) (1934, 1950) is perfectly justified even today: "seek the oesophageal lumen and follow it." The introduction of halogen "cold" light lightbulbs, of the angled optics system (Hopkins), of air insufflation, has limited the risk of iatrogenic perforation so that this type of complication occurs in a proportion similar to that of flexible endoscopy. However, rigid oesophagoscopy is increasingly less used (20,91,92), being indicated in certain cases only, such as neoplastic cases and especially foreign bodies. Rigidity of the instrument makes it difficult to use in patients with spondylosis or various types of cervical ankyloses. In compensation, this tool allows a precise, effective exploration of the oro- and hypopharynx, of the larynx, pharyngeal, of the pharyngeal-oesophageal junction, and of the upper oesophagus. This information is difficult to obtain by exploration with the flexible endoscope. One of the drawbacks of the technique is the need for a training period that the performing physician must go

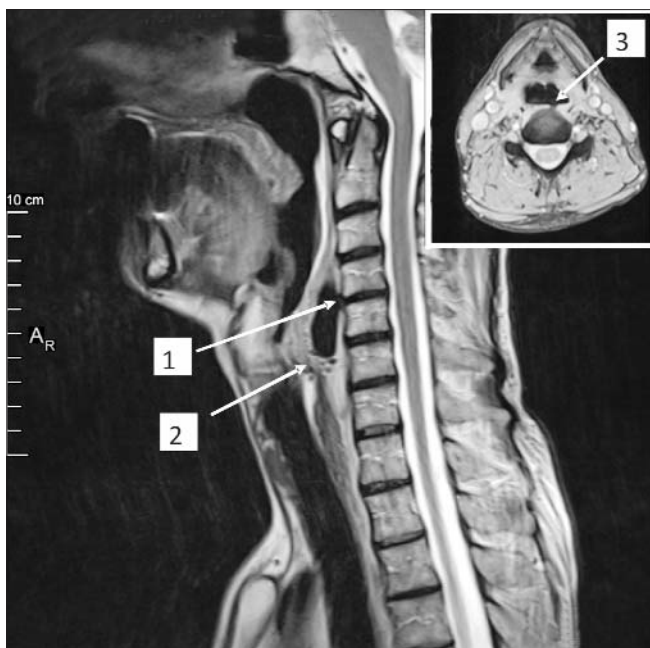


Figure 4. MRI sagittal view – 1. Posterior oesophageal perforation with vertebral body penetration. 2. Retropharyngeal abscess with gas bubbles. In cartouche, MRI transversal view. 3. Oesophageal perforation and bone penetration

through. Secondly, another drawback is the need for IOT general anaesthesia, the medical staff mandatorily having to include an anaesthesiologist. In general, the rigid oesophagoscopy technique is more difficult than the flexible one, requiring the allocation of an operating room and qualified staff, including someone to help mobilize the patient according to the needs of the explorer. On the other hand, it allows the use of an extremely diverse set of tools that facilitate extraction (endoscopes in various diameters and sizes, with appropriate accessories), and associated with a laryngoscope and bronchoscope it allows one to perform a pan-endoscopy of the upper aero-digestive pathway. The emergence of flexible endoscopes virtually caused a monopolization of the method. Two different endoscopic explorations both in terms of equipment and method of use are known: ENT fibroendoscope and classic gastrofibroscope. The ENT endoscope has the advantage of a small diameter, which makes it easily endurable to the patient and leads to some extremely useful information about the aero-digestive junction area, difficult or impossible to obtain when using the gastrofibroscope, however, below the area of the aero-digestive crossroads the exploration becomes virtually impossible. As a corollary of ENT mini-endoscopic examination, a concurrent specialized consult holds a crucial role (+ indirect laryngoscopy). Inspection of the oesophagus with the flexible gastrofibroscope allowed, in addition to barium swallow, a diagnostic index increase, regardless of oesophageal pathology, of almost 100% different pathologies that have similar semiotics being usually excluded by contrast radiology. For this reason, as well as for preliminary information on the oesophageal status, both fibrogastroscopy and, more recently, videoendoscopy are recommended to be performed after contrast radiology.

For fibroscopy, blind positioning of the instrument at upper level is generally easy, in case of cooperating patients, with no lesional involvement of the aero-digestive crossroads, of the hypo-pharynx or the upper oesophagus, but there is a risk of mobilizing FBs located in a supraglottic position in the oesophagus or, more seriously, in the larynx, with acute obstruction of the airways. Therefore, whenever a foreign body is suspected, the introduction of the endoscope must be performed "in sight". Whenever there is an abnormal resistance when attempting to perform an endoscopy, it is preferable to use a different technique, or even anaesthesia. Another consequence of endoscopic exploration is triggering vagal reflexes. This is why, in cardio-vascular patients or for lengthy explorations, continuous coronary monitoring is required during the investigation. In preparation for endoscopy, regardless of method, one must meet several conditions: thorough clinical examination (oral cavity-teething, functionality of the jaw joint, neck - asymmetry, lymph nodes, hypertrophy of the thyroid; spinal column - functionality, mobility, especially at cervical level), initial barium swallow, empty stomach, possibly premedication. The main prerequisite is a cooperative patient, balanced, otherwise requiring general anaesthesia. The use of general anaesthesia is required in patients with lesions of the airway.

Endoscopic examination, rigid or flexible, presents high diagnostic rates (90, 93-95), and may reveal foreign bodies in between 87-98% of cases via the first method, with a rate of perforation

less than 3%, while in case of the latter, the diagnostic index is between 80 - 98.5%, with a risk of perforation below 1%. In the hands of an experienced endoscopist the exploration allows, aside from obtaining diagnostic information, the possibility of performing a therapeutic gesture, under one condition - handling the endoscope with great finesse and patience. (Fig. 5, 6)

The differential diagnosis (96) must be made with other causes of dysphagia: various types of oesophageal stenosis, oesophageal spasms, tracheal stenosis, pharyngeal paraesthesia, or oesophageal diverticulitis, etc. Similar to many pathological entities, FBs also comply with the following corollary: the earlier the diagnosis is set, the smaller the risk of complications, and consequently the better the therapy results.

If airway obstruction is not present or is only partial, the Heimlich manoeuvre at the scene may precipitate impaction and blocking of the airways, so the patient should be transported to

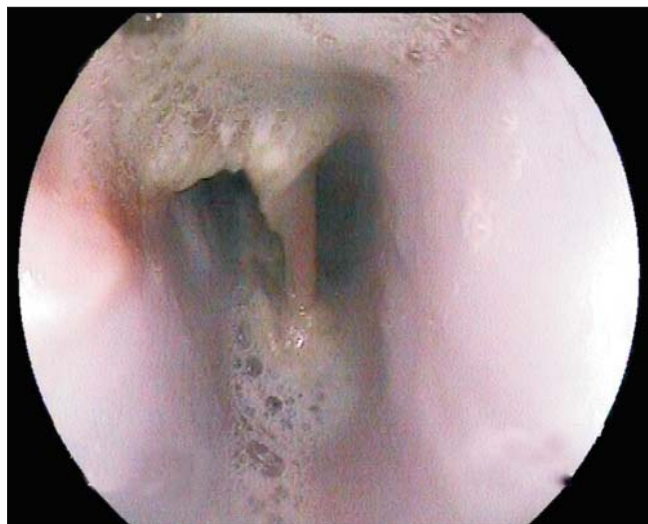

Figure 5. Endoscopy aspect – chicken bone impacted in medium oesophagus

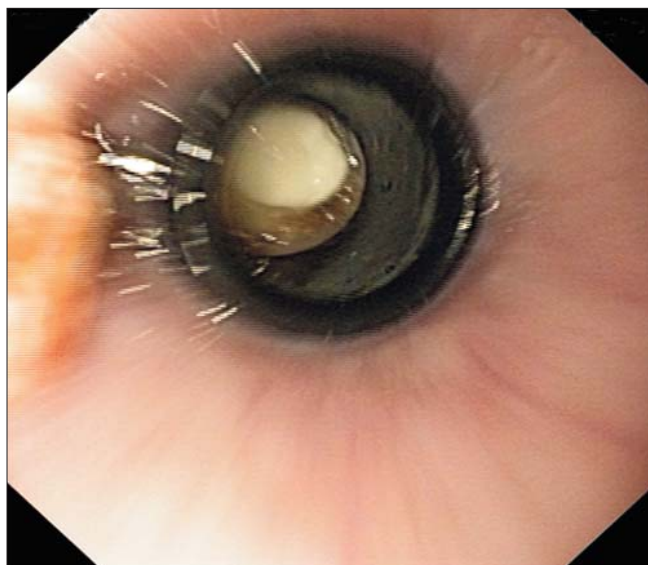


Figure 6. FB fixed in the oesophagus – endoscopy

the hospital as soon as possible so that the extraction can be performed. An attempt to perform blind exploration of the hypopharynx by use of a finger is also not desirable, frequently pushing the foreign body into the larynx or the oesophagus. Patient transport must be performed with him/her in supine position, ensuring a patent airway, with visual inspection of the oropharynx to detect the FB, sometimes a suction probe proving helpful in patients with sialorrhoea. The diagnosis is usually possible to establish from the patient's account, but in many cases it is necessary to interrogate the entourage as well. Treatment of oesophageal FBs starts with their recognition. Once arrived in the ER, the emergency doctor has four essential tasks to accomplish: clinical evaluation that essentially includes immediate and rapid evaluation of airway patency, eventual removal of accessible FBs, radiological / endoscopic investigation to identify them, medical management. Subsequently, the therapeutic task is undertaken by the endoscopist, ENT specialist or surgeon, depending on the circumstances: FB extraction via endoscopy, diagnosis and monitoring of complications, management of complications, usually surgical or endoscopic.

The signs of airway obstruction (stridor, wheezing, breathlessness) due to ingested foreign bodies sounds the alarm for a possible asphyxiation, which is why orotracheal intubation may be a solution, or a gesture of absolute necessity. The presence of a hypersialorrhoea with inability to swallow may also force intubation to prevent aspiration pneumonia. Even in case of an endoscopic extraction of the FB, intubation can relieve the risk of airway obstruction during the manoeuvre.

During the clinical examination, identification and removal of "handy" FB is mandatory, especially since one can face multiple ingestion situations.

Medication management is valuable and may be an important therapeutic weapon. Vomiting inducing methods with Ipecac or Papain are dangerous and ineffective (97). Instead, the administration of glucagon (i.v. Glucagon 1 mg), known for its myorelaxing effect on the oesophageal muscles and especially on the lower sphincter, would be beneficial in about 2/3 of cases by dislocation and propulsion of the FB into the stomach. Associating benzodiazepines or effervescent mixtures or water would significantly increase the success rate or will obviously ease the burden of the performing endoscopist (98-101), but on one condition: soft foreign body, with a reasonable size. Criticism regarding Glucagon administration includes side effects such as nausea / vomiting, hypokalaemia, hypoglycaemia and increased catecholamines (! in cardiac patients), with an at least questionable efficiency (98, 102-106).

Oesophageal foreign body treatment is polymorphic, but the endoscopic gesture is the most renowned, on the one hand due to the availability of the method, and on the other to the high efficiency of the technique in solving the pathology. An advantage not to be omitted of endoscopy is also that of parietal injury evaluation at oesophageal level. In case of ingestion (20), the medical attitude must take into account the time elapsed from the impaction of the FB, its contour and shape, its constituent material, the anatomical site of impaction, the endoscopist's experience, and last but not least the technical platform.

The moment of attempting endoscopic solving of the obstruction depends on the type of object, the site of impaction and the degree of obstruction. Endoscopy is recommended (20) to be carried out immediately in patients with ingestion of sharp FB (needles, bones- especially fish, glass, nails or objects > 6cm length, etc.), or of "button" type batteries with increased risk of perforation, or in those with total obstruction (size > 2.5 cm thick) due to possible aspirations. Generally, any foreign body impacted in the oesophagus has indication for endoscopic extraction within 24h after ingestion, taking into account the possibility of abrasion, ulceration, fistulisation if extending beyond this chronological limit. If the FB dimensions are reduced and the patient is stable, without any complaints, some authors (7,110) consider that emergency endoscopy is not required based on the argument that the passage will take place spontaneously in about 4-6 days. Conservative attitude (7-9, 108), however, requires a slight diet, control of faeces to check evacuation and a clinical assessment regarding the development of any symptoms. Compact objects, relatively uniform, are evacuated in about 4 weeks and require weekly radiological monitoring to assess progression (8).

Some endoscopic management principles are mandatory. The therapeutic act should be carried out in the operating room, usually under sedation with local pharyngeal anaesthesia or, more recommended, under general anaesthesia iv and under intubation even, having statistically a success rate of > 90% and complications < 5% (20, 109, 110). The higher the impaction site, the more urgently is IOT anaesthesia required. An available laryngoscope / bronchoscope for assistance or necessity is also a mandatory condition. Inspection of the crico-pharyngeal region must be rigorous to identify any other eventual FB that can be aspirated via the tracheal-bronchial tree. Extraction can be achieved by laryngoscopy - blade type laryngoscope - for foreign bodies such as fish bones, coins or small toys located above the cricopharyngeal muscle (glottic space). The equipment must include a complete kit for flexible and rigid endoscopy, and auxiliary equipment (Fig. 7) that includes mouse or crocodile teeth type forceps, polypectomy loops with or without a pannier, polyp extractors, Dormia type panniers, etc. (111). Flexible endoscopic technique is considered the first choice, especially for single foreign bodies with distal impaction site, and the rigid technique is the first option for multiple bodies, especially with proximal block. However, accessibility makes gastrofibroscopy to be the technique preferred by most experts, a rigid endoscope being considered only as a second option. The identification of pre-existing pathology is important as the endoscopy act may be difficult (COPD, asthma, etc.), or they may precipitate FB aspiration in the tracheobronchial tree. Left lateral decubitus position of the patient for flexible endoscopy is the standard method, avoiding supine position, while for performing rigid endoscopy the patient is placed in supine position, with his/her head and shoulders lifted. Intraoperatively, 5 technical principles enunciated by Chevalier Jackson (112) retain their applicability today as well- location, release, rotation, clamping and removal.

Several recommendations are related to the type of FB. If we consider an impacted food bolus as a foreign body, two

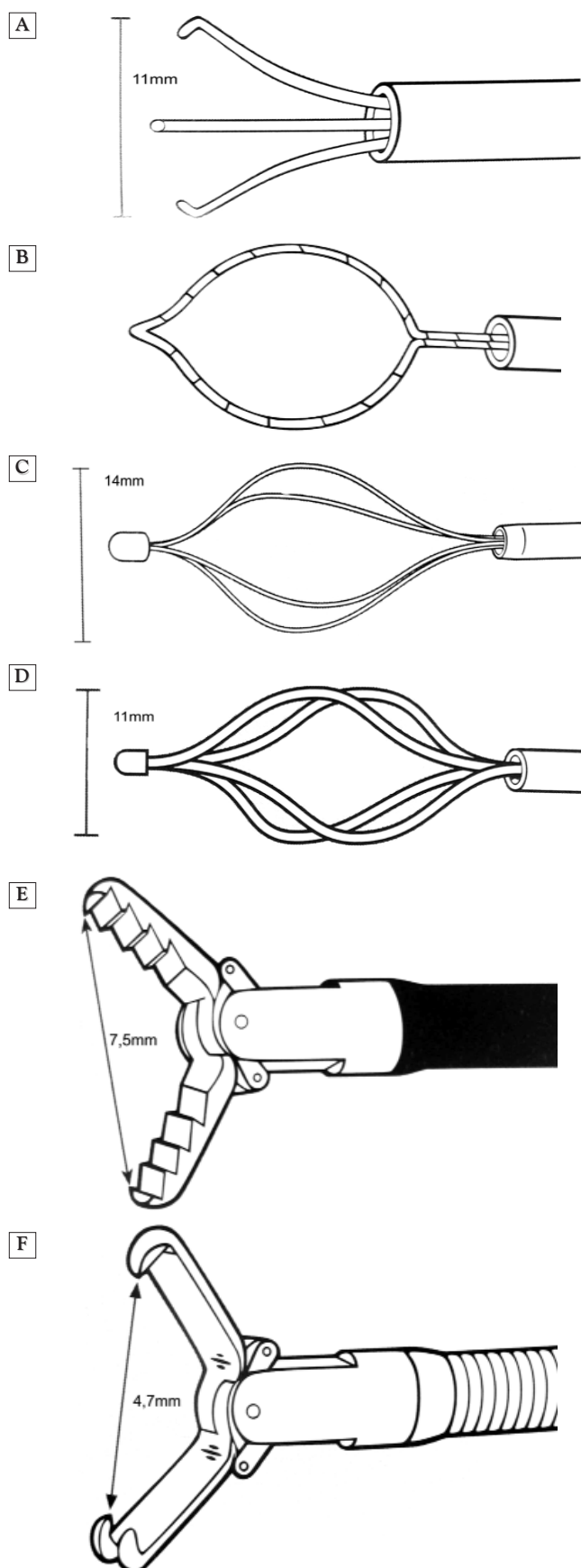


Figure 7. Various tools used in endoscopic extraction of FB (clamps, forceps, basket, etc.)

technical variants are described: *i)* en bloc extraction or progressive fragmentation with the crocodile teeth forceps and extracting residue via a polypectomy loom or a Roth basket *ii)* progressively pushing the bolus in the stomach (push technique). If in the case of the first method criticism is aimed at the high risk of aspiration of fragments and debris, in the second case it suggests the increasing number of punctured wounds due to identifying underlying pathologies at the impaction zone (11,17, 20). Latest studies (113, 114) conducted on a substantial number of cases reported no perforation complications and establish it as a safe method, with one condition: low pushing pressure, gentle in the middle of the bolus, and in terms of an inefficient gesture, marginal fragmentation persistent with bolus pressure.

The endoscopist's attitude is nuanced for so-called true foreign bodies. Coins and relatively rounded bodies, uniform, with blunt edges, are appropriate for conservative treatment if their size is <2.5 cm and they are located in the distal oesophagus (115); above this value endoscopy becomes the rule. The patient is recommended to be intubated, placed in the Trendelenburg position to minimize the risk of aspiration, extraction being performed with the crocodile teeth forceps, type Roth or Dormia pannier, or even the polypectomy forceps. "Button" batteries are extracted excellently via a Roth basket, "grappling" them with a crocodile teeth forceps being often impossible. Failure of extraction from the oesophagus can lead to the need to push the FB in the stomach, site where the possibility of manoeuvring and gripping/extracting by shifting the FB's position are much higher (116). Sharp foreign bodies (needles, bones, dentures, glass, etc.), as noted above, due to the high risk of perforation have indication for emergency extraction. The risk of oesophageal mucosa tear during the extraction is high, which is why it is recommended to push the FB into the stomach, as one can refocus and grab the object with the blunt side of the forceps, leaving the sharp one to be used near the end. In general, in preparing for extraction of a FB correct orientation is mandatory, but especially for long bodies, placing them on the longitudinal axis constituting the rule. The Roth pannier is often useless, but the Dormia pannier, polypectomy loop or crocodile forceps have instead proved their worth. Techniques are described to help protect the oesophagus, using an endoscopic tube placed in the oesophagus concomitantly with the endoscopy, in it being stored the extraction object ("penny pincher" technique), or a latex hood shaped as a bell (116). Failure of extraction or an incomplete extraction often determines the need for a new attempt. Recognizing an oesophageal perforation during endoscopy determines mandatory stenting (plastic or metal type fully-covered stents), checking every 24 hours via barium lunch, and its subsequent extraction about 4-5 weeks after installation (117,118).

Postendoscopic management includes temperature monitoring, pulse rate and breathing rate monitoring. Usually, administration of antibiotics or corticoids are not indicated, but obviously if tracheobronchial or oesophageal perforation occurs they are required. A good follow-up does not require thoraco-pulmonary X-ray, and the patient is discharged about

6 hours after endoscopic extraction, or the next day if not feverish, breathing is normal, and he does not require oxygen administration.

Non-endoscopic therapeutic options are described, for example extraction of FB under X-ray control, with the patient lying on the side, by means of a Foley probe or Fogarty 14-16 (119,120). The probe is inserted via the nose or mouth and placed under the foreign body, followed by swelling the balloon with a soluble contrast product up to a diameter estimated to be of the oesophagus, initiating light traction to ensure the mobility of the FB, subsequently performing extraction with the patient in Trendelenburg position, under radiological control. The technique is appropriate especially in children, but not only. The advantage of the cost of the manoeuvre is counteracted by reduced FB control, risk of aspiration and the impossibility of evaluating the parietal lesion. An alternative is that of oesophageal dilation, a method that involves "pushing" the FB in the stomach (121). This technique is reported as a success if applied in patients with ingestion of a single coin of small dimensions, the time elapsed since the intake is less than 24 hours, radiology identifies the site of impaction, there is no history of any other episodes of impaction, oesophageal pathology or surgery at this level, and the respiratory system is not involved. If we mention the extremely low costs of these methods - between 597 and \$ 1,884 for oesophageal dilation / Foley probe and between 3,100 and \$ 6,087 for endoscopy - as well as the consistent therapeutic success rates, with no compromises or serious complications, it is understandable why some specialists prefer to resort to them (122-124).

The option of surgery has become more recently the exception rather than the therapeutic rule, being considered after failure of other therapies, and when there is no other resource possible, when expecting progression through the lumen results in lack of mobilization for more than a week of the FB along the digestive tract, or when digestive complications (perforation with septic complications, obstruction, bleeding) for which there is no other solution occur.

Oesophageal approach is based on the site of impaction: left lateral cervicotomy along the SCM edge for the cervical segment, right thoracotomy in spaces IV, V or VI for cranial to caudal impaction, left distal thoracotomy or laparotomy for FB in the distal oesophagus. The technique involves oesophagotomy with FB extraction, followed by suture of the oesophageal wall. A good nasogastric Levin probe and good drainage are mandatory.

Cervical oesophageal approach is relatively easy, endurable, and usually accompanied by minor postoperative complications (125-131). Not the same can be said about thoracotomy (132, 133), especially in the elderly, the latter presenting other pathologies as well. Therefore, in recent times, a thoracoscopic and / or laparoscopic approach (134-137) may be a solution depending on the specificity of each case.

Fistula post-surgical risk is consistent, most often as a consequence of inflammatory / septic lesions due to impaction that will alter the quality of the parietal structure and therefore of the material suture. Cure of the fistula after primary surgical approach is possible, and only through

effective stenting (138-140).

The presence of perforation complicated with a collection more or less extensive rarely renders an oesophageal suture possible or effective, the main objective being to extract the FB with a sustained antiseptic lavage and efficient drainage. Postoperative stenting is recommended in this case as well, especially for abdominal and thoracic level impaction. An aggressive antibiotic therapy and providing a metabolic and fluid and electrolyte support by installing a PEG or jejunostomy are mandatory gestures.

There are particular situations such as narcotics smuggling by swallowing packages ("body packing") made of plastic, balloons or condoms (15,141,142). Since the risk of rupture with exitus by respiratory depression is higher in endoscopic extraction attempts, surgery is usually the only solution.

Conclusion

In conclusion, oesophageal foreign bodies are a frequent emergency, which causes functional symptoms and features that contrasts with poor clinical signs.

The most important treatment remains prevention and raising awareness among parents with children younger than 6 years. Preserving the airways free is the most important element in the management of FB.

Extraction treatment via natural methods is possible in most cases. For FB located in the hypopharynx and glottic space the most effective treatment is extraction by grasp forceps via rigid oesophagoscopy. For other oesophageal impaction sites flexible endoscopy is the first choice.

Variant endoscopy (e.g. oesophageal dilation or conservative treatment) are appropriate in some selected cases (size < 2.5 cm, uniform, blunt).

Surgical treatment cannot be avoided in cases where extraction was not managed by other methods or the patient developed complications.

References

1. Pellerin D, Fortier-Beaulieu M, Gueguen J. The fate of swallowed foreign bodies experience of 1250 instances of sub-diaphragmatic foreign bodies in children. *Progr Pediatr Radiol* 1969;2:286-302.
2. Weiland ST, Schurr MJ. Conservative management of ingested foreign bodies. *J Gastrointest Surg* 2002;6:496-500
3. Palta R, Sahota A, Bemarki A, et al. Foreign-body ingestion: characteristics and outcomes in a lower socioeconomic population with predominantly intentional ingestion. *Gastrointest Endosc* 2009;69:426-33
4. D.Pateron. Corps étrangers du tube digestif. *CHU JeanVerdier Université Paris XIII*.
5. Litovitovitz T.Schmitz B.F. Ingestion of cylindrical and button batteries, an analysis of 2520 cases. *Pediatrics* 1992; 89; 747-57
6. Webb WA. Management of foreign bodies of the upper gastrointestinal tract: update. *Gastrointest Endosc* 1995;41:39-51
7. Cheng W, Tam PK. Foreign-body ingestion in children: experience with 1265 cases. *J Pediatr Surg* 1999;34:1472-6
8. Hachimi-Idrissi S, Come L, Vandenpias Y. Management of ingested foreign bodies in childhood: our experience and review of the literature. *Eur J Emerg Med* 1998;5:319-23

9. Panieri E, Bass OH. The management of ingested foreign bodies in children - a review of 663 cases. *Eur J Emerg Med* 1995;2:83-7.
10. Weiland ST, Schurr MJ. Conservative management of ingested foreign bodies. *J Gastrointest Surg* 2002;6:496-500.
11. Abdullah BJJ, Teong LK, Mahadevan J, et al. Dental prosthesis ingested and impacted in the esophagus and orolaryngopharynx. *J Otolaryngol* 1998;27:190-4
12. Kamal I, Thompson J, Paquette OM. The hazards of vinyl glove ingestion in the mentally retarded patient with pica: new implications for surgical management. *Can J Surg* 1999; 42:201-4
13. Blaho KE, Merigian KS, Winbery SL, et al. Foreign body ingestions in the emergency department: case reports and review of treatment. *J Emerg Med* 1998;16:21-6
14. Simic MA, Budakov BM. Fatal upper esophageal hemorrhage caused by a previously ingested chicken bone: case report. *Am J Forensic Med Pathol* 1998;19:166-8
15. O. Ikenberry, Terry L. Jue, Michelle A. Anderson, Vasundhara Appalaneeni, Subhas Banerjee, Tamir Ben-Menachem et al (ASGE Standards of Practice Committee Steven) Management of ingested foreign bodies and food impactions – Guideline, *Gastrointestinal Endoscopy* 2011, Vol 73, No. 6: 1085-91
16. Guelfguat M, Kaplinskiy V, Srinivas H. Reddy, DiPoce J - Clinical Guidelines for Imaging and Reporting Ingested Foreign Bodies, *Am J Roentgenology* 2014 203:1, 37-53
17. Vizcarrondo FJ, Brady PG, Nord HJ. Foreign bodies of the upper gastrointestinal tract. *Gastrointest Endosc* 1983;29:208-10
18. Chu KM, Choi HK, Tuen HR, et al. A prospective randomized trial comparing the use of the flexible gastroscope versus the bronchoscope in the management of foreign body ingestion. *Gastrointest Endosc* 1998; 47:23-7.
19. Velitchkov NG, Grigorov GI, Losanoff JE, et al. Ingested foreign bodies of the gastrointestinal tract: retrospective analysis of 542 cases. *World J Surg* 1996;20:1001-5
20. Eisen GM, Baron TH, Dominitz JA, et al. Guideline for the management of ingested foreign bodies. *Gastrointest Endosc* 2002;55:802-806. (Clinical Guideline)
21. Gregory P Conners. Foreign Body Ingestions: Managing The Vast Array Of Objects Children Swallow. *Pediatrics*. 2005 Jun; vol 2; num 6.
22. Currarino G, Nikaidoh H. Esophageal foreign bodies in children with vascular ring or aberrant right subclavian artery: coincidence or causation? *Pediatr Radiol* 1991;21:406-408 (Case series; 4 patients)
23. Velanovich V, Ledbetter D, McGahren E, et al. Foreign bodies within a Meckel's diverticulum. *Arch Surg* 1992;127:864. (Case report)
24. Binder L, Anderson WA. Pediatric gastrointestinal foreign body ingestions. *Ann Emerg Med* 1984;13:112-117. (Retrospective medical record review; 125 patients)
25. Chaikhouni A, Kratz JM, Crawford FA. Foreign bodies of the esophagus. *Am Surg* 1985;51:173-9
26. William S. Crysedale, Khalil S. Sendi, and John Yoo Esophageal Foreign Bodies in Children 15-Year Review of 484 Cases *Ann Otol Rhinol Laryngol* April 1991 100: 320-324.
27. R I Macpherson, J G Hill, H B Othersen, E P Tagge and C D Smith Esophageal foreign bodies in children: diagnosis, treatment, and complications *American Journal of Roentgenology*. 1996;166: 919-924. 10.2214/ajr.166.4.8610574
28. Schwartz JT, Graham DY. Toothpick perforation of the intestines. *Ann Surg* 1977; 185:64-66
29. Slamon NB, Hertzog JH, Penfil SH, Raphaely RC, Pizarro C, Derby CD. An unusual case of button battery-induced traumatic tracheoesophageal fistula. *Pediatr Emerg Care* 2008; 24:313-316
30. Wu MH, Lai WW. Aortoesophageal fistula induced by foreign bodies. *Ann Thorac Surg* 1992; 54:155-156
31. Macchi, V., Porzionato, A., Bardini, R., Parenti, A. and De Caro, R. (2008), Rupture of Ascending Aorta Secondary to Esophageal Perforation by Fish Bone. *Journal of Forensic Sciences*, 53: 1181-1184. doi:10.1111/j.1556-4029.2008.00815.x
32. A. Champault, P. Cattan, Rupture aortique secondaire à l'ingestion d'une aiguille médicale. *Journal de Chirurgie*. 2009; 146(4): 442
33. Ginsberg GG. Management of ingested foreign objects and food bolus impactions. *Gastrointest Endosc* 1995;41:33-8
34. Smith MT, Wong RK. Foreign bodies. *Gastrointest Endosc Clin N Am* 2007;17:361-82
35. Koch H. Operative endoscopy. *Gastrointest Endosc* 1977;24:65-8
36. Ng KC, Mansour E, Eguare E. Retention of an ingested small blunt foreign body. *JBR-BTR* 2011; 94:339-342
37. Alexander WJ, Kadish JA, Dunbar JS. Ingested foreign bodies in children. *Progr Pediatr Radiol* 1969; 2:256-285
38. Ewing S, Miller R. Generalized nickel dermatitis in a 6-year-old boy as a result of swallowing a Canadian nickel. *J Am Acad Dermatol* 1991;25:855-856. (Case report)
39. Paopairochanakorn C, Warfield S, White S. Zinc toxicity associated with massive coin ingestion. *J Tox Clin Tox*. 2001;39:553.
40. Yelin G, Taff ML, Sadowski GE. Copper toxicity following massive ingestion of coins. *Am J Forensic Med Pathol* 1987;8:48-85.
41. Litovitz TL, Schmitz BF. Ingestion of cylindrical and button batteries: An analysis of 2382 cases. *Pediatrics* 1992;89:747-757. (Retrospective medical record review; 2382 patients)
42. Bronstein AC, Spyker DA, Cantilena LR Jr, et al. 2007 Annual Report of the American Association of Poison Control Centers' National Poison Data System (NPDS): 25th Annual Report. *Clin Toxicol(Phila)* 2008; 46:927-1057
43. Maves MD, Lloyd TV, Carithers JS. Radiographic identification of ingested disc batteries. *Pediatr Radiol* 1986; 16:154-156
44. Sue Y-J, Mercury. In: Nelson LS, Lewin NA, Howland MA, Hoffman RS, Goldfrank LR, Flomenbaum NE, eds. *Goldfrank's toxicologic emergencies*, 9th ed. Beijing, China: McGraw-Hill, 2011:1299-1307
45. C. Sevillano, M.N. Moraña, S. Estévez Visual involvement in foreign-body intestinal perforations *Archivos de la Sociedad Española de Oftalmología (English Edition)*. 2016;91(1):20-22
46. Milton T. Smith, Roy K.H. Wong Foreign Bodies Review Article *Gastrointestinal Endoscopy Clinics of North America*, Vol 17, Issue 2, April 2007, Pages 361-382
47. W Robert Foreign bodies in the gastrointestinal tract *Oct 2006 - Vol 18 - Issue 5 p 563-564*
48. Cummings Ch.W. – *Otolaryngology Head and Neck Surgery*, Ed. Mosby, 2001-2013, 1998)
49. Johnson WE. On ingestion of razor blades. *JAMA* 1969; 208:2163
50. Hodge D 3rd, Tecklenburg F, Fleisher G. Coin ingestion: does every child need a radiograph? *Ann Emerg Med* 1985; 14:443-6
51. American College of Radiology. ACR-SPR practiceguideline for the performance of abdominalradiography. American College of Radiologywebsite. www.acr.org/~media/79a594819bbd4631a7e31404daa66ef6.pdf. Published 2001. Revised2011. Accessed January 29, 2014
52. American College of Radiology. ACR-SPR practiceguideline for the performance of chest radiography.American College of Radiology website.www.acr.org/~media/B40302EE286D-4120AAEDE44B409DD45E.pdf. Published1993. Revised 2011. Accessed January 29, 2014
53. Smith SA, Conners GP. Unexpected second foreign bodies in pediatric esophageal coin ingestions. *Pediatr Emerg Care* 1998;14:261-262. (Retrospective medical record review; 83 patients)
54. Dowd MD. Esophageal coins. *Arch Pediatr Adolesc Med* 1994;148:423-424. (Case report)
55. Conners GP, Hadley JA. Esophageal coin with an unusual radiographic appearance. *Pediatr Emerg Care*. In press.
56. Maves MD, Lloyd TV, Carithers JS. Radiographic identification of ingested disc batteries. *Pediatr Radiol* 1986;16:154-156.

57. Aras MH, Miloglu O, Barutcugil C, Kantarci M, Ozcan E, Harorli A. Comparison of the sensitivity for detecting foreign bodies among conventional plain radiography, computed tomography and ultrasonography. *Dentomaxillofac Radiol* 2010; 39:72-78
58. Oikarinen KS, Nieminen TM, Makarainen H, Pyhtinen J. Imaging of Ingested Foreign Bodies. Visibility of foreign bodies in soft tissue in plain radiographs, computed tomography, magnetic resonance imaging, and ultrasound: an in vitro study. *Int J Oral Maxillofac Surg* 1993; 22:119-124
59. Lloyd M. ; Baker, Robert Nyhus *Mastery of Surgery VOL 1* (Hardcover - 1997)
60. Cedric G. Bremner, Tom R. DeMeester, James E. Huprich, and Ross M. Bremner *Esophageal Disease and Testing* (Hardcover - Aug 23, 2005)
61. Constantinoiu, D.Predescu. Evaluarea preoperatorie a pacienților cu patologie esofagiană. In: *Tratat de chirurgie, sub redactia Prof.Dr. Irinel Popescu, Vol VIII, Partea IB. București: Editura Academiei Române; 2008*
62. Akazawa Y, Watanabe S, Nobukiyo S, et al. The management of possible fishbone ingestion. *Auris Nasus Larynx* 2004; 31(4):413-6.
63. Mosca S. Management and endoscopic techniques in cases of ingestion of foreign bodies. *Endoscopy* 2000;32:232-3
64. Watanabe KI, Kikuchi T, Katori Y, et al. The usefulness of computed tomography in the diagnosis of impacted fish bones in the esophagus. *J Laryngol Otol* 1998;112: 360-4
65. James AE, Montali RJ, Chaffe V, et al:Barium or Gastrografin: Which contrast media for diagnosis of esophageal tear? *Gastroenterology*, 68:1103,1975
66. Predescu D, Constantinoiu S - Preoperative modern evaluation of patient with esophageal stenosis *Chirurgia (Bucur); 2003;98(6): 489-98.*
67. Vessal K, Montali RJ, Larson SM, et al: Evaluation of barium and Gastrografin as contrast media for the diagnosis of esophageal ruptures or complications, *Am J Roentgenol* 123: 307, 1975
68. Ginai AZ, ten Kate FJW, ten Berg RGM, Hoornstra K. Experimental evaluation of various available contrast agents for use in the upper gastrointestinal tract in case of suspected leakage. Effects on lungs. *Br J Radiol* 1984;57:895-901
69. Dodds WJ, Stewart ET, Vlymen WJ. Appropriate contrast media for evaluation of esophageal disruption. *Radiology* 1982;144:439-441. *AJR*
70. Rubin SA, Winsett MZ, Diner WC: Intrathoracic gastric balloon: Radiographic recognition of esophageal perforation, *Gastrointest Radiol* 7:311, 1982
71. Eliashar R, Dano I, Dangoor E, Braverman I, Sichel JY. Computed tomography diagnosis of esophageal bone impaction: a prospective study. *Ann Otol Rhinol Laryngol* 1999; 108:708-710
72. Marco De Lucas E, Sadaba P, Lastra Garcia-Baron P, et al. Value of helical computed tomography in the management of upper esophageal foreign bodies. *Acta Radiol* 2004; 45:369-374
73. Yong-Cai Liu, Shui-Hong Zhou, Ling Ling Value of helical computed tomography in the early diagnosis of esophageal foreign bodies in adults *The American Journal of Emergency Medicine*. 2013;31(9):1328-32
74. Luk WH, Fan WC, Chan RY, et al. Foreign body ingestion: comparison of diagnostic accuracy of computed tomography versus endoscopy. *J Laryngol Otol* 2009;123(5):535-40.
75. Loh WS, Eu DK, Loh SR, et al. Efficacy of computed tomographic scans in the evaluation of patients with esophageal foreign bodies. *Ann Otol Rhinol Laryngol* 2012;121(10):678-81.
76. Takada M, Kashiwagi R, Sakane M, et al. 3D-CT diagnosis for ingested foreign bodies. *Am J Emerg Med* 2000;18:192-3
77. Fadoo F, Ruiz DE, Dawn SK, Webb WR, Gorway MB. Helical CT esophagography for the evaluation of suspected esophageal perforation or rupture. *American Journal of Roentgenology* 2004;182:1177-9.
78. Koşucu P, Ahmetoğlu A, Koramaz I, et al. Lowdose MDCT and virtual bronchoscopy in pediatric patients with foreign body aspiration. *AJR* 2004; 183:1771-1777
79. Lane F, Donnelly, Kathleen H. Emery, A.S. Brody, T. Laor, Victoria M. Gylys-Morin, Ch.G. Anton, S.R. Thomas D.P. *Frush Minimizing Radiation Dose for Pediatric Body Applications of Single-Detector Helical CT Strategies at a Large Children's Hospital American Journal of Roentgenology* 2001 176:2, 303-306
80. Hojreh A, Prosch H.Dose optimization in CT examination of children *Radiologe*. 2012 Oct;52(10):927-33.
81. Ibrahim Adaletli , Sebuğ Kurugoglu, Sila Ulus, Harun Ozer, Mehmet Elicevik, Fatih Kantarci, Ismail Mihmanli, Canan Akman Utilization of low-dose multidetector CT and virtual bronchoscopy in children with suspected foreign body aspiration *Pediatric Radiology*. 2007;37(1):33-40
82. Ballesta-Lopez C, Vallet-Frenandez J, Catarci M, Bastida-Vila X, Nieto-Martinez B. Iatrogenic perforations of the esophagus. *Int Surg* 1993;78:28-31
83. Akman C, Kantarci F, Cetinkaya S. Imaging in mediastinitis: a systemic review based on aetiology. *Clin Radiol* 2004;59:573-85
84. A. Al-Qudah, S. Daradkeh, M. Abu- Khalaf Esophageal foreign bodies, *European Journal of Cardio-thoracic Surgery* 13 (1998) 494-499
85. Rodríguez H, Passali GC, Gregori D, Chinski A, Tiscornia C, Botto H, et al. Management of foreign bodies in the airway and oesophagus. *Int J Pediatr Otorhinolaryngol*. 2012 May 14;76 Suppl 1:S84-91
86. Spina P, Minniti S, Bragheri R. Usefulness of ultrasonography in gastric foreign body retention. *Pediatr Radiol Limite* 2000;30:840-841
87. Conners GP. Diagnostic uses of metal detectors: a review. *Int J Clin Pract*. doi 10.1111/j.1742-1241.2005.00456.x.
88. Conners GP. Finding aluminum foreign bodies. *Pediatr Rev* 2000;21:172.
89. Caraccio C, Sacchetti A, Lichenstein R. A new way to locate swallowed coins. *Contemp Pediatr* 1996;13:49-50, 53-54.
90. Nyhus I - *Esophageal Surgery, Second Edition*, New York, Lippincott, 2000
91. Chinitz MA, Bertrand CZ. Endoscopic removal of toothbrushes. *Gastrointest Endosc* 1990;36:527-30.
92. Russell R, Lucas A, Johnson J, Yannam G, Griffin R, Beierle E, Anderson S, Chen M, Harmon C. Extraction of esophageal foreign bodies in children: rigid versus flexible endoscopy. *Pediatr Surg Int*. 2014 Apr;30(4):417-22.
93. Gmeiner D, von Rahden BH, Meco C, Hutter J, Oberascher G, Stein HJ (2007) Flexible versus rigid endoscopy for treatment of foreign body impaction in the esophagus. *Surg Endosc* 21(11):2026-2029.
94. Popel J, El-Hakim H, El-Matary W (2011) Esophageal foreign body extraction in children: flexible versus rigid endoscopy. *Surg Endosc* 25(3):919-922.
95. Kim JK, Kim SS, Kim JI, et al. Management of foreign bodies in the gastrointestinal tract: an analysis of 104 cases in children. *Endoscopy* 1999;31:302-4.
96. Webb WA. Management of foreign bodies of the upper gastrointestinal tract: update. *Gastrointest Endosc* 1995;41:39-51
97. Holsinger JW, Fuson RL, Sealy WC. Oesophageal perforation following meat impaction and papain ingestion. *JAMA* 1968 ; 204 : 188-9.
98. Weant KA, Weant MP. Safety and efficacy of glucagon for the relief of acute esophageal food impaction. *Am J Health Syst Pharm*. 2012;69:573-7
99. Triadafilopoulos G1, Roorda A, Akiyama J. Update on foreign bodies in the esophagus: diagnosis and management. *Curr Gastroenterol Rep*. 2013 Apr;15(4):317.
100. Arora S, Galich P. Myth: glucagon is an effective first-line

- therapy for esophageal foreign body impaction. *CJEM*. 2009; 11:169-71.
101. Kaszar-Seibert DJ, Korn WT, Bindman DJ et al. Treatment of acute esophageal food impaction with a combination of glucagon, effervescent agent, and water. *Am J Roentgenol*. 1990; 154:533-4.
 102. Channer KS, Bolton R, Al-Hilli S et al. The effect of glucagon on the swallowing of capsules. *Br J Clin Pharmacol*. 1983;16:456-8.
 103. Hall-Boyer K, Zaloga GP, Chernow B. Glucagon: hormone or therapeutic agent? *Crit Care Med*. 1984; 12:584-9.
 104. Fass R, Dekel R. Intravenous glucagon in food impaction—use it or lose it? *Dysphagia*. 2004; 19:15-7.
 105. Deraney MF. Glucagon? One answer to cardiogenic shock. *Am J Med Sci*. 1971; 261:149-54.
 106. Lvoff R, Wilcken DE. Glucagon in heart failure and in cardiogenic shock. Experience in 50 patients. *Circulation*. 1972; 45:534-42.
 107. Bendig DW, Machel GO. Management of smooth-blunt gastric foreign bodies in asymptomatic patients. *Clin Pediatr* 1990;29:642-5.
 108. Stringer MD, Capps SN. Rationalizing the management of swallowed coins in children. *BMJ* 1991;302:1321-2.
 109. Chen T, Wu HF, Shi Q, Zhou PH, Chen SY, Xu MD, et al. Endoscopic management of impacted esophageal foreign bodies. *Dis Esophagus*. 2012 Sep 13.
 110. Wu WT, Chiu CT, Kuo CJ, Lin CJ, Chu YY, Tsou YK, et al. Endoscopic management of suspected esophageal foreign body in adults. *Dis Esophagus*. 2011;24(3):131–7. 111. Bounds BC. Endoscopic Retrieval Devices. *Tech Gastrointest Endosc*. 2006;8:16–21.
 112. W. Hsu, T. Sheen, C. Lin, C. Tan, T. Yeh, S. Lee, Clinical experiences of removing foreign bodies in the airway and esophagus with a rigid endoscope: a series of 3217 cases from 1970 to 1996. *Otolaryngol. Head Neck Surg*. 122 (March (3)(2000) 450–454.
 113. Vicari JJ, Johanson JF, Frakes JT. Outcomes of acute esophageal food impaction: success of the push technique. *Gastrointest Endosc* 2001;53: 178-81.
 114. Longstreth GF, Longatreh KJ, Yao JF. Esophageal food impaction: epidemiology and therapy. A retrospective, observational study. *Gastrointest Endosc* 2001;53:193-8.
 115. Waltzman ML, Baskin M, Wypij D, et al.: A randomized clinical trial of the management of esophageal coins in children. *Pediatrics* 2005, 116:614–619.
 116. Milton T. Smith, Roy K. H. Wong Esophageal foreign bodies: Types and techniques for removal *Current Treatment Options in Gastroenterology*. 2006;9(1):75-84
 117. Schmidt SC, Strauch S, Rösch T, Veltzke-Schlieker W, Jonas S, Pratschke J, et al. Management of esophageal perforations. *Surg Endosc*. 2010;24:2809–13.
 118. van Heel NC, Haringsma J, Spaander MC, Bruno MJ, Kuipers EJ. Short-term esophageal stenting in the management of benign perforations. *Am J Gastroenterol*. 2010;105:1515–20.
 119. Campbell JB, Quattromani FL, Foley LC. Foley catheter removal of blunt esophageal foreign bodies. Experience with 100 consecutive children. *Pediatr Radiol*. 1983;13(3):116-8.
 120. Conners GP A literature-based comparison of three methods of pediatric esophageal coin removal. *Pediatr Emerg Care*. 1997; 13(2):154-7.
 121. Bonadio WA, Jona JZ, Glicklich M, Cohen R: Esophageal bougienage technique for coin ingestion in children. *J Pediatr Surg* 1988, 23:917–918
 122. Arms JL, Mackenberg-Mohn MD, Bowen MV, Chamberlain MC, Skrypek TM, Madhok M, Jimenez-Vega JM, Bonadio WA. Safety and efficacy of a protocol using bougienage or endoscopy for the management of coins acutely lodged in the esophagus: a large case series. *Ann Emerg Med*. 2008 Apr;51(4):367-72. Epub 2007 Oct 15.
 123. Dahshan AH, Kevin Donovan G. Bougienage versus endoscopy for esophageal coin removal in children. *J Clin Gastroenterol*. 2007 May-Jun;41(5):454-6.
 124. Heinzerling NP, Christensen MA, Swedler R, Cassidy LD, Calkins CM, Sato TT. Safe and effective management of esophageal coins in children with bougienage. *Surgery*. 2015 Oct;158(4):1065-70; discussion 1071-2.
 125. Lohiya, G.-S., et al., Esophageal obstruction by a lemon that required esophagotomy: thoughts on prevention. *Ment. Retard*. 43(5):317-e321.
 126. Toshima, T., et al., Surgical removal of a denture with sharp clasps impacted in the cervicothoracic esophagus: report of three cases. *Surg. Today*. 41(9): 1275-e1279.
 127. Sockeel P. et al. Foreign body perforation of the thoracic esophagus. *J. de Chir.*146(1): p. 40e47.
 128. Imam, S.Z., et al., Cervical esophagotomy for an impacted denture: a case report. *Ear, Nose, Throat J*. 88(3): p. 833-834.
 129. N'Gattia, K.V., et al., [Extraction of the esophageal foreign bodies by cervicotomy: our experience about 9 cases]. *Rev. Laryngol. Otol. Rhinol*. 132(2): p.123-128
 130. Patrick Heger, Tim F. Weber, Johannes Rehm, Anita Pathil, Frank Decker and Peter Schemmer Cervical esophagotomy for foreign body extraction – Case report and comprehensive review of the literature *Journal: Annals of Medicine and Surgery*, 2016DOI: 10.1016/j.amsu.2016.04.001
 131. Chua YK, See JY, Ti TK. Oesophageal-impacted denture requiring open surgery. *Singapore Med J*. 2006;47:820–1.
 132. Miyazaki T, Hokama N, Kubo N, Ishiguro T, Sakimoto T, Ishibashi K, et al. Management of oesophageal foreign bodies: Experience of 90 cases. *Esophagus*. 2009;6:155–9.
 133. 2. Abdullah BJ, Teong LK, Mahadevan J, Jalaludin A. Dental prosthesis ingested and impacted in the esophagus and orolaryngopharynx. *J Otolaryngol*. 1998;27:190–4.
 134. Dalvi AN, Thapar VK, Jagtap S, et al. Thoracoscopic removal of impacted denture: Report of a case with review of literature. *Journal of Minimal Access Surgery*. 2010;6(4):119-121.
 135. Rückbeil O, Burghardt J, Gellert K. Thoracoscopic removal of a transesophageal ingested mediastinal foreign body. *Interact Cardiovasc Thorac Surg*. 2009;9:556–7.
 136. Raval MV, Campbell BT, Phillips JD. Case of the missing penny: Thoracoscopic removal of a mediastinal coin. *J Pediatr Surg*. 2004;39:1758–60.
 137. Palanivelu C, Rangarajan M, Parthasarathi R, Senthilnathan P. Thoracoscopic retrieval of a “smiling” foreign body from the proximal esophagus: An impacted denture. *Surg Laparosc Endosc Percutan Tech*. 2008;18:325–8.
 138. Deniz Than, Didem Trabulus, Aykut Altunkaya, Selami Karaca, Alper Chan, Halil Alif. Esophageal perforation due to inadvertent swallowing of a dental prosthesis *Turk J Gastroenterol* 2011; 22 (5): 529-33
 139. Bakken JC, Wong Kee Song LM, de Groen PC, Baron TH. Ues of a fully covered self-expandable metal stent for the treatment of benign esophageal diseases. *Gastrointest Endosc*. 2010;72(4): 712–20.
 140. Petersen JM. The use of a self-expandable plastic stent for an iatrogenic esophageal perforation. *Gastroenterol Hepatol*. 2010; 6(6):389–91.
 141. Lancashire MJR, Legg PK, Lowe M, et al. Surgical aspects of international drug smuggling. *BMJ* 1988;296:1035-7.
 142. Beno S, Calello D, Baluffi A, et al. Pediatric body packing: drug smuggling reaches a new low. *Pediatr Emerg Care* 2005;21:744-6.