

Clinical Significance of the Lymphoscintigraphy in the Evaluation of Non-axillary Sentinel Lymph Node Localization in Breast Cancer

M. Gherghe¹, C. Bordea², Al. Blidaru²

¹Nuclear Medicine Department, "Prof. Dr. Al. Trestioreanu" Institute of Oncology, Bucharest, Romania

²Surgical Oncology II Department, "Prof. Dr. Al. Trestioreanu", Institute of Oncology Bucharest, Romania

Rezumat

Semnificația clinică a evaluării limfoscintigrafice în localizarea non-axilară a ganglionului sentinelă în cancerul mamar

Introducere: Identificarea și biopsia ganglionului sentinelă (SLN) în stadiile precoce ale cancerului mamar (T1-T2N0) a devenit metoda standard în tratamentul chirurgical al axilei datorită acurateții evaluării statusului ganglionilor axilari, evitându-se disecția extensivă a axilei la pacienții cu SLN negativ. Studiul nostru își propune să evidențieze rolul limfoscintigrafiei cu ^{99m}Tc nanocoloid în vizualizarea preoperatorie a SLN, în special în cazul altor localizări decât cea axilară și aportul acestei tehnici în stadializarea corectă a cancerului mamar.

Material și metodă: Au fost incluși în studiu 430 de pacienți (vârsta 31-81 ani) cu cancer mamar (stadializare T1-T2N0), care au efectuat limfoscintigrafie pentru identificarea ganglionului sentinelă în cadrul Departamentului de Medicină Nucleară al Institutului Oncologic "Prof. Dr. Al. Trestioreanu" București în perioada octombrie 2008 – iulie 2014. S-a injectat peritumoral sau intradermic periareolar ^{99m}Tc-nanocoloid în doză de 20-37 MBq (volum de 0,3-0,5 ml) efectuându-se apoi achiziții dinamice și statice postinjectare. Identificarea ganglionilor

sentinelă intraoperator s-a realizat utilizând sonda gamma, după marcajul pe piele efectuat preoperator la finalizarea limfoscintigrafiei.

Rezultate: S-au identificat imagistic un număr de 697 ganglioni sentinelă la 427 din pacienți (99%). Dintre aceștia localizarea a fost axilară la 364 pacienți și non axilară (interpectorală, mamara internă, supraclaviculară, intramamară) la 48 pacienți (11%), un număr de 15 pacienți (3%) având localizare multiplă (axilară și non-axilară). Examenul histopatologic intraoperator a identificat un număr de 74 ganglioni sentinelă invadați (macrometastaze 12% și micrometastaze 88 %).

Concluzii: Identificarea și biopsia ganglionului sentinelă în stadiile I și IIA este o practică utilă în stadializarea corectă nu numai în cazul drenajului limfatic axilar, dar și în alte localizări mai rare ale extensiei ganglionare în cancerul mamar, orientând în continuare managementul acestor pacienți după efectuarea intervenției chirurgicale.

Cuvinte cheie: cancer mamar, biopsia ganglionului sentinelă (SLNB), limfadenectomia axilară (ALND)

Corresponding author: Mirela Gherghe, MD
Nuclear Medicine Department
"Prof. Dr. Al. Trestioreanu" Institute of Oncology
252 Fundeni Street, sector 2, Bucharest, 022112
Romania
E-mail: mirela_gherghe@yahoo.com

Abstract

Background: Identification and biopsy of the sentinel lymph node (SLN) in early-stage breast cancer (T1-T2N0) has become the standard method in the surgical treatment of the axilla, due to its accuracy in the evaluation of axillary lymph node status, thus avoiding extensive axillary lymph node dissection in patients with negative SLN. The aim of our study is to highlight the role of ^{99m}Tc-nanocolloid lymphoscintigraphy in the

preoperative lymphatic mapping, especially for SLN localizations outside the axilla, as well as the benefits of this technique in the accurate staging of breast cancer.

Materials and Method: 430 patients (age 31-81 years) with breast cancer (T1-T2N0 stage) were included in the study group, who underwent lymphoscintigraphy in order to identify the sentinel lymph node in the Nuclear Medicine Department of “Prof. Dr. Al. Trestioreanu” Institute of Oncology, Bucharest, between October 2008 - July 2014. Radiocolloid (^{99m}Tc -nanocolloid) was injected using peritumoral or periareolar intradermal technique, doses between 20-37 MBq (0.3-0.5 ml volume), followed by static and dynamic post-injection acquisitions. Intraoperative identification of the SLN was performed using a gamma-probe, guided by the skin marker performed preoperatively after completion of lymphoscintigraphy.

Results: 697 sentinel lymph nodes were identified through imaging techniques in 427 patients (99%). Of them, 364 patients had axillary localization of the SLN, while 48 patients (11%) had non-axillary (pectoral, internal mammary, supraclavicular, intra-mammary) localization and 15 patients (3%) had multiple localization (axillary and non-axillary). Intraoperative histopathological exam revealed lymphatic invasion in 74 SLN (12% macrometastases and 88% micro-metastases).

Conclusions: The identification and biopsy of the sentinel lymph node in stages I and IIA is a useful routine for accurate breast cancer staging, suited for axillary lymphatic drainage, as well as for unusual non-axillary SLN localization, guiding the clinician for further postoperative management of these patients.

Key words: breast cancer, sentinel lymph node biopsy (SLNB), axillary lymph node dissection (ALND)

Introduction

The status of the axillary lymph nodes in breast cancer is one of the most important prognostic factors. Despite impressive progress of imagistic methods in the last decades, especially the introduction of PET-CT and, more recently, PET-MRI in the complete staging of breast cancer, they could not offer concrete information on micro-metastases in the axillary lymph nodes or other lymphatic drainage basin of the breast. The introduction of the sentinel lymph node (SLN) technique represented a revolutionary moment in the conservative surgery of the axilla, which nowadays has come to replace lymphatic axillary dissection not only in the T1-T2N0 clinical stages, but also in many particular situations like multicentric tumours, breast cancers treated preoperatively with chemotherapy, after excisional biopsy or other limited interventions for benign pathologies. Thus, in the last three decades, conservative surgery of the breast and axilla in stages I and II led to a reduction in number of cases requiring axillary

lymphadenectomy by up to two thirds. (1)

The concept of sentinel node was introduced by Ramon Cabanas in 1977 for penile cancer (2) and then developed by Jim Morton in malignant melanoma (3), but it wasn't until 1992 that it was introduced in clinical practice by using blue dye or radioactive isotopes. In 1994, Armando Giuliano described SLNB as a safe procedure for axillary staging, its utility being later confirmed by Umberto Veronesi through clinical studies.

SLNB is based on the hypothesis that lymphatic drainage at the level of the breast tumor takes place first in the sentinel lymph node and only after in other nodes from the referred lymphatic territory (axillary or non-axillary). This is why the identification and biopsy of the sentinel node offers information on the status of the whole lymphatic drainage basin; classically it is considered that if the SLN presents metastatic cells, then axillary lymphatic dissection is required and, if not, this procedure can be avoided. Survival rate is similar (90.3% compared to 91.8% in the NSABP B32 study) (4,5,6,7), the advantage of SLN biopsy being that of a less invasive surgical technique, with minimal postoperative complications. The common complications occurring after axillary lymphatic dissection, such as pain, limited movement in the shoulder joint, paraesthesia and lymphedema, have a significantly reduced incidence (17% compared to 3%) in conservative interventions with limited breast resection and sentinel node biopsy. (8)

Therefore, the SLNB method was quickly approved in clinical practice, confirmed by numerous multicentric trials to be highly accurate [97% in the study published by Krag et al (9)], becoming over the last decades the standard approach for surgical treatment of stage I and II breast cancer in all clinical guidelines (NCCN Guidelines) (10).

Moreover, the latest randomized clinical trials, like the one conducted by the American College of Surgeons Oncology Group (ACOSOG Z0011), which included patients with metastases in one up to three sentinel lymph nodes, in order to see whether axillary lymphadenectomy was needed or a “wait and see” attitude could be adopted, demonstrated that there are no major statistical differences in the general survival or the disease-free survival rate after a medium interval of 6.3 years (11). This is why, according to the most recent therapeutic guidelines (12) it is considered that in most of the cases presenting with one or two metastatic sentinel nodes, axillary lymph node dissection is not mandatory if the patients undergo conservative surgery followed by external radiotherapy.

Correct identification of the sentinel lymph node implies, however, accurate lymphatic mapping, which can be currently done by using different imaging techniques, but in clinical practice the radiopharmaceutical method was imposed due to its accuracy, simplicity and reproducibility.

Materials and Method

In our study, we evaluated the lymphoscintigraphic investigations of 430 patients admitted at “Prof. Dr. Al. Trestioreanu” Institute of Oncology between October 2008 and July 2014,

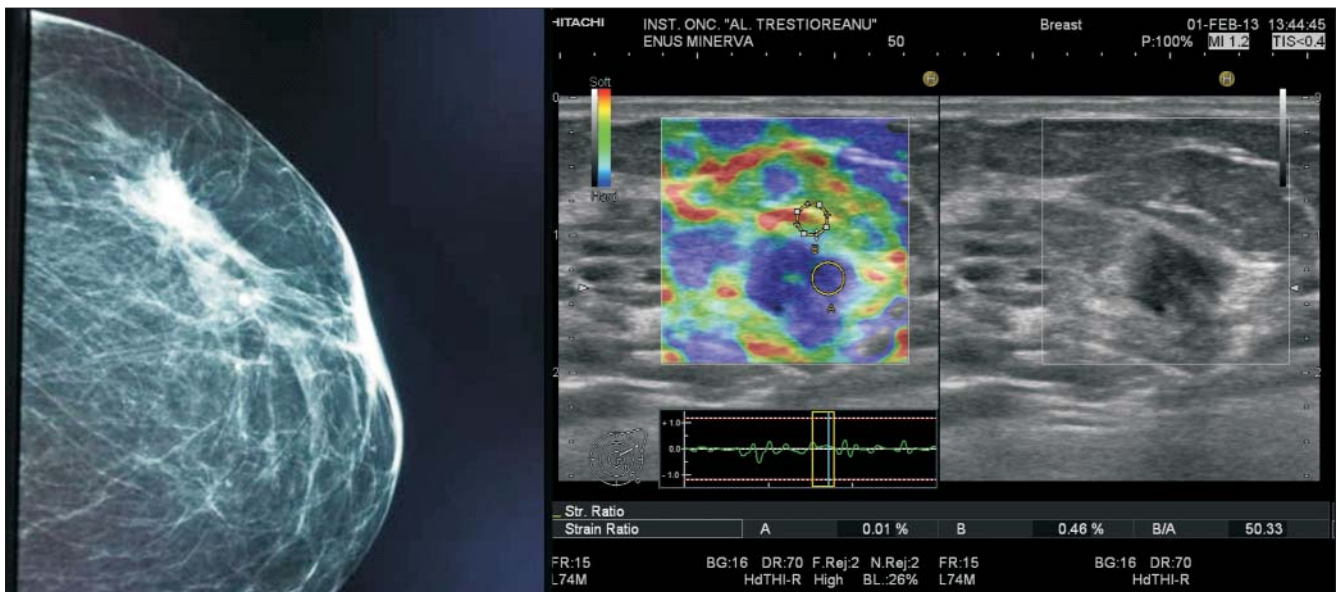


Figure 1. Mammography, 2D ultrasound and sonoelastography aspect of a BIRADS 5 breast tumour

with ages ranging from 31 to 81 year-old.

The patients were diagnosed with stage I or II breast tumours, using mammography (digital or classic), ultrasonography (in some cases associated with sonoelastography) and breast MRI, in that cases when mammography and echography tests were incomplete in providing the full characteristics of the lesions, as imagistic methods. (Fig. 1)

Tumours were classified into BIRADS 3, 4 and 5 by imaging techniques, and histopathological confirmation was obtained by core needle biopsy or excisional biopsy, using the classic method of paraffin-embedded sections or immunohistochemistry. Clinical or imaging signs of lymphatic node involvement represented an exclusion criterion from our study. Therefore, in accordance with TNM staging, the patients involved in the study presented with breast tumours classified as T1N0M0 or T2N0M0.

Lymphoscintigraphic examination for identifying the SLN used radiopharmaceutical Tc99m-nanocolloid, administered 18-20 hours prior to the surgical intervention. The radiopharmaceutical contains 5-100 nm particles and ensures both a fast lymphatic drainage and an optimal retention in the SLN, so that it can be detected intraoperatively using a gamma-probe (13). In most of the cases, we injected peritumorally a small volume (0.3-0.5 ml) of ^{99m}Tc -nanocolloid with 20-37 MBq activity, followed by soft massage of the injection site. For tumours localized in the central quadrant we used the periareolar intradermic injection technique, bearing in mind the well-known theories according to which lymphatic drainage of the central quadrant is similar to that of the areola.

Lymphoscintigraphic acquisition was performed using a “dual head” gamma camera, equipped with high resolution collimators, obtaining images in anterior, oblique and lateral incidences, at 30 minutes intervals until the SLNs were visualised (at maximum 4 hours after the injection). Static

acquisition of 500 kcounts were obtained in each incidence (anterior, lateral and oblique), and in case of periareolar intradermic injection, dynamic acquisition lasting 15 minutes, with 1frame/20 sec were started with. At the end of visualization, sentinel node skin marks were made using a small source of ^{99m}Tc in order to guide the surgical incision. For a more precise outline of the body, a flood phantom with a solution of ^{99m}Tc was used. (Fig. 2)

Image processing was performed using special static and dynamic operating data software. A focal uptake of the radiotracer is considered to be the sentinel lymph node if an afferent lymphatic vessel can be highlighted or if it represents the first or the only one visible focus of radiotracer accumulation in a certain lymphatic territory on the sequentially acquired images.

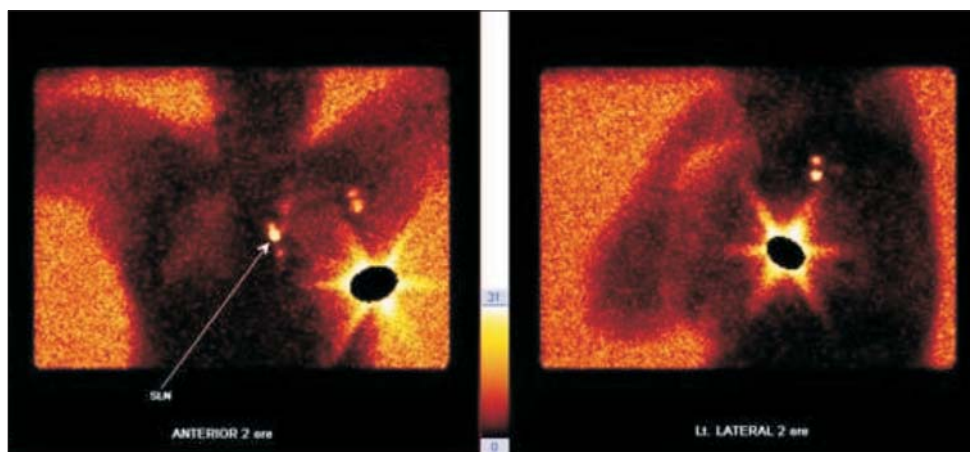
Intraoperative identification of the sentinel nodes was performed 18-20 hours after the radiotracer injection, by the team of the Surgical Oncology Clinic II, by using a high spatial resolution and sensitivity gamma-probe. Sentinel lymph node dissection was performed employing surgical techniques suited for each localization individually. (Fig. 3)

Results

430 patients diagnosed with breast cancer after mammography, ultrasound, as well as sonoelastography or breast MRI in selected cases, without clinical or imaging signs of lymphatic extension were included in the study and were preoperatively staged as T1N0M0 or T2N0M0.

From an imaging point of view, in most of the patients (367) standard digital mammography and high frequency probe ultrasonography were enough to include the tumours in the high malignancy risk categories (BIRADS 5 or BIRADS 4b and 4c). The remaining patients required association of sonoelasto-

Figure 2. Preoperative lymphoscintigraphy with SLN visualization in the axillary and internal mammary lymph nodes



graphy (37 cases) or breast MRI (26 cases) in order to precisely define the non-conclusive lesions detected by mammography and/or ultrasonography and to classify them in groups 4 and 5 according to American College of Radiology.

The tumours in the study lot were most frequently identified in the upper-outer quadrant and the central quadrant of the breast (76% of cases).

Histopathological exam revealed a number of 9 in situ carcinomas, 348 invasive ductal carcinomas, 34 lobular carcinomas, the remaining 39 cases presenting associations of invasive ductal and invasive lobular carcinomas or invasive ductal and lobular in situ carcinomas. Examination of the paraffin-embedded sections confirmed the results obtained from the extemporaneous intraoperative tests in 396 cases; in 31 other patients the histopathological examination revealed with certainty associated histological types of carcinomas that were not initially diagnosed.

The lymphoscintigraphy performed after injecting the ^{99m}Tc -nanocolloid identified SLNs at intervals between 3 minutes (in case of periareolar intradermic injections) and 4

hours after injection, in the majority of cases (67%) visualization being obtained between 30 and 60 minutes postinjection. SLN localization after lymphoscintigraphy, dynamic or static sequential visualizations, was axillary in 364 patients and non-axillary in 48 patients (internal mammary in 21 patients, intramammary in 9 patients, pre- or interpectoral in 11 patients and supraclavicular in 7 patients). 15 patients presented multiple localizations, respectively axillary associated with one of the non-axillary groups for breast drainage. In 3 patients (0.7% of cases) the sentinel node could not be revealed by lymphoscintigraphy up to 4 hours after injection. (Table 1)

697 SLN were identified intraoperatively using gamma-probe Neoprobe 2000, with good spatial resolution and sensitivity. Frozen extemporaneous histopathological exams of the excised sentinel lymph nodes, as well as paraffin-embedded sections, were performed, revealing 74 metastatic SLN (65 patients presenting micrometastases and 9 patients presenting macrometastases). In cases where the intraoperative histopathological exam revealed metastases in the axillary nodes, the surgical intervention continued with axillary lymphadenectomy. In 48 patients with non-axillary localizations (single or multiple) 69 SLN were found, of which 5 nodes presented tumour invasion (4 micrometastases and 1 macrometastases), thus leading to treatment course change in 10% of the cases, by modifying the local or systemic therapy.

If we refer to the type of surgical intervention performed at the breast level, it has been decided that a conservative treatment (with limited breast resection) was suitable for 273 patients, the remaining 157 patients being submitted to radical treatment (modified radical mastectomy). Regarding axillary surgery, after identification of metastases in the sentinel lymph nodes during intraoperative histopathological exam, the approach of choice was that of completing the intervention with axillary lymphadenectomy. (Table 2)

In case of non-axillary localization of the SLNs diagnosed with micro- or macrometastases, their excision was followed by modification of the classic therapeutic attitude, by performing radiotherapy that includes in the target volume the site of the non-axillary lymph node and, depending on the tumour grading, by adding adjuvant chemotherapy.

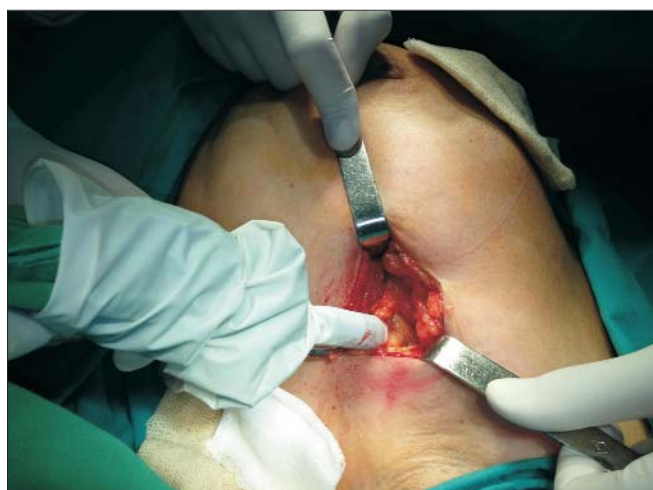

Figure 3. SLN intraoperative detection using gamma-probe

Table 1. Clinical and pathological characteristics of patients in the study group

Average age	T stage	Tumour localization	Histologic type	Hormonal receptors status
<40 years - 73 pts (17%)	T1a -28 (7%)	Outer quadrants - 284 (66%)	IDC - 348 (81%)	ER+/PR+ 374 (87%)
41-55 years -138 pts (32%)	T1b - 79 (18%)	Inner quadrants - 107 (25%)	ILC - 34 (8%)	ER-/PR- 56 (13%)
56-65 years -166 pts (39%)	T1c - 147 (34%)	Central quadrant - 39 (9%)	DCIS - 9 (2%)	HER2+ 52 (12%)
>65 years - 53 pts (12%)	T2 - 176 (41%)		Others - 39 (9%)	HER2 - 307 (71%)
				HER2 unknown-71 (17%)

Table 2. Study results regarding the localization and histopathological exam of SLN

SLN Localization	SLN Visualization Interval	SLN Histopathological Result
Axillary – 364 pts (85%)	<5 min - 41 pts	Micrometastases 65 pts
Non-axillary – 48 pts (11%)	5-30 min - 85 pts	Macrometastases 9 pts
- internal mammary 21		
- intra-mammary 9	30-60 min - 179 pts	Negative 356 pts
- pre- or inter-pectoral 11		
- supraclavicular 7	60-120 min - 71 pts	
Multiple - 15 pts (3%)	>120 min - 51 pts	

Discussion

Introducing the dissection of the sentinel lymph node represented a remarkable progress in the conservative surgery of breast cancer, determining an important decrease of complications regarding axillary lymphadenectomy and identification of patients with minimal tumour invasion in the regional lymphatic nodes. In these cases, choosing the optimal surgical treatment and the adjuvant therapy is still under debate all over the world (14). Most recent studies, summarized by the latest update of the American Society of Clinical Oncology Guideline (12), highlights that axillary lymphatic dissection can be omitted in patients with only 1-2 invaded SLN, if these present only isolated tumor cells or micrometastases. As a result, current efforts focus on identifying these subgroups of patients in whom classical lymphadenectomy can be avoided, even if they present micrometastases, without significant increasing of recurrence rates (15).

At “Prof. Dr. Al.Trestioreanu” Institute of Oncology a sustained effort has been shown over the last decades to diagnose and treat early stage breast cancers at current standards (16). Since the introduction of the SLN method in 2005, the number of patients who have benefited from this type of intervention has constantly increased by approximately 12-15% each year (17). Using modern imaging methods (digital mammography, breast tomosynthesis, sonoelastography or MRI) it became possible to diagnose an increasingly higher number of patients presenting with stage I-II breast cancer, expanding the possibilities of an efficient treatment, with high survival rate, but also with excellent aesthetic and functional results.

Nevertheless, in comparison with West-European countries or the USA, in Romania, due to a lack of a screening program, the number of patients with breast cancer detected in early stages remains very small, more than half of the patients presenting to the hospital with stage III or IV disease

(18). However, mass media campaigns regarding the population awareness on seeing the doctor from the first signs of disease, and the necessity of performing periodically mammography and breast ultrasound, especially in patients with familial history of breast cancer, succeeded to a considerable increasing number of cases diagnosed in early stages during the last years, even with infraclinical tumours.

Performing preoperative lymphoscintigraphy in all patients with stage I and II breast tumours, without clinical or imaging signs of lymphatic node involvement, is very useful in identifying the lymphatic drainage basin of the tumour, and the sentinel lymph node respectively, whose biopsy has been proven to accurately estimate the status of regional nodes. As evidenced by the result of our study, SLNs in breast cancer do not mandatorily have axillary localization, which determines the change of the surgical attitude and further treatment management.

Of the 430 patients included in our study 11% presented non-axillary localization of the SLN, a result close to that obtained by van Rijk et al. in a 785 patient case study (12%) (19). However, other studies showed significantly higher percentages of non-axillary lymphatic drainage; thus, the 700 patient case study developed by Susanne H. Estourgie et al. reported percentages of 24% for palpable tumours and 43% for non-palpable tumours (20). This difference could be explained both by the variable localization of the tumour and by the use of different injection techniques of the radiotracer; for example in case of superficial injection, the rate of migration in the extra-axillary lymphatic territory is lower than when the injection is profound, peritumoral, a fact that confirms that deep lymphatic vessels from the posterior region of the breast drain in these lymph nodes. Paganelli et al. showed that after deep administration of the radiotracer in the breast parenchyma at the level of the inner quadrants, drainage in the internal mammary nodes appears in 66% cases, compared to 10% in

case of outer quadrants localization of the tumour (21).

In our study we noticed that tumours located in the inner quadrants more frequently drain in non-axillary nodes, compared to the tumours from the outer quadrants (16% beside 5%) especially to the internal mammary chain. The accuracy of the method is based on the use of a peritumoral injection technique, using a small volume of radiotracer, which allowed lymphatic drainage visualization without significant distortions. We used periareolar intradermic injection only in that circumstances when the tumour was located in the central quadrant, because we considered that, in the other cases it does not reflect the physiological drainage of the tumour (22). Even if intradermic injection is easier to perform, it is also less painful and leads to quicker and more frequent visualization of the SLN, this method will rarely determine a lymphatic drainage to another basin than the axillary one (23), because cutaneous lymphatic vessels do not precisely reflect the lymphatic drainage of the breast glandular tissue.

Even though the majority of studies prove that a combination of radiocolloid injection and blue dye is the method with the highest rate of SLN identification, in our study we have obtained a 99% visualization rate. We could not use blue dye, as there is no one authorized product on the Romanian pharmaceutical market. There are, however, studies proving the superiority of one method or the other, the results actually reflecting the experience and preference of the multi-disciplinary team of each institution.

Lymphoscintigraphic identification of non-axillary SLN led both to a correct oncological staging, and to avoiding useless axillary dissection. Even if the percentage of metastasized SLN is more reduced compared to the axillary region, it is however significant in some localizations of the primary tumour and determines changes in therapeutic approach. Thus, in the study group, identifying metastases in the internal mammary, supraclavicular or pectoral sentinel lymph nodes required inclusion of these regions in the radiotherapy plan, as well as neo-adjuvant chemotherapy for highly aggressive tumours.

Conclusions

Preoperative lymphoscintigraphy performed after peritumoral administration of radiocolloid is a sensitive and reproducible technique that allows precise identification of the SLN in both axillary and non-axillary territories. The identification of SLN outside the axilla was found in 11% of patients, 10% of them presenting metastases that led to changes in therapeutic approach (surgical intervention as well as postoperative radio- or chemotherapy). From a surgical point of view, we consider that highlighting the extra-axillary localization of SLNs strictly can avoid classic axillary lymph node dissection, its omission in particular cases seeming to be the appropriate option. An adequate injection technique offers a complete image of the breast tumour's lymphatic drainage, determining accurate staging and an appropriate therapeutic approach. The implications of metastasis presence in non-axillary SLN on the local

recurrence risk and survival rate are still under debate and require further research on larger groups of patients.

References

1. Kootstra JJ, Hoekstra-Weebers JE, Rietman JS, de Vries J, Baas PC, Geertzen JH, Hoekstra HJ A longitudinal comparison of arm morbidity in stage I-II breast cancer patients treated with sentinel lymph node biopsy, sentinel lymph node biopsy followed by completion lymph node dissection, or axillary lymph node dissection. *Ann Surg Oncol*. 2010 Sep;17(9):2384-94.
2. Cabanas RM. An approach to the treatment of penile carcinoma. *Cancer*. 1977;39(2):456-66.
3. Morton DL, Wen DR, Wong JH, Economou JS, Cagle LA, Storm FK, et al. Technical details of intraoperative lymphatic mapping for early stage melanoma. *Arch Surg*. 1992;127(4):392-9.
4. Krag DN, Anderson SJ, Julian TB, et al.(2010) Sentinel-lymph-node resection compared with conventional axillary-lymph-node dissection in clinically node-negative patients with breast cancer: Overall survival findings from the NSABP B-32 randomised phase 3 trial. *Lancet Oncol* 11:927-933.
5. Weaver DL, Ashikaga T, Krag DN, et al.(2011) Effect of occult metastases on survival in node-negative breast cancer. *N Engl J Med* 364:412-421.
6. Krag DN, Anderson SJ, Julian TB, et al.(2007) Technical outcomes of sentinel-lymph-node resection and conventional axillary-lymph-node dissection in patients with clinically node-negative breast cancer: Results from the NSABP B-32 randomised phase III trial. *Lancet Oncol* 8:881-888.
7. Harlow SP, Krag DN, Julian TB, et al.(2005) Prerandomization Surgical Training for the National Surgical Adjuvant Breast and Bowel Project (NSABP) B-32 trial: A randomized phase III clinical trial to compare sentinel node resection to conventional axillary dissection in clinically node-negative breast cancer. *Ann Surg* 241:48-54.
8. Sagen A, Kaaresen R, Sandvik L, Thune I, Risberg MA. Upper limb physical function and adverse effects after breast cancer surgery: a prospective 2.5-year follow-up study and pre-operative measures. *Arch Phys Med Rehabil*. 2014 May;95(5):875-81.
9. Krag D, Weaver D, Ashikaga T, et al. The sentinel node in breast cancer: a multicenter validation study. *N Engl J Med*. 1998;339(14):941-946.
10. NCCN Clinical Practice Guidelines in Oncology www.nccn.org/professionals/.
11. Elisabeth G Klompenhouwer, Paul D Gobardhan, Martinus A Beek, Adri C Voogd and Ernest JT Luiten. The clinical relevance of axillary reverse mapping (ARM): study protocol for a randomized controlled trial. *Trials* 2013;14:111.
12. Gary H. Lyman, Sarah Temin, Stephen B. Edge, Lisa A. Newman, Roderick R. Turner, Donald L. Weaver, Al B. Benson III, Linda D. Bosserman, Harold J. Burstein, Hiram Cody III, James Hayman, Cheryl L. Perkins, Donald A. Podoloff and Armando E. Giuliano. Sentinel Lymph Node Biopsy for Patients With Early-Stage Breast Cancer: American Society of Clinical Oncology Clinical Practice Guideline Update. *JCO*, May 1 2014 vol.32, no 13, 1365-1383.
13. Francesco Giammarile & Naomi Alazraki & John N. Aarsvold & Riccardo A. Audisio & Edwin Glass & Sandra F. Grant & Jolanta Kunikowska & Marjut Leidenius & Valeria M. Moncayo & Roger F. Uren & Wim J. G. Oyen & Renato A.

- Valdés Olmos & Sergi Vidal Sicart. The EANM and SNMMI practice guideline for lymphoscintigraphy and sentinel node localization in breast cancer. *Eur J Nucl Med Mol Imaging* (2013) 40:1932–1947.
14. Wasif N, Maggard MA, Ko CY, Giuliano AE. Underuse of axillary dissection for the management of sentinel node micrometastases in breast cancer. *Arch Surg* 2010 Feb;145(2):161-6.
 15. Van Deurzen CH, MonnikhofnEM, Bult P, et al. Non-sentinel lymph node metastases associated with isolated breast cancer cells in the sentinel node. *J Natl Cancer Inst* 2008 Nov 19;100(22):1574-80.
 16. Bălănescu I, Blidaru AI. Cancerul sânuului. In: Angelescu N, ed. *Tratat de patologie chirurgicală*. București: Editura Medicală; 2003.
 17. Blidaru A, Bordea C, Voinea S, Condrea I, Albert P, HoucheimiB. Validation protocol of sentinel node biopsy for breast cancer using radioactive tracer at the Institute of Oncology Bucharest "Prof. Dr. Alexandru Trestioreanu". *Chirurgia (Bucur)*. 2006;101(4):391-9.
 18. C. Bordea, M. Plesca, I. Condrea, M. Gherghe, A. Gociman, A. Blidaru. Occult Breast Lesion Localization and Concomitant Sentinel Lymph Node Biopsy in Early Breast Cancer (SNOLL). *Chirurgia* (2012) 107: 722-729.
 19. Van Rijk MC, Tanis PJ, Nieweg OE et al. Clinical implication of sentinel nodes outside the axilla and internal mammary chain in patients with breast cancer. *J Surg Oncol*. 2006; 94:281-6.
 20. Estourgie SH, Nieweg OE, Valdes Olmos RA, et al. Lymphatic drainage patterns from the breast. *Ann Surg* 2004;239:232-237.
 21. Paganelli G, Galimberti V, Trifirò G, Travaini L, De Cicco C, Mazzarol G, Intra M, Rocca P, Prisco G, Veronesi U. Internal mammary node lymphoscintigraphy and biopsy in breast cancer. *Q J Nucl Med*. 2002 Jun;46(2):138-44.
 22. Povoski SP, Olsen JO, Young DC, Clarke J, Burak WE, Walker MJ, Carson WE, Yee LD, Agnese DM, Pozderac RV, Hall NC, Farrar WB: Prospective randomized clinical trial comparing intradermal, intraparenchymal, and subareolar injection routes for sentinel lymph node mapping and biopsy in breast cancer. *Ann Surg Oncol* 13:1412-1421, 2006.
 23. Celliers L, Mann GB. Alternative sites of injection for sentinel lymph node biopsy in breast cancer. *ANZ J Surg*. 2003 Aug;73(8):600-4.