

Congenital Agenesis of the Inferior Vena Cava - Cause of Deep Vein Thrombosis

A. Bolocan^{1,2}, D. Ion^{1,2}, D.N. Ciocan¹, D.N. Păduraru^{1,2}

¹IIIrd Emergency General Surgery Department, Emergency University Hospital, Bucharest, Romania

²"Carol Davila" University of Medicine and Pharmacy, Bucharest, Romania

Rezumat

Agenezia congenitală de venă cavă inferioară – cauză complexă de tromboză venoasă profundă

Agenezia de venă cavă inferioară este o malformație extrem de rară, de cele mai multe ori descoperită întâmplător. Lucrarea de față prezintă cazul unui pacient de sex masculin, în vârstă de 41 de ani internat în Clinica de Chirurgie Generală III a Spitalului Universitar de Urgență București cu diagnosticul de sindrom posttrombotic la nivelul membrelor pelvine bilaterale. Din antecedentele personale chirurgicale reținem că prima intervenție în sfera vasculară a fost efectuată la vârsta de 6 ani. Indicația a fost determinată de prezența varicelor hidrostatice voluminoase la nivelul membrelor inferioare bilaterale, practicându-se crosectomie cu stripping al venelor safene mari bilaterale. Până la internarea în clinica noastră, pacientul a suferit intervenții chirurgicale repetate pentru varice hidrostatice recidivate la nivelul membrelor inferioare. Pacientul a fost diagnosticat în serviciul clinicii noastre cu agenezie congenitală de venă cavă inferioară, evoluția fiind lent favorabilă, pacientul externându-se la 17 de zile de la internare. Prezentarea descrie particularitățile clinice, imagistice și terapeutice ale unui astfel de caz. Considerăm esențială pentru evoluția favorabilă a pacientului nostru decelarea imagistică precoce a anomaliei vasculare, identificarea factorilor procoagulanti asociați și îngrijirea minuțioasă a leziunilor locale.

Cuvinte cheie: agenezie de venă cavă inferioară, tromboză venoasă profundă, ulcer varicos

Abstract

Agnesis of the inferior vena cava is an extremely rare abnormality, most often discovered by accident. This paper reports the case of a 41-year-old male patient, admitted to the IIIrd Emergency General Surgery Clinic of the Emergency University Hospital with the diagnosis of bilateral pelvic limb post-thrombotic syndrome. According to his personal history he had the first vascular surgical intervention at the age of 6. The surgical indication was determined by large hydrostatic varicose veins of the lower limbs and the performed surgery was crosectomy with bilateral stripping of the great saphenous vein. Until admission to our clinic, the patient had repeated surgery for recurrent varicose veins of the lower limbs. The patient was diagnosed in our service with congenital agnesis of inferior vena cava, the evolution was good and the patient was discharged after 17 days. This paper presents the clinical, imagistic and therapeutic particularities of such a case. Imagistic detection of early vascular abnormality, identifying procoagulant factors and the close care of the local lesion are essential for patient evolution.

Key words: agnesis of the inferior vena cava, deep vein thrombosis, varicose ulcer

Corresponding author: Dan Nicolae Păduraru, MD
IIIrd Emergency General Surgery Department
Emergency University Hospital
Bucharest, Romania
E-mail: dan.paduraru.nicolae@gmail.com

Introduction

Most studies report that in Romania venous disease affects

32% of the adult population. (1)

The most frequent and most characteristic clinical manifestations of these diseases occur in the veins of the lower limbs (venous disease, venous malformations, and superficial and / or deep venous thromboembolic disease).

Diagnosis and treatment of each of these three pathologies are standardized. Important therapeutic management issues occur when we have a patient with a history of vascular surgery (crossectomy and bilateral saphenous vein stripping) currently with deep venous thromboembolic disease. Imagistic investigations can detect the thromboembolic pathology cause of a venous malformation.

Congenital malformations of the veins and especially those of the inferior vena cava are clearly described in the literature. They are usually discovered by accident during imagistic examinations performed for other conditions. The literature reports that inferior vena cava malformations are present in a proportion of 0.3% to 0.5% among the general population and in a percentage between 0.6% and 2% among patients with other cardiovascular malformations. (2,3,4,5,6,7)

The most common are forking inferior vena cava and its presence on the left side of the body. (8,9,10,11)

Agenesis of the inferior vena cava is the rarest of congenital malformations of the vena cava and can be easily misdiagnosed.

This condition has an incidence of 0.0005% to 1% in the general population according to multiple studies and reports confirm its important role as a risk factor for deep vein thrombosis in young adults. (3,12,13,14,15)

According to some authors, among patients with deep venous thrombosis, agenesis of inferior vena cava prevalence rises to 5%. (2,16,17,18,19)

Case report

A 41-year-old patient was admitted to the IIIrd Emergency General Surgery Clinic of Bucharest University Emergency Hospital for bilateral post-thrombotic syndrome of the pelvic limbs. He had significant bilateral leg edema, dermatitis and also varicose ulcers in the right lower limb and functional impotence. (Fig. 1)

Clinical examination showed impressive local lesions: right leg edema, right leg painful to the touch, varicose veins of the lower limbs with bilateral superinfected varicose ulcers, bilateral postoperative scarring in the femoral trigon - after stripping of the saphenous veins bilaterally, scars on the right leg - post drainage phlegmon with hyperchromic skin, hyperkeratosis (Fig. 2)

It is difficult to properly render the visual aspect of the lesions on admission given that the image (Fig. 2) is taken after 10 days of treatment, up to this point, the patient was uncooperative.

Besides the signs and symptoms presented as grounds for admission, clinical evaluation highlights superficial collateral circulation in the abdomen and thorax, which guided the surgical team to the diagnosis of venous malformation (Fig. 3)

History of the patient revealed: morbid obesity, neglected

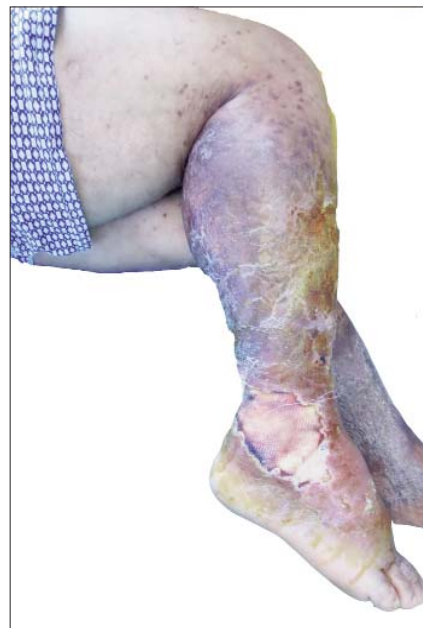

Figure 1. Lesional aspect after 10 days of treatment (lateral right view) (personal archive)

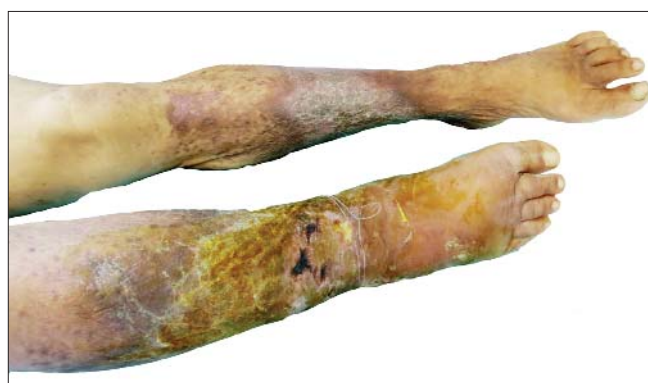

Figure 2. Lesional aspect after 10 days of treatment (frontal view) (personal archive)

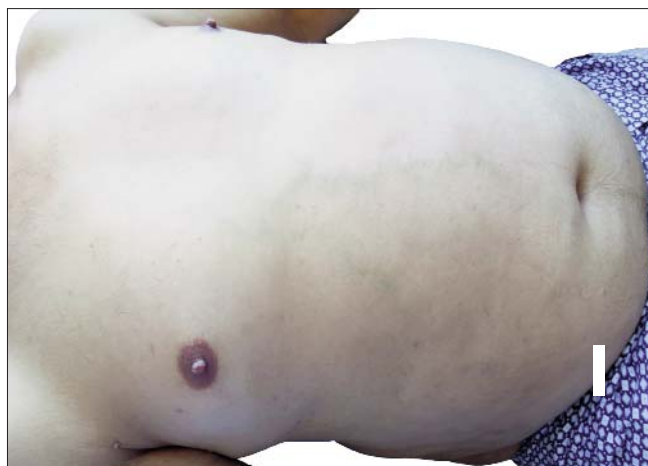

Figure 3. Colateral thoracic and abdominal superficial veins (personal archive)

type II diabetes, hypertension without treatment.

The history of surgical interventions is impressive because of the number and age (6 years old) at which the first surgery was performed. From the age of 4 when he had his first symptoms of varicose veins and until the admission in our clinic (2013), the patient underwent a series of four surgeries in the superficial venous system of the lower limbs, the first being represented by crossectomy and bilateral stripping of the saphenous vein, while the next three ones were treated and managed as recurrences. Imagistic investigations showed deep vein thrombosis: Doppler ultrasound highlighted no compressibility in right parietal and femoral popliteal vein, and the presence of intraluminal images typical for the existence of a thrombus that migrated from the popliteal vein to the right femoral vein, and also agenesis of the inferior vena cava detected on CT scans. (Figs. 4, 5, 6)

Management and results

It is legitimate to ask questions such as:

- What is the correct management of such a patient?
- Is there a standardized management?
- Does proper management involve the application of general standards or the clinician's ability to make good decisions?

In the case of our patient, initial treatment consisted in parenteral anticoagulation with unfractionated heparin, with a dose adjusted to achieve and maintain a therapeutic APTT. After five days the patient developed thrombocytopenia, therefore requiring replacement therapy with fondaparinux. After that we associated oral anticoagulants with a target therapeutic INR of 2-3.

Dynamic ultrasound performed didn't reveal regression of venous thrombosis, although the patient reached therapeutic

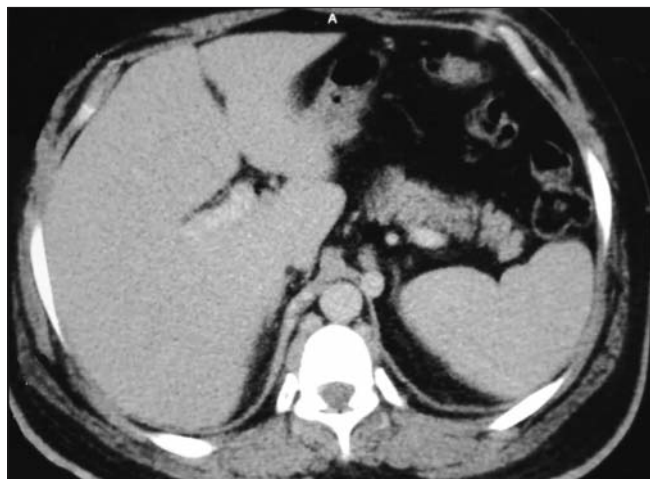


Figure 4. CT scan – axial plane (personal archive)

values of anticoagulation. For this reason we studied precipitating factors in a potential thrombophilia. Further investigations revealed the existence of a protein C deficiency and anticardiolipin antibodies.

Oral anticoagulant therapy in the correct dosage, associated to local management of ulcerative lesions (complicated by the presence of massive edema) led to a favorable local evolution.

Discussions

We consider it appropriate to discuss embryology:

- The inferior vena cava is the result of a complex embryological process that takes place between the 6th and 8th weeks of pregnancy. Three pairs of primitive veins (post-cardinal, subcardinal and supracardinal) are formed in this

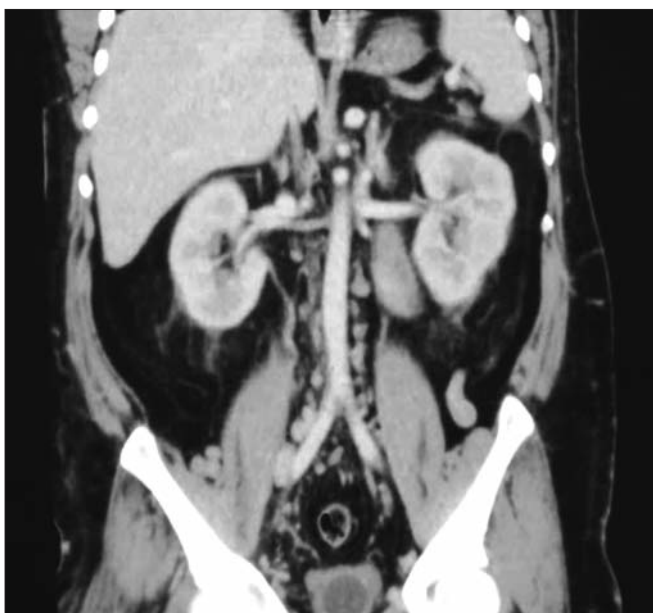

Figure 5. CT scan – coronal plane (personal archive)

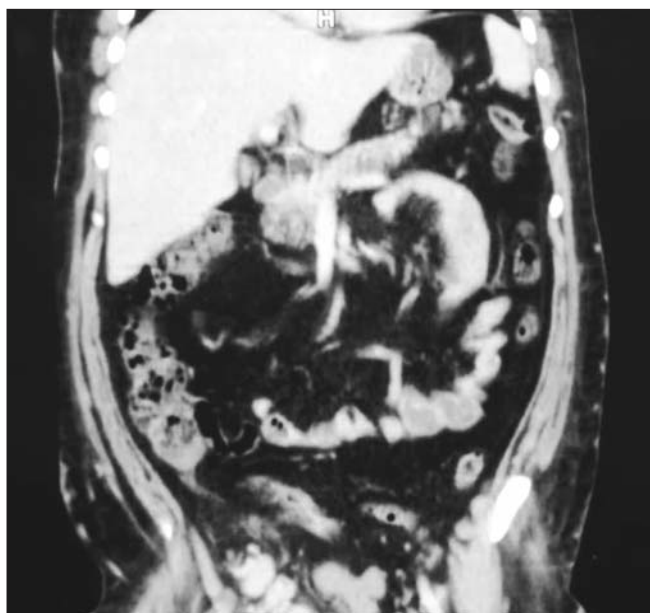


Figure 6. CT scan – coronal plane (personal archive)

order and form the four segments of the inferior vena cava: liver, adrenal, renal and infrarenal.

Agenesis of the inferior vena cava can occur in three different situations:

1. Absence of the suprarenal IVC results from failure to form the right subcardinal vein. The hepatic segment drains directly into the right atrium, and the blood from the infrarenal IVC returns to the heart through the azygos and hemiazygos veins. There is association with other cardiac and visceral anomalies, such as dextrocardia, atrial septal defect, atrioventricular canal, situs inversus, polysplenia, or asplenia. (20,21,22)
2. Absence of the infrarenal IVC with preservation of the suprarenal segment implies a failure of the development of the right supracardinal vein. (23,24,25)
3. Absence of the entire IVC, as in our patient's case, suggests that all three paired vein systems failed to develop properly, but it has no relation to the other congenital anomalies described previously. (3,7,9,13, 26,27,28,29,30)

The reasons for the developmental failure are unclear. One hypothesis is embryonic dysontogenesis, but some authors suggest that it is the result of an intrauterine or perinatal thrombosis.

Usually the pathology that we have presented in this paper is asymptomatic and diagnosed incidentally during abdominal surgery or certain imagistic tests for other diseases.

Under these conditions, in front of a patient in whom we accidentally discover a pathology such as agenesis of the inferior vena cava the question is: what is the right attitude?

Immediate response should, in our view, have three directions:

1. Recording a medical document and warning patients about the existing malformation;
2. Oral anticoagulant therapy;
3. Obligatory avoidance of risk factors for venous thrombosis: smoking, contraceptives for women, restraining or special physical activities.

If the agenesis of the inferior vena cava presents as first manifestation deep vein thrombosis, as it happened in our case, there are important issues of therapeutic management.

Particularities of the case are determined by the patient's genetics, complications occurred during evolution and therapeutic attitude developed from the first episode of venous pathology until now. A fact that we consider defining for the evolution of the case is that the clinical manifestations of venous pathology were present from an early age (4 years) and laboratory investigations have repeatedly confirmed the diagnosis of deep vein thrombosis.

Conclusions

- Agenesis of the inferior vena cava is a very rare condition, but misdiagnosed it can lead to postoperative major complications of patients who underwent surgery considered classically simple. Even if study of such malformations leads to significant use of financial

resources, however, we must not ignore the possibility that a patient who developed varicose veins of the lower limb without risk factors has agenesis of the inferior vena cava.

- The general assumption that agenesis of the inferior vena cava is a risk factor for deep vein thrombosis is sustained in our case by: agenesis in combination with other procoagulant factors (chronic venous stasis, poor venous return, venous hypertension due to the absence of main veins, thrombophilia presence).
- We believe that the diagnosis of agenesis of the inferior vena cava should be considered in young patients without risk factors with deep vein thrombosis.

References

1. Jecu Avram, Iulian Avram. Patologia chirurgicală a venelor. In: Popescu I, ed. *Tratat de Chirurgie*. București: Editura Academiei Române; 2008. p. 979.
2. Vasco PG, Ruedas López A, Laiño Piñeiro María and Gallego Rivera JI. Deep venous thrombosis caused by congenital inferior vena cava agenesis and heterozygous factor V Leiden mutation – a case report. *Int J Angiol*. 2009;18(3): 147-9.
3. Kuldeep Singh, James Poliquin, Guy Syversten and Douglas O Kohler. A rare cause of venous thrombosis: Congenital absence (agenesis) of the inferior vena cava. *Int J Angiol*. 2010;19(3): e110–e112.
4. Schneider JG, Eynatten MV, Dugi KA, Duex M, Nawroth PP. Recurrent deep venous thrombosis of the inferior vena cava and heterozygous factor V Leiden mutation. *J Intern Med*. 2002;252(3):276-80.
5. Yun SS, Kim JI, Kim KH, Sung GY, Lee DS, Kim JS, et al. Deep venous thrombosis caused by congenital absence of inferior vena cava, combined with hyperhomocysteinemia. *Ann Vasc Surg*. 2004;18(1):124-9.
6. Ruggeri M, Tassetto A, Castaman G, Rodeghiero F. Congenital absence of the inferior vena cava: A rare risk factor for idiopathic deep-vein thrombosis. *Lancet*. 2001;357(9254):441.
7. Obernoester A, Aschauer M, Schnedl W, Lipp RW. Anomalies of the inferior vena cava with iliac venous thrombosis. *Ann Intern Med*. 2002;136(1):37-41.
8. Chee YL, Cullighan DJ, Watson HG. Inferior cava malformation as risk factor for deep venous thrombosis in the young. *Br J Haematol*. 2001;114(4):878-80.
9. Körber T, Petzsch M, Placke J, Ismer B, Schulze C. Acute thrombosis of the deep leg and pelvic veins in agenesis of the renal inferior vena cava. *Z Kardiol*. 2001;90(1):52-7. German.
10. Bass JE, Redwine MD, Kramer LA, Huynh PT, Harris JH Jr. Spectrum of congenital anomalies of the inferior vena cava: cross-sectional imaging findings. *Radiographics*. 2000;20(3): 639-52.
11. Clayburgh DR, Yoon JD, Cipriani NA, Ricketts PA, Arora VM. Clinical problem-solving. Collateral damage. *N Engl J Med*. 2008;359(10):1048-54.
12. Salgado Ordóñez F, Gavilán Carrasco JC, Bermúdez Recio FJ, Aguilar Cuevas R, Fuentes López T, González Santos P. Absence of the inferior vena cava causing repeated deep venous thrombosis in an adult - a case report. *Angiology*. 1998;49(11):951-6.
13. Garcia-Fuster MJ, Forner MJ, Flor-Lorente B, Soler J, Campos S. Inferior cava malformations and deep venous thrombosis. *Rev Esp Cardiol*. 2006;59(2):171-5. Spanish

14. Simon RW, Amann-Vesti BR, Pfammatter T, Koppensteiner R. Congenital absence of the inferior vena cava: a rare risk factor for idiopathic deep-vein thrombosis. *J Vasc Surg.* 2006;44(2):416.
15. Takehara N, Hasebe N, Enomoto S, Takeuchi T, Takahashi F, Ota T, et al. Multiple and recurrent systemic thrombotic events associated with congenital anomaly of inferior vena cava. *J Thromb Thrombolysis.* 2005;19(2):101-3.
16. Galie N, Vasile R, Savu C, Petreanu C, Grigorie V, Tabacu E. Superior vena cava syndrome--surgical solution - case report. *Chirurgia (Bucur).* 2010;105(6):835-8. Romanian
17. Gil RJ, Pérez AM, Arias JB, Pascual FB, Romero ES. Agenesis of inferior vena cava associated with lower extremities and pelvic venous thrombosis. *J Vasc Surg.* 2006;44(5):1114-6.
18. Shah NL, Shanley CJ, Prince MR, Wakefield TW. Deep venous thrombosis complicating a congenital absence of the inferior vena cava. *Surgery.* 1996;120(5):891-6.
19. Timmers GJ, Falke TH, Rauwerda JA, Huijgens PC. Deep vein thrombosis as a presenting symptom of congenital interruption of the inferior vena cava. *Int J Clin Pract.* 1999;53(1):75-6.
20. Anderson RC, Adams P, Burke B. Anomalous inferior vena cava with azygos continuation (infrahepatic interruption of the inferior vena cava). Report of 15 new cases. *J Pediatr.* 1961;59: 370-83.
21. Dougherty MJ1, Calligaro KD, DeLaurentis DA. Congenitally absent inferior vena cava presenting in adulthood with venous stasis and ulceration: a surgically treated case. *J Vasc Surg.* 1996;23(1):141-6.
22. Sneed D, Hamdallah I, Sardi A. Absence of the retro hepatic inferior vena cava: what the surgeon should know. *Am Surg.* 2005;71(6):502-4.
23. May R, Thurner J. The cause of the predominantly sinistral occurrence of thrombosis of pelvic veins. *Angiology.* 1957; 8(5):419-27.
24. Gayer G, Zissin R, Strauss S, Hertz M. IVC anomalies and right renal aplasia detected on CT: A possible link? *Abdom Imaging.* 2003;28(3):395-9.
25. Fearon WF, Semba CP. Iliofemoral venous thrombosis treated by catheter-directed thrombolysis, angioplasty and endoluminal stenting. *West J Med.* 1998;168(4):277-9.
26. Nseir W, Mahamid M, Abu-Rahmeh Z, Markel A. Recurrent deep venous thrombosis in a patient with agenesis of inferior vena cava. *Int J Gen Med.* 2011;4:457-9.
27. Rosendaal FR. Venous thrombosis: a multicausal disease. *Lancet.* 1999;353(9159):1167-73.
28. Vucicevic Z1, Degoricija V, Alfrevic Z, Sharma M. Inferior vena cava agenesis and a massive bilateral iliofemoral venous thrombosis. *Angiology.* 2008;59(4):510-3.
29. Gayer G, Luboshitz J, Hertz M, Zissin R, Thaler M, Lubetsky A, et al. Congenital anomalies of the inferior vena cava revealed on CT in patients with deep vein thrombosis. *AJR Am J Roentgenol.* 2003;180(3):729-32.
30. Markel A. Origin and natural history of deep vein thrombosis of the legs. *Semin Vasc Med.* 2005;5(1):65-74.