

Multivisceral Echinococcosis: Concept, Diagnosis, Management

C. Grozavu, M. Iliș, D. Pantile

Department of Thoracic Surgery, "Carol Davila" Central Military Emergency University Hospital, Bucharest, Romania

Rezumat

Echinococoză pluriviscerală: concept, diagnostic, management

Introducere: Boala hidatică este în prezent într-o perioadă de recrudescență. În România frecvența afecțiunii se citează a fi în jur de 5-6 cazuri la 100.000 locuitori.

Material și metodă: În studiul de față abordăm problema echinococozii pluriviscerale, care în contextul general al bolii hidatice este o formă anatomo-clinică mai gravă, cu implicații în ceea ce privește diagnosticul, tratamentul, morbiditatea și mortalitatea. Am definit conceptul de echinococoză pluriviscerală și l-am diferențiat de echinococoză multiplă și de cea singulară. Etiologia echinococozii pluriviscerale este aceeași ca și în echinococoză singulară (monoviscerală), similar ciclul de viață al parazitului și stadiile lui de dezvoltare. În ceea ce privește patogenia bolii, analizând materialul clinic (84 cazuri de echinococoză pluriviscerală), am apreciat că există atât cazuri cu mecanism patogen primar (cele mai multe), cât și secundar, dar și cazuri în care mecanismul patogenic este incert.

Discuții: Diagnosticul afecțiunii, de cele mai multe ori stabilit tardiv, este relativ ușor de pus prin investigații clasice sau mai nou apărute (TC, RMN). Simptomatologia este mai zgomotoasă datorită numeroaselor semne și simptome date de localizările pluriviscerale sau multiple ale chisturilor și frecvența mai mare a asocierii cu alte afecțiuni. Este unanim apreciat că

tratamentul bimodal medico-chirurgical în echinococoză este atitudinea cea mai adecvată și cu rezultatele cele mai bune.

Concluzii: Dorim ca prezentarea de față asupra acestei afecțiuni să aducă un plus de informație în studiul bolii hidatice în general și al formelor pluriviscerale în particular.

Cuvinte cheie: echinococoză pluriviscerală, diagnostic, tratament

Abstract

Introduction: Hydatid disease is in a come-back period. In Romania the incidence is cited at 5-6 cases per 100,000 inhabitants.

Material and Method: In this study we define the concept of multivisceral echinococcosis, which is a more serious form of the hydatid disease with implications of diagnosis, treatment, morbidity and mortality. Multivisceral echinococcosis must be differentiated from multiple echinococcosis. The latter is defined as the localization of multiple hydatid cysts in the same organ. In case of multiple echinococcosis, we can describe double echinococcosis (two hydatid cysts located in the same organ), triple, etc. The etiology of multivisceral echinococcosis is similar to mono-visceral echinococcosis. Regarding the pathogenic mechanism, we appreciate that there are two distinct mechanisms: primary infection (most of them) and secondary infection.

Discussion: We propose a classification of multivisceral echinococcosis based on the anatomical compartment involved. The diagnosis of this condition is easy to establish using classic or more recent investigations (CT, MRI). Compared to mono-visceral echinococcosis, the symptomatology is louder because of

Corresponding author:

Constantin Grozavu, MD, PhD
Department of Thoracic Surgery
"Carol Davila" Central Military Emergency
University Hospital, Bucharest, Romania
E-mail: grozavuaxon@yahoo.com

the involvement of several organs and its association with different other conditions.

Conclusions: We wish this study to bring more information about hydatid disease, but especially about multivisceral echinococcosis.

Key words: multivisceral echinococcosis, diagnosis, treatment

Introduction

Concept of multivisceral echinococcosis

Although cases of hydatid cysts with multiple organ involvement have been described, we were not able to find an adequate definition of multivisceral echinococcosis in the literature. Bisson illustrated a diffuse hepato-pulmonary cystic hydatid disease in 1984 (1), while in 1978 Burdescu, in Romania, reported a clinical case of a child with multivisceral echinococcosis (both lungs and liver hydatid cysts) (2). We find it useful establishing a concept that defines multivisceral echinococcosis and guides the therapeutic management of multivisceral hydatid disease.

We define as multivisceral echinococcosis concept the simultaneous localization of hydatid cysts in more than one organ.

Multivisceral echinococcosis must be differentiated from multiple echinococcosis. The latter is defined as the localization of multiple hydatid cysts in the same organ. In case of multiple echinococcosis, we can describe double echinococcosis (two hydatid cysts located in the same organ), triple, etc.

A special remark regarding paired organs (lungs, kidneys): we consider simultaneous hydatid cysts in paired organs as multivisceral echinococcosis because, related to surgical intervention (anatomy, surgical approach and even tactical elements and techniques), cysts situated in paired organs are completely different from one another.

Material and method

The study was conducted in "Carol Davila" University Emergency Central Military Hospital, in the Thoracic Surgery Department, over 10 years. During this timeframe, 508 patients with cystic echinococcosis were identified; 84 of them were categorized, according to the definition stated above, as multivisceral echinococcosis. Our study represents the analysis of these 84 patients.

The sex distribution shows 38.09% (32 patients) female patients and 61.90% (52 patients) male patients (Fig. 1). The greater number of male patients is due to a more frequent contact with pests (dogs, wild animals, infected animal products, etc.).

We have encountered hydatid cysts in patients with ages

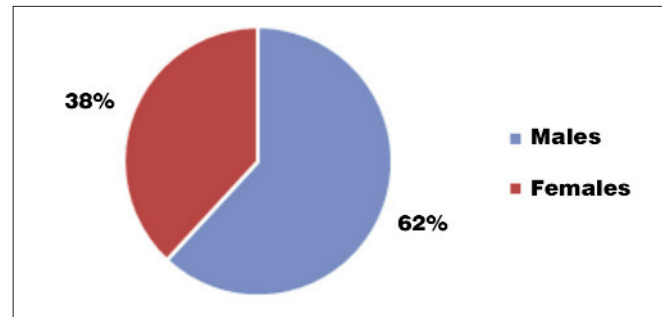


Figure 1. Patients with hydatid cysts, sex ratio

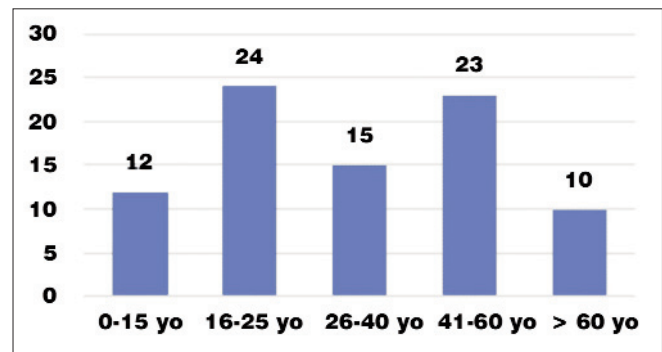


Figure 2. Patients' distribution according to age groups

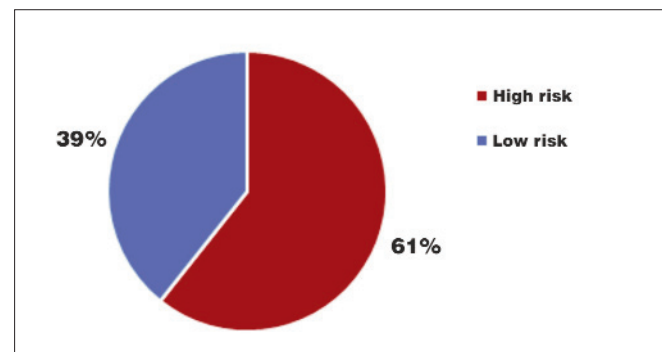


Figure 3. Patients' distribution according to their professional risk

varying from 6 year-old to 80 year-old (Fig. 2), with a peak incidence in patients aged from 16 to 60 year-old. A small percentage is encountered in children and elderly patients.

Regarding rural/urban patients' distribution, we had 57 patients (67.58%) living in rural areas, while only 27 patients (32.14%) lived in urban conditions.

Patients' occupation and their workplace (Fig. 3) are other important elements in multivisceral echinococcosis' epidemiology. We have encountered a higher percentage of patients with hydatid cysts (60.71%) among animal breeders, butchers, veterinarians, tanners, hunters, dog trainers, etc.

A relatively high number of patients without high-risk occupations (39.28%) can be explained by a growth of people owning pets, as well as their contact with infested pets.

Cystic echinococcosis localization

Hydatid disease can affect any part of the human body, no matter what organ, tissue or cavity. The most frequently affected organ is the liver.

In most studies, such as Tode et al. (1960), hepatic incidence is between 50-60%; Saidi (1976) reported an incidence between 70-80% (3,4).

The lungs are the second most frequent localization, as Barrett (1947) and Dew (1928) mentioned, with an incidence varying from 10-30% (5).

Considering liver and lung localization incidence, 10-15% with other localizations of the hydatid cysts remain (5). Among these rare locations of hydatid cysts, cardiac localization is cited with an incidence of 0.5-2% (Omer Tetik) (6,7), the left ventricle being the most frequent cardiac localization (55-60%), followed by the right ventricle with an incidence of 15%, interventricular septum (5-9%), left atrium (8%), pericardium (8%), pulmonary arteries (7%) and the right atrium (3-4%) (8). These values, mentioned by other authors, were also encountered in our study.

Brain involvement is more frequent in children (1-2%). Brain hydatid cysts are usually unique, localized within the grey matter, although some authors have described patients with multiple brain hydatid cysts (9,10)

Pancreatic involvement is extremely rare, with an incidence of 0.25% – 0.75% and occurs usually via hematogenous seeding, but also via pancreatic or bile ducts, as well as via the pancreatic lymphatic route. Preoperative diagnosis is very difficult because it can be mistaken for pancreatic pseudocyst, pancreatic cyst-adenocarcinoma, congenital or posttraumatic pancreatic cysts.

Other described localizations of the hydatid cysts are the spleen, kidney, peritoneum, genitals, muscles, bones, vertebrae, thyroid, adrenal gland, subcutaneous soft tissues, etc.

After the analysis of clinical material and studying all 84 cases of multivisceral echinococcosis, we have assembled a table which includes all the multivisceral locations of the hydatid cysts we have found (Table 1). For interpreting these data, we must consider that the study was performed in a thoracic surgery department, fact that explains the high frequency of lung hydatid cysts.

Table 1. Multivisceral localizations of the hydatid cysts studied

Localization	Patients	Frequency
Right and left lung	26	30.95%
Right lung and liver	20	23.80%
Left lung and liver	22	26.19%
Both lungs and liver	9	10.71%
Right lung and heart	1	1.19%
Both lungs, liver and spleen	1	1.19%
Left lung and spleen	1	1.19%
Left lung and heart	1	1.19%
Liver, spleen and pancreas	1	1.19%
Thoracic aorta, liver, spleen and kidneys	1	1.19%
Both lungs and heart	1	1.19%
Total	84	100%a

Pathogenesis

For multivisceral echinococcosis, several mechanisms are described; these mechanisms may lead to primitive multivisceral cystic echinococcosis or to secondary (metastatic) cystic echinococcosis.

Primitive cystic echinococcosis corresponds to a phase of the “great echinococcal cycle”, the phase in which parasites disposed by the definitive host reach the intermediate host (sometimes the intermediate host is human).

- The digestive system (hematogenous) is the most frequent way of infection. This represents a massive infection of the intermediate host's digestive system (including human), where the echinococcus embryophore, which covers the hexacanth embryo, is destroyed by the digestive secretions and the embryo is released.
- The lymphatic system is an alternative way for parasites to enter the lungs. This explains bilateral lung involvement with the absence of liver involvement. The embryo enters the lymphatic vessels of the small intestine, through the thoracic duct it enters the internal jugular vein, the right cavities of the heart and then reaches the lungs. Hepatic and extrahepatic venovenous (porto-caval) anastomoses represent another possible way of multivisceral infection with *Echinococcus granulosus*.
- The respiratory system is another way for lung infection with *Echinococcus granulosus*, sustained by several authors. On the other hand, Chrysopatis (1966) (3,11) states that it is uncertain if bronchial secretions can destroy the embryophore in order to release the hexacanth embryo. Other authors (Barrett, 1960) (5) reject the idea that the inhaled parasite could remain viable inside the bronchial tree.

Secondary multivisceral echinococcosis (metastatic) corresponds to the “small echinococcal cycle”. Protoscolexes released by a viable cyst from a primitive anterior infection, spontaneously or intraoperatively ruptured, lead to other organs' infection and will give birth to other hydatid cysts. This process can be realized by single or successive seeding, fact that explains different dimensions of the hydatid cysts. Several ways of secondary multivisceral echinococcosis are described.

- The direct path, which defines the spontaneous or iatrogenous rupture of a hydatid cyst inside a natural cavity (abdomen, thorax), may lead to secondary peritoneal or pleural echinococcosis. A particular aspect is the rupture of a hydatid cyst developed in the hepatic dome (8th segment) inside the pleura, with a bilio-bronchial fistula.
- The hematogenic path is another way of developing secondary multivisceral echinococcosis. This happens when a hydatid cyst localized inside an organ ruptures into a blood vessel and thus can spread anywhere inside the body (vena cava – cyst localized in the liver; pulmonary artery – cyst localized in the heart; aortic wall hydatid cyst – aortic-cystic fistula with multiple

intra-abdominal seeding: liver, spleen, kidneys, pancreas, etc).

- The ductal path represents yet another way of developing secondary multivisceral echinococcosis. It involves the rupture of a lung hydatid cyst into the bronchial tree and massive secondary lung dissemination. Similar, the rupture of a liver hydatid cyst into the bile ducts, with a cystic-bile fistula, is described.

For most of the 84 patients studied (76, 90.48%) we identified a primary pathogenic mechanism (see Table 2). We also found four patients with secondary pathogenic mechanism (4.76%) and other four patients with an uncertain pathogenic mechanism.

We correlated the organ's association frequency with the pathogenic mechanism. The most frequent association was found to be right lung – left lung (30.95%), mainly because the study was performed in a thoracic surgery department. Multivisceral echinococcosis in this association is realized through a primary pathogenic mechanism, meaning that the infection of both lungs and the development of hydatid cysts was simultaneous (at least four cysts of similar size are needed in order to certify this pathogenic mechanism).

From a pathogenic point of view, multivisceral echinococcosis can be a primary phenomenon – simultaneous infection of several organs from an outside source (90.48% in our study), or a secondary phenomenon – simultaneous infection of several organs from one or more primary sites (4.76% in our study). Sometimes it is impossible to differentiate the two pathogenic mechanisms: in our study 4.76% of patients remained with an uncertain pathogenic mechanism.

Multivisceral echinococcosis – classification (by localization)

Based on the analysis of multivisceral localization on studied patients and literature data, we have built a classification of multivisceral echinococcosis according to the two big compartments (thoracic and abdominal) and organs affected. This classification is schematically represented below (the numbers in brackets indicate the number of patients from our study).

- A. According to involved compartments
- Same compartment:

Table 2. Patients' distribution according to multivisceral echinococcosis' pathogenic mechanism

Pathogenic mechanism	No. of patients	Percentage
Primary multivisceral echinococcosis	76	90.48%
Secondary multivisceral echinococcosis	4	4.76%
Multivisceral echinococcosis with uncertain pathogenic mechanism	4	4.76%
Total	84	100%

- ♦ abdomen: (1)
 - o liver;
 - o spleen;
 - o kidneys;
 - o pancreas.
- ♦ thorax: (29)
 - o lungs;
 - o heart;
 - o great vessels.
- different compartments:
 - o abdomen + thorax; (54)
 - o abdomen + head;
 - o thorax + head.

B. According to the involved organs:

- Right lung + Liver (20)
- Left lung + Liver (22)
- Right lung + Left lung (26)
- Right lung + Left lung + Liver (9)
- Left lung + Spleen (1)
- Right lung + Heart (1)
- Left lung + Heart (1) – Fig. 4 A, B, C
- Liver + Spleen + Pancreas (1)
- Right lung + Left lung + Liver + Spleen (1)
- Right lung + Left lung + Heart (1)
- Thoracic aorta + Liver + Spleen + Kidneys (1)

Of course, the localizations of human multivisceral echinococcosis depend on the services addressing this pathology. The Thoracic Surgery department of Central Military Emergency University Hospital had, from a total of 508 patients with hydatid cysts over a 10-year time interval, 84 patients with multivisceral echinococcosis (16.53%).

We found 29 patients (34.52%) with multivisceral localization inside the thoracic compartment only, 54

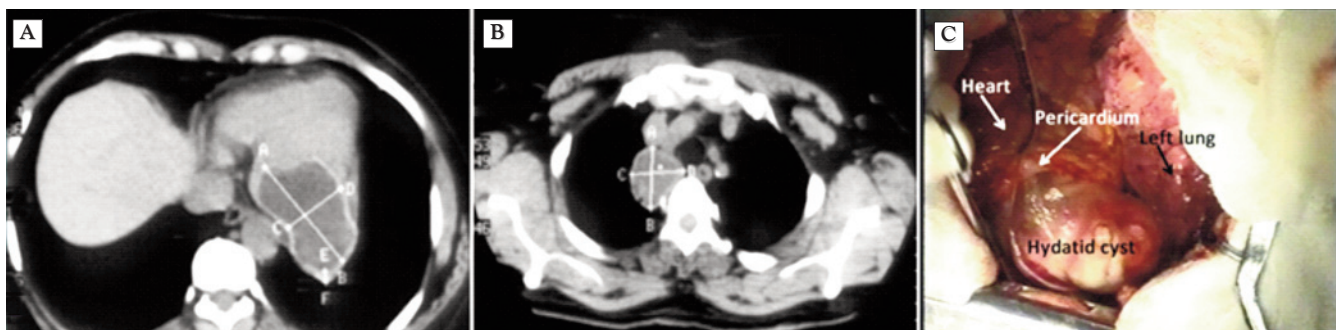


Figure 4. (A) CT – hydatid cyst localized at left myocardium level; (B) CT – hydatid cyst of left lung (anterior segment, left superior lobe); (C) Intraoperative aspect – hydatid cyst localized at left myocardium level

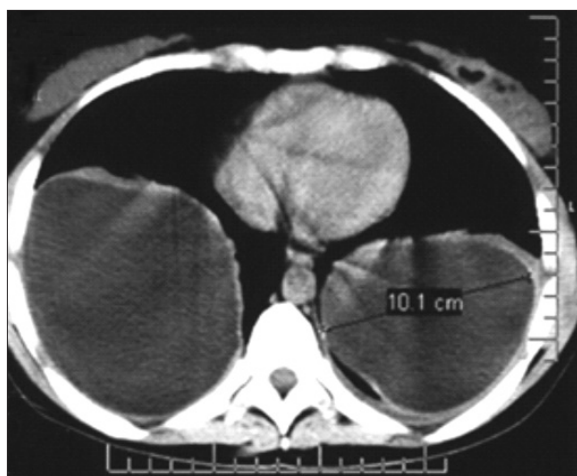

Figure 5. Chest CT showing bilateral hydatid cysts

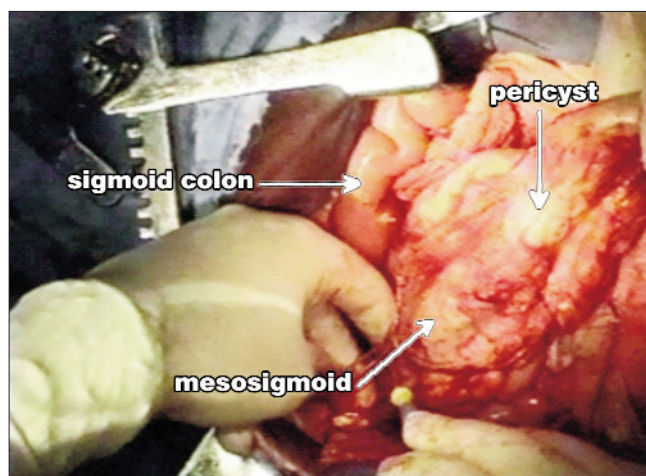


Figure 6. Intraoperative aspect - hydatid pericyst dissection from mesosigmoid

patients (64.28%) with multivisceral localizations inside the thoracic and abdominal compartments and only one patient (1.19%) with abdominal multivisceral echinococcosis.

The most affected organs were lungs (97.61%), liver (64.28%), spleen (4.7%), heart (3.57%) and thoracic aorta, pancreas, kidneys with 1.19% each.

The most frequently observed multivisceral associations were right lung – left lung (Fig. 5) (30.45%), left lung – liver (26.19%), right lung – liver (23.88%), right lung – left lung – liver (10.71%). Other associations were singular cases (Fig. 6).

Diagnosis

In multivisceral echinococcosis, we find the same pathogen as in simple cystic echinococcosis: *Echinococcus granulosus*. During its life cycle, the human represents an intermediate host in which only the larva develops, the hydatid cyst, localized in several organs or structures.

On the studied patients (84), we identified several circumstances in which the diagnosis of multivisceral echinococcosis was set (Table 3). We highlight the great number of respiratory symptoms (48 patients), followed by digestive symptoms (22 patients). We had 12 asymptomatic patients; in this case, the diagnosis was set after screening X-ray exams. For two patients, allergic symptoms were the first signs of hydatid disease; complementary paraclinical investigations set the final diagnosis of multivisceral echinococcosis.

Table 3. Circumstances under which multivisceral echinococcosis was diagnosed

Circumstances	Patients	Percentage
Standard X-ray	12	14.28%
Respiratory symptoms	48	57.14%
Digestive symptoms	22	26.19%
Allergic symptoms	2	2.38%

There are no specific methods to diagnose multivisceral echinococcosis. Instead, all classic imaging techniques (standard X-ray) or recent imaging techniques (ultrasonography, computed tomography, magnetic resonance, fiber bronchoscopy), in various associations, are of great utility, replacing more invasive maneuvers (bronchography, scintigraphy).

Until the development of modern investigation techniques (computed tomography, MRI), the standard chest X-ray was the only investigation suggesting a thoracic hydatid cyst.

The standard chest X-ray is very useful and it can suggest by itself the diagnosis of pleuro-pulmonary echinococcosis. A round or oval opacity, of sub-costal intensity is described. According to evolutionary stage of the hydatid cyst, the radiological aspect is described as polymorphic.

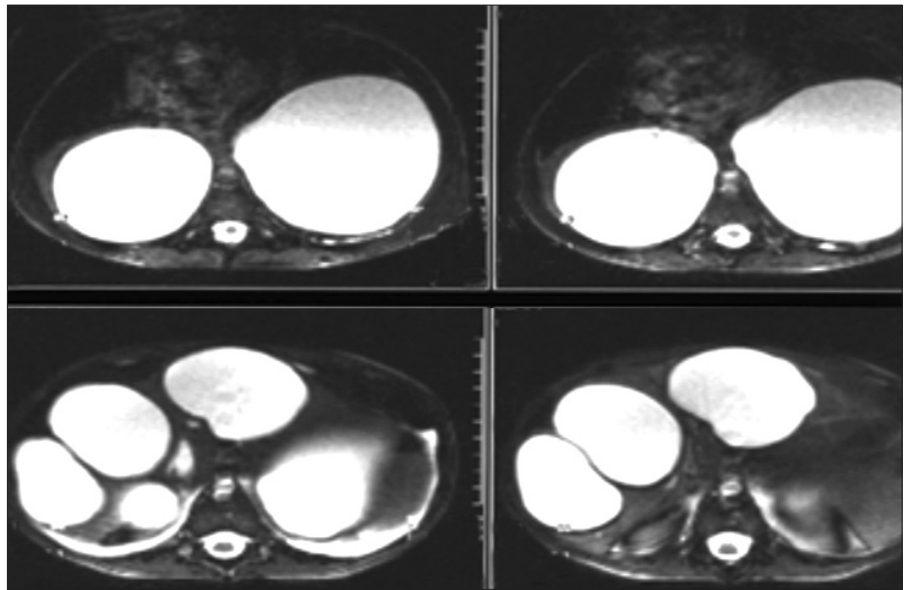
The introduction of computed tomography in the diagnosis of multivisceral echinococcosis brought immense advantages. Computed tomography is useful in certifying multivisceral echinococcosis diagnosis, differential diagnosis and postoperative surveillance.

The CT scan shows round or oval well-defined areas of homogenous hypo density, with values of 0-15 HU (liquid density). It reveals multivisceral localization of hydatid cysts in areas inaccessible to standard X-ray, the structure of adjacent parenchyma, as well as its mass effect over these structures (displacement, compression, impression, etc.). As with the ultrasound, the CT exam can establish the evolutionary stage of the hydatid cyst (Khannos, 1993).

The CT protocol describes a round or oval opacity, delimited by surrounding parenchyma, with liquid intensity and the possibility to visualize the hydatid membrane, without mediastinum or hilum masses (Fig. 7).

During the 1970's, ultrasound techniques join the echinococcosis' diagnostic methods. This method, based on ultrasound, is completely non-invasive, becoming the most used investigation for diagnosis and monitoring patients with echinococcosis. All the studied patients had ultrasound investigation before and after surgery. Ultrasound is useful to define the cysts' internal structure, the number,

Figure 7. CT scan – multivisceral echinococcosis: liver and bilateral lung hydatid cysts (6 year-old child)



localization, as well as to identify any possible complication. The specificity of ultrasound is close to 90% (12).

Proposal of diagnosis algorithm

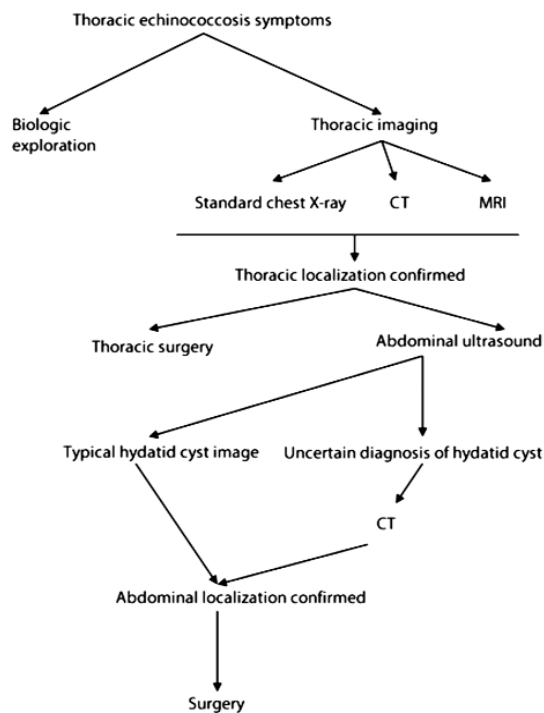
Considering the relatively frequent possibility of multivisceral echinococcosis, finding the hydatid disease in one organ entails searching other sites for hydatid cysts, at least inside the abdominal and thoracic compartments. Based on literature

data and personal findings, we propose a diagnosis algorithm for multivisceral echinococcosis involving thoracic and abdominal compartments (see diagnosis algorithms 1 and 2).

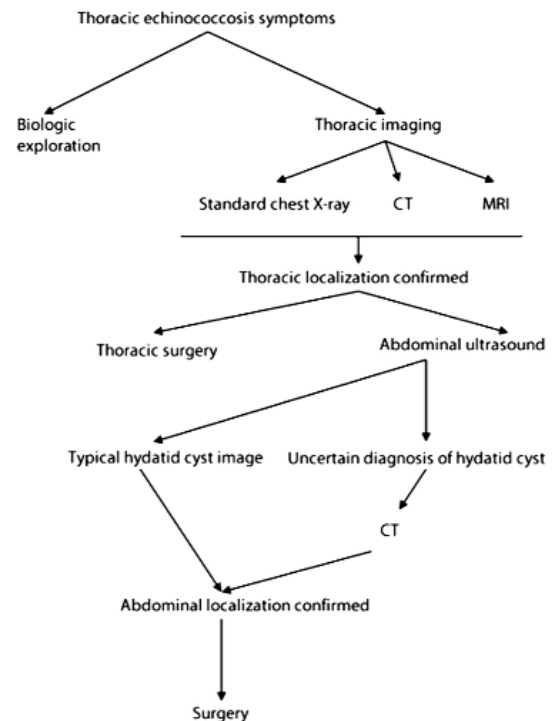
Multivisceral echinococcosis diagnosis algorithm

1. from thorax to abdomen (algorithm 1)

2. from abdomen to thorax (algorithm 2)



Algorithm 1.



Algorithm 2.

Multivisceral echinococcosis - treatment

Medical treatment (chemotherapy) with benzimidazol-like drugs has indication for multivisceral echinococcosis perioperatively or between seriate surgeries (13,14).

We do not recommend medical treatment as first therapeutic step because it could lead to serious complications, like suppurations with lung parenchyma destruction. Drug therapy has a certain curative effect on cysts smaller than two cm. Our patients did not have any relapses after medical treatment.

Surgical treatment of human echinococcosis is based on conservative (salvaging as much tissue or parenchyma as possible) or more aggressive procedures (removing more tissue or parenchyma along with the cyst).

The objectives of surgical treatment are intact removal of the parasite (when possible), treatment of the remaining cavity and associate lesions, and treatment of complications.

Surgical treatment of multivisceral sites can be simultaneous (same surgical intervention) or successive (separate surgical interventions). Simultaneous attack is achieved through a common surgical approach (if the cysts are close to one-another) or through separate surgical incisions (if the cysts are located in different organs). In our study, simultaneous attack through a common surgical approach has been practiced for six patients (right thoracotomy and right phrenotomy – 5; left thoracotomy and left phrenotomy – 1). Simultaneous approach through separate surgical incisions has been practiced for two patients (simultaneous bilateral thoracotomy – 1; left thoracotomy and median laparotomy – 1). All the other 76 patients have been approached through successive surgical interventions (seriate surgery).

Regarding the order of surgical interventions in multivisceral echinococcosis, this is set by several priorities. We have developed a priority algorithm regarding this order.

First priority is the surgical treatment of complicated cysts (infection, fistula, hemorrhage) no matter their localization. The second priority are uncomplicated cysts with thoracic localization because any general anesthesia can rupture the hydatid cysts with secondary pulmonary infection. Finally, the third priority is the size of the cyst – larger cysts will be removed before smaller cysts.

We recommend classic surgery with maximum sparing of parenchyma.

Treatment for lung hydatid cysts in multivisceral echinococcosis

Since this study was performed in a thoracic surgery department, most cases of multivisceral echinococcosis (97.61%) presented with lung hydatid cysts.

Throughout the years several procedures of complete and intact removal of the parasite from the lung have been described. Dubau recommends the intact removal of the hydatid cyst by approaching it at the most superficial level, accessing the space between cyst and pericyst (15,16). Hugon

sectioned the pericyst at the lung – pericyst junction, through the space between cyst and pericyst. Coman approaches the cyst through the lung parenchyma, digitally dissecting the cyst (17). Perez Fontana approaches the cyst through a space considered avascular (false), between the cyst and the pericyst. We have rarely utilized the above procedures, under maximum safety conditions and only for very superficial cysts (Hugon procedure). The most utilized procedure for eliminating the hydatid cysts are those applied after the evacuation of the hydatid fluid. The evacuation is performed with a special device, using a closed system, without any chances of contamination. Partial or complete removal of the hydatid liquid can be performed slow or fast, using the methods described by several authors (Finochietto, Arce, etc.).

After the removal (complete or partial) of the hydatid liquid, a parasiticide solution is used in order to inactivate the remaining hydatid liquid or the hydatid fertile elements, followed by a cystotomy (pneumotomy) and the extraction of the hydatid membrane.

After the hydatid removal, the remaining cavity must be adequately treated in order to prevent the onset of complications (suppuration, lung abscess, etc.). Any surgical treatment used must promote the aeration of the adjacent lung parenchyma.

Dor procedure (capitonnage of the residual cavity)

The original method resolves the residual cavity by controlling the remnant cystic cavity (multistory bursae), from inside out. The closure of the identified bronchial fistulae with slowly absorbable sutures (2/0 or 3/0 Maxon® or 2/0 Dexon®) has been added to the original procedure. After the lung is inflated, the bursae are closed. We do not use “X” or “U” sutures because they can disorganize the pericyst near the fistula, thus enlarging the fistula (Figs. 8, 9).

Another type of capitonnage is performed after the “valley principle”, which uses successive bursae instead of multistory bursae (18,19).

In our study the most frequent procedure was Dor capitonnage, with 57.39%, followed by the capitonnage according to “valley procedure”. This procedure (Dor capitonnage) is the most adequate and most efficient method for the majority of cases, without any major postoperative complications.

GGerulanos drainage is more often performed lately. In our clinic, Prof. Dr. Horvat actualized the method (18,20). The original procedure consisted of pneumopexy (lung attachment to the margins of the thoracotomy) and the cavity's drainage with a tube (the pneumotomy's margins were fixed to this tube). There is no mention regarding the bronchial fistulae. The alterations brought to this procedure by Prof. Dr. Horvat consisted of bronchial fistulae closure with absorbable sutures (2/0 or 3/0 Maxon® or 2/0 Dexon®), followed by suturing of the lung parenchyma and drainage of the remaining cavity with a 5 mm diameter drainage tube, attached to the remaining cavity. The drainage tube is externalized through an intercostal space, above or under the thoracotomy, leaving about 10 cm of its length inside the thoracic cavity (between the lung and the thoracic

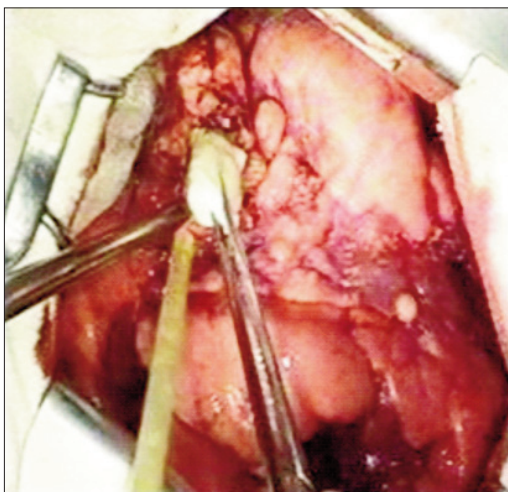


Figure 8. Intraoperative aspect – cystotomy, evacuation of the proligerous membrane

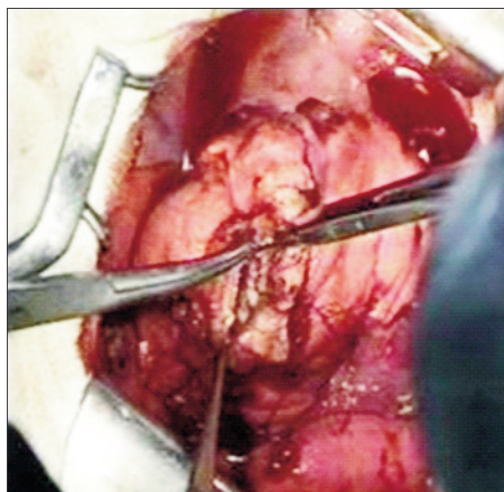


Figure 9. Intraoperative aspect – capitonnage of the residual cavity

wall) and connected to a B  cl  re passive drainage system.

Posadas-C  rpin  san extensive pericystic resection procedure involves the resection of the pericyst until its limit with lung parenchyma. The residual cavity is abandoned on the lung parenchyma in order to solder with parietal pleura (flat cystectomy) (18,20). The closure of bronchial fistulae is mandatory. The pleural cavity must be actively drained. This procedure is often utilized for big, peripheral cysts with huge bronchial fistulae. There is a high risk of complications, such as lung suppuration. We have seldom used this procedure because of its high risk of complications. Horvat, 1997, (20) recommends this procedure for cysts exposed for more than 2/3 of their surface, with big bronchial fistulae, for big cysts in young patients with elastic lung parenchyma and for big cysts exposed at least for half their surface at lung fissures' or mediastinal level, with high vascular and bronchial risks.

Juvara procedure

The Juvara procedure consists of pericystectomy with closure of the bronchial fistulae using a muscular flap (from intercostal muscles).

Surgical lung excisions have been recommended for several hydatid cysts. We performed pulmonary wedge resections for peripheral hydatid cysts. When the hydatid cysts occupied a full lung segment, or when the infection had not expanded beyond segmental plane, typical segmentectomy has been performed. If the size or number of hydatid cysts were extended to a full pulmonary lobe, lobectomy has been performed. Pneumonectomy is seldom appropriate for hydatid cysts surgical treatment. Its indications are special and are linked with the suppurated suppurate process (lung destroyed by suppuration) or with intraoperative accidents.

Surgical treatment for hepatic localization in multivisceral echinococcosis

In our study, hepatic localization is the second most frequent

localization of hydatid cysts. Of all 84 patients, 54 (64.28%) had liver hydatidosis. The associations of liver hydatidosis with other localizations are illustrated in *Table 4*.

Despite new methods of hydatid cyst treatment having been developed (medical treatment, minimally invasive treatment), the classical surgical treatment remains the most reliable "weapon" to fight with against multivisceral echinococcosis. The objectives for liver surgery are the same as for lung hydatid cysts: parasite removal, residual cavity treatment and treatment of the complications.

Conservative surgical treatment

Conservative methods involve saving the pericyst (residual cavity) after extracting and removing the parasite. These techniques are used for patients with high surgical risk: localization of hydatid cyst is hard to access, patient's comorbidities contraindicates the surgical intervention, etc.

1. PAIR/PAI This procedure consists of puncture (P), aspiration (A), injection of parasiticide agent (I), re-aspiration or reinjection (R). It can be applied through percutaneous approach, minimally invasive, or through open surgery.
2. External drainage of pericystic cavity History kept the "marsupialization" of the hydatid cyst as the oldest treatment for hydatid cysts. It consists of a large external

Table 4. Multivisceral echinococcosis with liver hydatid cysts

Multivisceral echinococcosis	No. of patients
Liver and lungs (bilateral)	9
Liver, spleen and lungs (bilateral)	1
Liver and right lung	20
Liver and left lung	22
Liver, spleen and pancreas	1
Liver, thoracic aorta, spleen	1
Total liver hydatid cysts	54
Total patients	84

drainage of the remaining cavity, after the cyst is fixed to the abdominal wall. The most important drawbacks of this procedure are secondary infection, obstruction of remaining cavity's collapse, prolonged postoperative bile drainage. This procedure also favors the transformation of the remaining cavity in an infected abscess with delayed healing. Other external drainage procedures: cystotomy with the evacuation of the parasite, bipolar approach of the common bile duct and of the remaining cavity (21), Oddi sphincterotomy, trans-coledochal drainage of the remaining hepatic hydatid cavity.

3. Internal drainage of the hepatic hydatid cyst. This type of procedure, which completely preserves hepatic parenchyma, wants to create a direct anastomosis between the pericyst and the digestive tube, granting an internal drainage of the remaining cavity. The main indications for this procedure are complicated hydatid cysts (hydatid cysts with a bile fistula externalized on the inferior side of the liver).

Radical surgical treatment – surgical techniques for complete or partial pericyst removal

Reduction procedures, through which the pericyst is partially removed can be a simple “unroofing” procedure or a wider resection of the pericyst. The “unroofing” procedure carries the name of Lagrot (22), who proposed it under the name of “resection of the projecting dome” and has indications for exteriorized hydatid cysts of the liver, without any bile fistula in the remaining cavity.

Juvara (23) describes a procedure we also utilized, partial pericystectomy and tunneling of the remaining cavity over a drainage tube, reducing the hepatic cavity. This tunneling procedure can be performed through the invagination of the cavity's margins or through a multistoried suture (capitonnage) of the remaining pericyst, while leaving a drainage tube inside the profound plane (Guedj, 1967).

Extended maximal pericystectomy [D. Sabău (24)] involves the almost complete resection of the pericyst, leaving only a small chip of the pericyst on the liver's surface, with hemostasis and closure of all bile fistulae. In case of a bigger chip of remaining pericyst, the surgery can be finalized through a circumferential suture or through complete obliteration of the remaining cavity with multistoried sutures, without a drainage tube.

Ideal cystectomy is possible only with open surgery and can be performed without opening the cyst (Napalkov), or after its opening and evacuation. In both situations, the pericyst is dissected from the liver, imposing hemostasis and bile fistulae closure.

Atypical hepatectomy and regulated hepatectomy are rarely indicated in liver echinococcosis, being reserved for patients with massive destruction of liver parenchyma, for multiple cysts or for giant cysts that suppress a complete liver territory.

Transdiaphragmatic approach of the hepatic dome hydatid cyst at the same operative time (simultaneous) with the right

lung hydatid cysts (or eventually left lung) is indicated only if the hepatic cyst is not complicated with a bile fistula or with infection.

The localization of hydatid cysts is possible in any organ and, in some cases, requires a multidisciplinary approach.

Minimally invasive surgical treatment

Minimally invasive surgical treatment is gaining more and more support lately, especially for multivisceral echinococcosis in patients with great risks for open surgery. Minimally invasive surgery requires a special technique and special instruments. The most utilized methods are PAIR (Punction, Aspiration, Injection, Re-aspiration), thoracoscopic procedures, video assisted thoracic surgery (VATS), laparoscopic surgery, ERCP (endoscopic retrograde colangiopancreatography).

Updates of the Lamas-Mondino procedure for multivisceral echinococcosis with lung involvement

In the context of minimally invasive treatment for multivisceral echinococcosis with lung involvement, we have updated an older procedure, its alterations being possible because of the newly medical advances. We will not describe the original procedure, but the modified, updated one. The updates proposed were very well received by the patients, with an excellent postoperative evolution.

We will briefly describe the operative steps. The approach is through an antero-lateral thoracotomy at the 6th intercostal space level, with the resection of the anterior arch of the 6th rib (5 cm in length). The pleural space is blocked and a large tumor with cystic characteristics is identified. The tumor has close relations with the thoracic wall and with the medium and inferior lobes of the right lung. The cyst is punctured, evacuated, inactivated with alcohol and minimal pericystectomy is performed. Multiple daughter vesicles, in various sizes, are being extracted. After complete evacuation and abundant lavage of the residual cavity, the thoracoscope is introduced inside the cavity, and an important bronchial fistula, approximately 1.5 cm in diameter, is identified. Through this fistula multiple daughter vesicles were engaged. The bronchial fistula is sutured. In the end we performed hemostasis and no air leakage was identified. The inspection of the cyst and diaphragm does not emphasize any other sub-diaphragmatic cyst or any path of trans-diaphragmatic communication. The cystic cavity is drained with a single drainage tube, through cystotomy (a la Gerulanos). This procedure, updating the old Lamas-Mondino procedure, obtained a minimally invasive approach for the relapsed hydatid cyst by utilizing modern thoracoscopic techniques. The patient benefited from this procedure by having a reduced hospitalization time and a fast social and professional reintegration.

Perioperative morbidity and mortality

It is normal for patients with multivisceral echinococcosis to develop a higher postoperative morbidity rate than patients

with monovisceral echinococcosis, by summing the complications resulted from multiple approaches.

Multivisceral echinococcosis also has a higher morbidity rate. For our studied patients, the perioperative mortality rate was of 3.57% (3 out of 84 patients). 2 patients had septic complications and one patient had an important hemorrhage from a hydatid cyst of the thoracic aorta.

Discussions

The literature contains many references regarding the localization of hydatid cysts, but we are yet to find a study about multivisceral echinococcosis regarding the symptoms, diagnosis and its complex treatment. In Romanian medical literature many authors described their experience regarding the various localizations of multivisceral echinococcosis (25,26,27,28,29).

Doran et al. described a patient with multivisceral echinococcosis with liver and pelvic localization and presented a surgical technique adapted to this case, while insisting on presenting the complications of the residual cystic cavity (25).

Rare localizations of the hydatid cysts for which pathophysiologic explanations are uncertain, including the diaphragm (26), the anterior mediastinum (27), the gluteus maximus muscle (28), or the antero-lateral thigh (29) were presented over time.

Prousalidis et al. (1998) (30) present rare localizations of the hydatid cyst in the Mediterranean area. Between 1967 – 1994, other localizations than the liver and lungs were described in 49 patients. 28 males and 21 females were included in that study, aged between 10 and 80 year-old. Among these patients, 25 had peritoneal hydatid cysts, 10 had splenic hydatid cysts, 5 had renal hydatid cysts, 3 had vertebral hydatid cysts, 2 had abdominal wall hydatid cysts, one had a cardiac hydatid cyst and another one had a thoracic wall hydatid cyst. The hospitalization time varied from 9 to 88 days, with an average of 27 days. Only two patients, one with vertebral echinococcosis and another one with cardiac echinococcosis, have died. Three patients with multiple peritoneal echinococcosis and one with abdominal wall echinococcosis had relapses and required another surgical intervention. None of them had another relapse.

Macedo Aj. et al. (1997) (31) describe a rare case of cardiac hydatid cyst. An 11 year-old child with history of abdominal pain, admitted in pediatrics for a prolonged systolic murmur, is diagnosed with a tumor located at the right ventricle level. The MRI performed reveals a multilobulate tumor with cysts inside and another cyst in the right pulmonary artery. ELISA performed for hydatid cyst was positive. The patient underwent surgery and both cysts were removed. Postoperatively he was administrated albendazole drug therapy.

Atilgan (1996) (32) describes an unusual case of cardiac hydatid cyst (left ventricle) with multivisceral involvement. In this case, the trans-esophageal ultrasound brings new information and confirms the diagnosis proposed by the trans-thoracic ultrasound.

Grozavu et al. (2000) (33) describe a very rare case of primary echinococcosis of the thoracic aorta with multiple

intra-abdominal secondary localizations: liver, spleen, pancreas, pelvis and peritoneum. The patient's evolution was unfortunate due to an aortic-cystic-pulmonary fistula with a massive hemothorax and hemoptysis.

Atan et al (1997) (34) describe a rare case of renal hydatid cyst, while Giordano G. (1995) describes a case of bilateral renal multiple hydatid cysts which associates cerebral and splenic cysts after a rupture of a cardiac hydatid cyst. These authors highlight the rarity of the renal localization of hydatid cysts and explain the dissemination of echinococcosis. They also explain the role of preoperative CT examination.

Conclusions

The pathogen of multivisceral echinococcosis is the same agent as for single-organ echinococcosis: *Echinococcus granulosus*. During its lifecycle, humans are intermediate hosts in which only the larva, the hydatid cyst, with different localizations, develops. We have defined multivisceral echinococcosis as the simultaneous localization of the hydatid cysts in more than one viscera. We have differentiated it from multiple echinococcosis, which means multiple localizations of the hydatid cysts inside the same viscera. We consider simultaneous involvement of pair-organs (lungs, kidneys) as multivisceral echinococcosis, using the definition stated above.

Pathogenically speaking, multivisceral involvement can be a primary or secondary phenomena. Sometimes the difference between pathogenic mechanisms can be impossible to reveal.

Regarding multivisceral echinococcosis in humans, the localization of the hydatid cysts depend on the specific service the patient is admitted in. We had multivisceral echinococcosis affecting exclusively the thoracic or the abdominal compartment. The most frequently involved organs were: lungs, liver, spleen, heart, thoracic aorta, pancreas, and the kidneys. More frequent multivisceral associations were: right lung – left lung; left lung – liver; right lung – liver.

Regarding the diagnostic methods we have stated that there is no specific diagnostic method for multivisceral echinococcosis. Nevertheless, all imaging methods, older (standard X-ray) or more recent (ultrasound, CT, MRI) are of great utility, replacing more invasive procedures like bronchography, scintigraphy, etc. Having in mind the relatively frequent multivisceral echinococcosis we suggest that the identification of a hydatid cyst imposes the search for hydatid cysts inside other organs. Based on personal experience and literature data, we have compiled a diagnosis algorithm for multivisceral echinococcosis involving the thoracic and abdominal compartments.

Medical treatment with drugs benzimidazol-like is appropriate for multivisceral echinococcosis, but we do not recommend it as the first therapeutic step. The usage of drugs as the first therapeutic step may lead to serious complications: supuration with parenchymal distraction. Medical treatment as single therapy has curative effect only on cysts less than 2 cm in diameter. We did not encounter any relapses after medical treatment in studied the patients.

The surgical treatment of multivisceral echinococcosis

can be simultaneous (in a single surgical intervention) or successive (separate surgical interventions). Simultaneous attack can be accomplished through a single approach (neighbouring locations) or through separate approaches (distant locations). Regarding the order of surgical interventions, we have established that it is determined by several priorities, as stated above.

The surgical procedures we recommend for multivisceral echinococcosis are classic procedures, with minimal loss of visceral parenchyma.

Minimally invasive surgical treatment, with its technical variations, has certain indications for multivisceral echinococcosis, lowering the impact of surgical aggression needed for multiple localizations. For certain pulmonary localizations we have proposed a personal minimally invasive procedure, derived from the cystotomy in pleural symphysis – Lamas-Mondino procedure.

Among the studied patients, the mortality was of 3.57%, as stated above.

Because it raises a series of specific problems of etiology, surgical strategy and tactics, multivisceral echinococcosis should be regarded as a distinct chapter inside “hydatology”, justifying research by each surgical specialty involved in the treatment of multivisceral echinococcosis.

References

1. Bisson A, Abbas M, Colchen A, Leroy M, Personne C, Toty L. Diffuse hepato-pulmonary hydatidosis. Apropos of a case. *Sem Hop.* 1984;60(11):798-800. French
2. Burdescu C, Singer I, Achimescu G, Ionescu D, Tender V, Diaconu I. Hydatid cysts of plurivisceral localizations in a child. *Rev Chir Oncol Radiol O R L Oftalmol Stomatol Chir.* 1978; 27(4):307-8. Romanian
3. Shields TW. General Thoracic Surgery, The fifth edition. 2000.
4. Symbas P, Aletras H. Hydatid disease of the lung. T. Shields General Thoracic Surgery, 4 th Ed. 1994.
5. Barrett NR. The anatomy and the pathology of multiple hydatid cysts in the thorax. *Ann R Coll Surg Engl.* 1960;26: 362-79.
6. Sârbu V. Pagini din istoria chirurgiei românești. București: Ed. Academiei Române; 2004.
7. Tetik O, Yilik L, Emrehan B, Ozbek C, Gurbuz A. Giant hydatid cyst in the interventricular septum of a pregnant woman. *Tex Heart Inst J.* 2002;29(4):333-5.
8. Fourati M, Sahnoun Y, Kamoun A, Kamoun R, Kamoun A, Aiouaz A. La chirurgie du kyste hydatique du coeur. *Annales de chirurgie thoracique et cardiovasculaire;* 1983.
9. Baysefer A, Erdogan E, Gonul E, Kayaly H, Timur Kaynak E, Seber N. Primary multiple cerebral hydatid cysts: case report with CT and MRI study. *Minim Invasive Neurosurg.* 1998; 41(1):35-7.
10. Posacioglu H, Bakalim T, Cikirikcioglu M, Yuce G, Telli A. Intramural hydatid cyst of descending aorta complicated by false aneurysm. *Scand Cardiovasc J.* 1999;33(4):242-4.
11. Chrysopathis P. Echinococcus cyst of the lung. *Dis Chest.* 1966;49(3):278-83.
12. Gharbi HA, Hassine W, Brauner MW, Dupuch K. Ultrasound examination of the hydatid liver. *Radiology.* 1981;139(2):459-63.
13. Crețu CM, Codreanu RR, Mastalier B, Popa LG, Cordoș I, Beuran M, et al. Albendazole associated to surgery or minimally invasive procedures for hydatid disease - how much and how long. *Chirurgia (Bucur).* 2012;107(1):15-21.
14. Horvat T, Grozavu C, Savu C, Cordoș I, Nicodin A, Voiculescu V. Indicație abuzivă de tratament cu Albendazol în afecțiuni toracice neparazitare. *Jurnalul de Chirurgie Toracică.* 1997;2(3-4):247-249.
15. Dubau R. Le kyste hydatique du poumon, in *Traité de Technique Chirurgicale Tome IV.* Paris: Ed Masson; 1955.
16. Dubau R, Bourdet P, Moulin F, Blanc L. Problèmes posés par les kystes hydatiques multiples. *Bull. et Mem. de la Soc des chir. de Paris.* 1962;52(6):160-168.
17. Coman C. *Tratat de patologie chirurgicală vol.V.* București: Ed. Medicală.
18. Horvat T, Cordoș I, Nistor C, Nicodin A, Grozavu C, Savu C, et al. Considerații generale asupra chistelor hidatice cu localizare toracică. *Jurnalul de Chirurgie Toracică.* 1997;2(2):137-41.
19. Horvat T, Grozavu C, Cordoș I, Nicodin A, Nistor C. Echinococoză pulmonară bilaterală (conduita chirurgicală). Comunicare la Prima Conferință Națională de Chirurgie Toracică, Tg Mureș 2-4 octombrie 1997.
20. Horvat T, Cordoș I, Nicodin A, Grozavu C, Savu C. Reevaluarea procedurilor Gerulanos și Posadas Cărpinișan în tratamentul chirurgical al chistului hidatic pulmonar. *Jurnalul de Chirurgie Toracică.* 1997;2(3-4):291-4.
21. Bourée P. Etudes des corrélations entre le group sanguins et certaines parasitoses. *Med. Chir. Dig.* 1990;16:5-6.
22. Lagrot G, Coriat P. Procédés opératoires dans le traitement du kyste hydatique hépatique. *Semaine des Hôp.* 1957;7-8:475.
23. Juvara I, Rădulescu D, Prișcu A. Probleme de patologie hepato-biliară. București: Ed Medicală; 1969.
24. Popescu I. *Chirurgia ficatului.* București: Ed. Universitară Carol Davila; 2005.
25. Doran H, Mihalache O, Pătrașcu T. Hydatid cysts with hepatic and pelvic synchronous location - clinical case. *Chirurgia (Bucur).* 2012;107(1):126-9. Romanian
26. Guzel A, Tatli M, Maciaczyk J, Altınors N. Primary cerebral intraventricular hydatid cyst: a case report and review of the literature. *J Child Neurol.* 2008;23(5):585-8. Epub 2008 Jan 11.
27. Motaș C1, Motaș N, Davidescu M, Rus O, Horvat T. Hydatid cyst of anterior mediastinum. *Chirurgia (Bucur).* 2012;107(1): 115-8. Romanian
28. Atmatzidis K, Koutelidakis I, Papaziogas B, Alexandrakis A, Chatzimavroudis G, Grigoriou M, et al. Primary hydatid cyst of the thigh. *Chirurgia (Bucur).* 2006;101(4):419-21.
29. Săvulescu F, Iordache II, Hristea R, Dumitru C, Sandru AM, Bălașa G, et al. Primary hydatid cyst with an unusual location - a case report. *Chirurgia (Bucur).* 2010;105(3):419-22.
30. Prousalidis J, Tzardinoglu K, Sgouradis L, Katsolis C. Uncommon sites of hydatid disease. *World J Surg.* 1998;22(1):17-22.
31. Macedo A J, Magalhaes M P, Tavares N J, Bento L, Sampayo F, Lima M. Cardiac hydatid cyst in a child. *Pediatr Cardiol.* 1997;18(3):226-8.
32. Atilgan D, Demirel S, Akkaya V, Korkut F. Left ventricular hydatid cyst: an unusual location of Echinococcus granulosus with multiple organ involvement. *J Am Soc Echocardiogr.* 1996; 9(2):212-5.
33. Grozavu C, Mocanu I, Brezeanu I, Cordoș I, Paraschiv M, Țucă C, et al. Echinococoză primară de aortă toracică cu multiple determinări secundare subdiafragmatice-prezentare la Al V-lea Congres Medical Militar Balcanic-Ankara septembrie 2000.
34. Atan A, Cöl C, Dolapçı M, Hökelek M. A case of pure renal hydatid cyst without multiple organ involvement. *Int Urol Nephrol.* 1997;29(1):1-4.