

Primary Axillary Hydatid Cyst

D. Mercuț¹, A. Andrițoiu¹, E.T. Trașcă¹, C. Siloși¹, A. Resceanu¹, R. Mercuț²

¹“Dr. Ștefan Odobleja” Emergency Military Hospital, Craiova, Romania

²Department of Plastic and Reconstructive Surgery, University of Medicine and Pharmacy Craiova, Romania

Rezumat

Chistul hidatic axilar primar

Echinococoză (boala hidatică) este o zoonoză cauzată de stadiul larvar al *Echinococcus granulosus* (sau *Tenia echinococcus*). Forma adultă a parazitului se găsește în intestinul câinelui, în timp ce gazdele intermediare sunt reprezentate de pisici, bovine, porci și oameni (considerați a fi gazde intermediare accidentale). Parazitul are o distribuție globală, dar zonele endemice sunt Canada, Alaska, Noua Zeelandă și Australia, regiunea mediteraneană. Chistul hidatic poate evolua o perioadă îndelungată până la apariția simptomelor sau semnelor clinice. Ficatul și plămânii sunt principalele organe afectate, dar localizarea primară a bolii hidatice la nivelul regiunii axilare este extrem de rară. În țară nu au fost descrise cazuri, în timp ce în literatura internațională sunt descrise doar 12 cazuri de boala hidatică cu localizare axilară. Prezentăm cazul unei paciente, în vârstă de 60 de ani, cu localizare primară a bolii hidatice la nivel axilar și la care s-a practicat excizia chirurgicală a chistului.

Cuvinte cheie: boala hidatică, regiunea axilară, chist

Abstract

Echinococcosis (hydatid disease) is a zoonosis caused by the larval stage of *Echinococcus granulosus* (or *Tenia echinococcus*). The adult form of the parasite lives in the gut of the dog, while the intermediate hosts, where the tapeworm develops to larval stage are cats, cattle, pigs and humans (considered to be accidental intermediate hosts). The parasite has a worldwide distribution, but the endemic areas are Canada and Alaska, Australia, New Zealand, South America and the Mediterranean region. Hydatid cyst can grow many years before the symptoms and clinical signs appear. The liver and the lungs are the most affected organs, but primary location of the hydatid disease in the axilla is extremely rare. In our country we did not find any records of axillary hydatid disease, while the literature contains only 12 cases of axillary location. We present the case of a woman, 60 years old, with a primary axillary location of hydatid cyst, who underwent a total cystectomy.

Key words: hydatid disease, axillary region, cyst.

Corresponding author:

Prof. Dorin Mercuț, MD, PhD
Surgery Department
“Dr. Șt. Odobleja” Military Emergency Hospital
no.150, Caracal street, Craiova, Romania
E-mail: mercutdorin@yahoo.com

Introduction

Hydatid disease is a parasitic infection caused by the larval stage of *Echinococcus granulosus*, which is the most incriminated species, although there are cases caused by *Echinococcus multilocularis* or *E. oligarthus*. The most common locations of the cyst are the liver (50-75% of the cases) and the lungs (5-10%), but in 5-10% of the cases, the hexacanth embryo passes through the hepatic and pulmonary filters and reaches different organs by the way of systemic arterial vessels (1). There are a described a series of unusual locations described for

hydatid disease: bladder, parotid gland, breast, thyroid gland or subcutaneous tissue. Axillary location of the hydatid cyst is extremely rare, only 12 cases having been published in the literature.

Case report

A 60 year-old woman, from the rural area, was admitted to our clinic due to presence of a tumor in the right axillary region, which appeared three years ago, then gradually increased in size, without notice of any nipple discharge, clinically detectable breast tumors, fever or any other symptoms. At local examination we found a painless, mobile, axillary tumor, of 7 cm in size, with no changes at bilateral breast exam. Biological values revealed elevated values for ESR and cholesterol, without any changes in blood cell count or leukocyte formula. Ultrasound examination revealed a transonic, cystic tumor, homogeneous, well-defined, 5 cm in size, which is close to the axillary vessels, without any Doppler signal in the cystic walls (Fig. 1). Breast ultrasound and left axilla examination detected no modification. CT-scan revealed no changes in the chest, abdomen or pelvis. Ultrasound guided puncture revealed clear, plain fluid. With the preoperative diagnosis of axillary hydatid cyst, under general anesthesia we performed a complete cyst excision, without its intrusion, together with skin coverage of the aspiration puncture site (Fig. 2). Macroscopic examination revealed hydatid fluid with germinative membrane (Fig. 3). The diagnosis was confirmed by histopathological exam. Postoperatively the patient had a favorable outcome and was discharged on the 3rd postoperative day with the indication of following treatment with albendazol for 6 months.

Discussion

Primary axillary hydatid cyst is the result of dissemination through the hepatic and pulmonary filters of hexacanth embryos of *E. granulosus*, eventually occupying so-called atypical locations: kidney, orbit, spleen, bladder, muscle, soft tissues, parotid, breast, thyroid. The axillary location of the hydatid disease is extremely rare and is not recorded in our medical literature (2,3). If no complications occur, hydatid disease is generally asymptomatic, patients rarely complaining of pain or fatigue (4). Axillary hydatid cyst ultrasound or CT scan provides the same information as in other locations. Hydatid cyst may be unilocular as in the early stages of the disease or multilocular in case of old cysts, which may present daughter cysts or may be calcified.

The differential diagnosis should mostly be done with axillary adenopathies, metastatic tumors, soft tissue sarcomas (2). Ultrasound examination was not helpful for the diagnosis. There is no single biochemical test which can establish the diagnosis. Casoni and Weinberg tests are no longer used because of low sensitivity. Tests determining of specific antigens and immune complexes in hydatid disease using ELISA are positive in more than 90% of patients and if the disease is

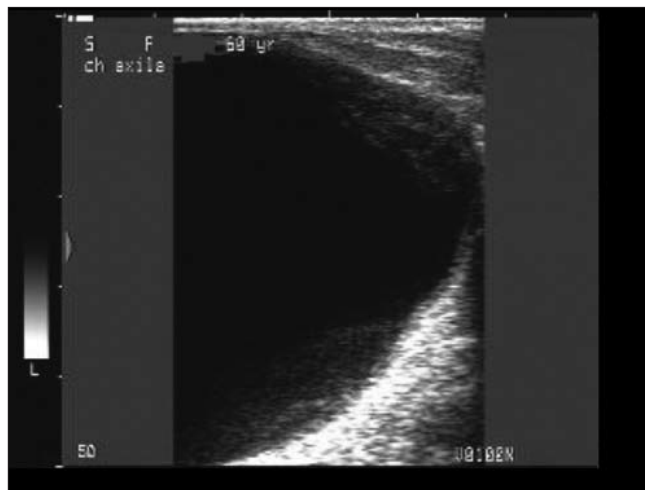


Figure 1. Ultrasound aspect of the cyst

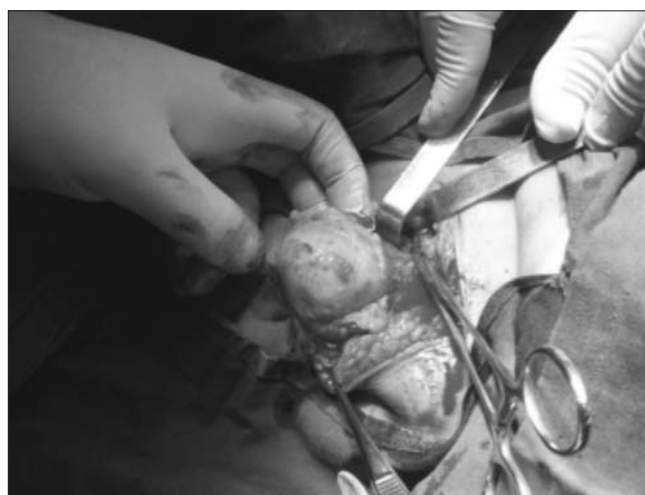


Figure 2. Intraoperative aspect

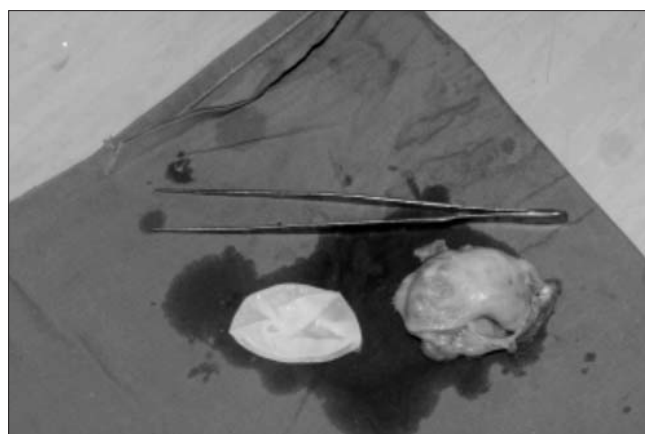


Figure 3. The cyst and the germinative membrane

present, we can highlight the Ig E and IgG antibodies. During daily surgical practice an accurate diagnosis of soft tissue

hydatid disease is often delayed until we obtain puncture aspiration cytology result or histopathological examination after surgery. Although routine use of puncture for diagnosis should be discouraged, this procedure can be very helpful when a hydatid cyst is clinically suspected (5). The puncture was performed in our patient before we suspected the presence of a hydatid cyst. The diagnosis was confirmed by the post-operative histopathological exam (6). We recorded no adverse or allergic reactions due to puncture. Therefore puncture aspiration in the evaluation of suspected soft tissue hydatid disease appears to be a safe diagnostic method. For more than 20 years benzimidazole chemotherapy has been used for the treatment of hydatidosis. Medical therapy implementation for this disease is established by WHO and indicated in the following circumstances:

- prophylaxis of postoperative recurrences,
- preparation for surgery,
- plurivisceral hydatid disease,
- patients with contraindications for surgery or who could not undergo radical surgery.

The most commonly used drugs are albendazol (10 mg/kg/day in one or two daily administrations) and mebendazole (4–5 g/day corresponding to 50 mg/kg/day), acting as parasiticides. However experience with antihelminthic agents in the treatment of soft tissue hydatid disease is limited and the results are far from being curative. Due to the small size of the hydatid axillary cyst, the image may correspond both to a fertile hydatid cyst and a non-helminthic cyst and due to the small interval between diagnosis and surgery, we did not use antiparasitic medication preoperatively. PAIR (puncture, aspiration, introduction, reaspiration with 95% alcohol or 30% saline solution) (7,8) is a non-surgical treatment of hydatid cysts of the liver based on an old method used in inoperable patients with diffuse peritoneal hydatidosis. It has been contraindicated for a long time due to the risk of leakage of cyst content in the peritoneum with well-known consequences (anaphylactic shock, secondary echinococcosis).

The main objective of surgical treatment is to prevent complications such as:

- Compression of the neighbouring organs,
- Cyst infection,
- Cyst rupture.

Total cystectomy, together with fibrous adventitia allows removing all content without parasitic leakage. This is the

curative treatment of hydatid cyst of the soft tissues.

Hydatid cysts of soft tissue can be easily broken and subsequent relapse can occur (9). We performed total cystectomy without breaking the membrane and without fluid dissemination in the axillary space. There is a possibility that the cystic wall be intimately adherent to axillary vessels and nerves and hence a risk of cyst rupture exists. To avoid this, the cystic content has to be inactivated, evacuated and afterwards a partial pericystectomy performed, to prevent secondary seeding.

Conclusions

When discovering a tumor in the axillary region, the presence of a hydatid cyst should be considered in the differential diagnosis of specific diseases in this region.

References

1. Patrașcu T, Brezean I. Chistul hidatic hepatic. In Popescu I. *Tratat de Chirurgie*. Ed. Academiei Romane; 2007. p. 634-650.
2. Mercuț D, Ianoși G, Resceanu A, Fronie S, Demetrian P, Nemeș E. Hydatid cyst--rare presentations. *Chirurgia (Bucur)*. 2004;99(3):173-6.
3. Unal AE, Ulukent SC, Bayar S, Demirkan A, Akgül H. Primary hydatid cysts of the axillary region: report of the case. *Surg Today*. 2001;31(9):803-5.
4. Kireşi YES, Karabacakoğlu A, Odev K, Karaköse S. Uncommon locations of hydatid cysts. *Acta Radiol*. 2003; 44(6):622-36.
5. Prousalidis J, Tzardinoglou K, Sgouralis L, Katsohis C, Aletras H. Uncommon sites of hydatid disease. *World J Surg*. 1998; 22(1):17-22.
6. Albayrak D, Sezer YA, Ibis AC, Yagci MA, Hatipoglu AR, Coskun I. Karaciger Kist Hidatik Olgularimiz. *Trakya Univ Tip Fak Derg*. 2008;25:95-9.
7. Ben Amor N, Gargouri M, Gharbi HA, Golvan YJ, Dyachi K, Kchouk H. Trial therapy of inoperable abdominal hydatid cysts by puncture. *Ann Parasitol Hum Comp*. 1986;61(6):689-92. French
8. Bastid C, Hzar C, Doyer M, Sahel J. Percutaneous treatment of hydatid cysts under sonographic guidance. *Dig Dis Sci*. 1994;39(7):1576-80.
9. Tuccari G, Giuffrè G, Inferrera A. Unexpected diagnosis of hydatid cyst by fine-needle biopsy (FNB). *Diagn Cytopathol*. 1997;16(1):93. Comment on: Role of fine-needle biopsy in the diagnosis of hydatid cyst. [*Diagn Cytopathol*. 1995]