

Experimental Liver Transplantation on Pigs - Technical Considerations

N. Copca¹, A. Hanna¹, C. Pivniceru¹, V. Constantinica¹, G. Radilescu², G. Gardean³, I. Campeanu¹

¹2nd Surgical Department of the "St. Mary" Hospital, Bucharest, Romania

²Intensive Care Department of the "St. Mary" Hospital, Bucharest, Romania

³Intensive Care Department with the Faculty of Veterinary Medicine, Bucharest, Romania

Rezumat

Transplantul experimental de ficat la porc - considerații tehnice

Scopul a fost acela de a ne îmbunătăți și perfecționa tehnica transplantului hepatic ortotopic.

Material și metodă: Intervențiile experimentale s-au desfășurat pe suine, 26 de perechi. S-a practicat transplantul ortotopic la porc după lavajul ficatului donatorului prin gradient presional iar transplantul s-a făcut utilizând suntul porto-cavo-jugular și suturile veno-venoase, artero-arteriale și coledoco-coledociene în maniera termino-terminală.

Rezultate: Supraviețuirea imediată a fost de 88,46%.

Concluzii: Activitatea de transplant experimental pe porci are o valoare reală contribuind la parcurgerea mai rapidă a curbei de învățare și totodată la perfecționarea manualității, creșterea eficienței suturilor precum și la consolidarea echipei anesteziico-chirurgicale.

Cuvinte cheie: transplant experimental de ficat, porc, considerații tehnice

Abstract

The purpose was to improve and refine our technique for orthotopic liver transplantation.

Material and method: Experimental interventions were performed on pigs, 26 pairs. Orthotopic transplantation was performed after lavage of the donor pig liver by pressure gradient and transplantation was performed using porto-cavo-jugular shunt and veno-venous, arterio-arterial and choledoco-choledochal sutures in end-to-end manner.

Results: Immediate survival was 88.46%.

Conclusions: Experimental transplant activity on pigs is of real value, contributing to a faster learning curve and at the same time improving handling, increasing the efficiency of sutures, as well as anesthetic and surgical team building.

Key words: experimental liver transplantation, pigs, technical considerations

Introduction

Beginning with October 2011, in the 2nd Surgical Department of the "St. Mary" Hospital in Bucharest we have developed an experimental surgery program performed on animals (pigs) for liver transplant operations. This project was developed in partnership with the Faculty of Veterinary Medicine in Bucharest that has provided us with the operating theatre and logistics. The purpose was to improve and refine our surgical technique for orthotopic liver transplantation (1) going through the learning curve with the only goal of immediate survival, at the end of intervention (cardiac activity present on the monitor), knowing that the first step to the success of a transplant is a perfect technique. Only after that would immunologic management to prevent rejection of the grafted liver (2) become a major concern.

Corresponding author:

Narcis Copca MD
2nd Surgical Clinic of the "St. Mary" Hospital
Bucharest, Romania
E-mail: narciscopca@yahoo.com

Material and Method

This activity was intensively developed over several months between 2011 and 2012. The experimental animals were 26 pairs of medium sized pigs, Pietrain race, balanced in terms of gender ratio (60 % male), with an average weight of 35 kg. The animals were brought from the farm to the Faculty of Veterinary Medicine shelter 48 hours before the procedure, kept in separate rooms, fed properly until one day prior to the surgical intervention and kept free from stress as a mandatory condition. We have always used two pigs, out of which one was the source of the donor liver and the other was the recipient. We have always used general anesthesia, preceded by sedation with Ketamine 1-2 mg/kg i.m. and Xylazine 1 mg/kg i.m., performed about 30 minutes before intervention. For the first 5 transplants general anesthesia was performed by endotracheal intubation, but due to the systematic absence of specific catheters we gave up, and as such, in the following cases intubation was performed by tracheostomy, which proved much easier and safer - none of the processes of intubation endangered the animal's life and lead to death. General anesthesia was preceded by fitting a cannula in a vein of the right or left ear. During the interventions of both the donor and the recipient vital functions were monitored: electrocardiography (ECG), blood pressure (BP), heart rate (AV), oxygen saturation (SpO₂) on the anesthesia monitor. Rectal temperature on the intrarectal thermometer and diuresis on Foley catheter mounted by cystostomy were also under surveillance. Anesthesia involved administration of O₂ and Sevoflurane 2-3% through the mask. Propofol 2 mg/kg i.v. was used for induction and Dormicum 1 mg i.v. for hypnosis, Fentanyl 0.1 mg i.v. for analgesia, Norcuron 1mg i.v. to prevent twitching, Lystenon 150 mg i.v. for depolarizing in intubation purposes. Maintaining of anesthesia was obtained with Sevoflurane 2-3%, Fentanyl 0.1 mg repeated every 30 minutes, Norcuron 1 mg repeated after 45 minutes. Mechanical ventilation was performed under pressure control to maintain inspiratory pressure = 400-600 ml / breath and respiratory rate = 12 / minute. The central venous catheter was always mounted on the external jugular vein denudation, performed by the surgeon and anesthesiologist. Depending on the intraoperative evolution and operator times, the anesthesia required a cardiac inotropic positive support: Dopamine 250 mg/50 ml by automatic syringe 2-6-18 ml / 1 hour (60-100 micrograms/kg/ minute), dobutamine 250 mg/50 ml by automatic syringe 2-5-10 ml / 1 h. Heparinization was performed before and during the mounting of extracorporeal circulation as follows: Heparin 10.000u/50 ml physiological serum by injectomat 5 ml / 1 hour (1000U / h, 15-20 U / kg / h under APTT control (24-34 sec-normal) up to twice the normal values. Volume replacement support was performed by Voluven, Vitafuzor or HES and blood provided through autotransfusion.

The operation began, both in the donor and the recipient's case, with incision and discovery in the cervical region, of both external jugular veins and internal carotids carotids and one side was used by the anesthesiologist for

venous and arterial line.

Regarding liver transplant surgery on pigs the initial difficulties in identifying the anatomy of the animal were quickly overcome after the first 3-4 surgeries performed, but instead some anatomical particularities have raised real problems difficult to overcome, an aspect that will be discussed later.

The technique used for prevation of the donor liver was the same in all 26 pigs and started with median xiphosuprapubical incision and xiphoid appendix resection, the mounting of a cystostoma by Foley catheter through implantation in the bladder; cholecystectomy was practiced only in 8 cases. After that, the triangular ligament of the liver was incised and its mobilization, double ligature with wire supported on the left and right inferior diaphragmatic pedicle was made with silk or polypropylene wire. Hepatoduodenal ligament dissection from right to left, with identification of the common bile duct at the edge of the ligament and its limited dissection, avoid devascularisation in the suprapancreatic portion and keep it on the traction loop, was followed by portal vein dissection up to the origin of the spleno-mesenteric trunk in the retropancreatic portion and loop isolation. (3,4,5) The next step was the dissection of the common hepatic artery at the origin of the celiac trunk and isolation after finding its hepatic branches, followed by the dissection of the lower subhepatic vena cava up to the confluence of the right and left renal veins while maintaining on loop and dissection with systematic ligature of the suprarenal veins. (3,4,5) The next step was the dissection of the descending aorta prior to its bifurcation in iliac arteries and maintaining on loop, and the dissection of the lower vena cava in the suprahepatic area after performing a circular incision in the diaphragm (the actual free area of the vein is located in the intrathoracic region in the pig) up to the vicinity of the right atrium, to obtain enough material for the anastomosis (6). Dissection of the aorta in the supraceliac region was followed by incision of the descending aorta in the caudal region after the ligature of the distal head of the artery and after clamping of the supraceliac aorta and installation of an arterial lavage system exclusively for the liver (7). The lavage system used was made of a suspended recipient providing lavage through pressure gradient following Calne's method (8). The lavage solution was Ringer's - lactate, enriched, 3 litres at 4 degrees Celsius following Chalstrey technique (9). This lavage solution was drained from the liver through the lower vena cava sectioned intrahepatically, until the suctioned fluid became clear. Sectioning of the CBD and of the common hepatic artery as close as possible to the distal region and collection of the liver, which was placed in a recipient with ice, ended this surgical stage. Immediately prior to collection, all animals were alive, as proven by heart activity shown on screen. Following that, the donor experimental animal was euthanized, a urinary probe was extracted and parietoraphy performed.

The dissection of the pedicles and the regularization of the anastomosis edge were continued on the work table for the donor liver.

The receiver's liver collection technique was the same as described above for the donor, provided that all anatomic structures were dissected and sectioned as close to the liver as possible, maintaining arterial, venous and biliary pedicles as long as possible (as opposed the donor's case). Anatomical variations and particularities proved to be challenges that we needed to overcome when performing hepatectomy, and these issues shall be described subsequently.

The porto-cavo-jugular bypass was performed as follows: the afferent branch in the previously dissected external jugular vein and the other 2 efferent branches, one in the lower vena cava, sectioned transversally with a stump as long as possible, and the other efferent branch in the portal vein sectioned as close as possible to the bifurcation of the two portal branches, left and right. The execution of the bypass may be followed by significant blood losses, with important hemodynamic changes, occasionally very difficult to correct even by administration of blood previously collected from the donor pig. Liver transplant from donor to receiver involves the execution of veno-venous, artero-arterial and bilio-biliary anastomosis. The first one is the suprahepatic cavo-cava anastomosis executed termino-terminally, (T-T) with running suture with polypropylene thread 4-0, checking the suture tightness and the possible need for adding threads in "X". The next one was porto-portal anastomosis, performed similarly to T-T, but with polypropylene 5-0 thread and using the "growth factor" technique. Following was the intrahepatic cavo-cava anastomosis T-T, also with running suture with polypropylene thread 4-0. (Fig. 1) Arterio-arterial anastomosis was performed T-T with running suture with double reinforced thread 6-0 polypropylene, except for 3 cases where an arterial patch was used following Carrel technique. Choledoch-choledochal anastomosis T-T with double reinforced polypropylene thread 6-0 in running suture ended the anastomosis stage. (Fig. 2) This anastomosis was performed like in human liver transplantation T-T manner without Kehr catheter (10).

Viability check on the experimental animal was done by determination of heart activity – present in 23 cases, and in 3 cases finalization of procedure was achieved without any heart activity seen (the receiver had deceased) followed by removal of cystostoma, closing of the abdominal and cervical wounds and collection of the devices.

Results and Discussions

From the various and significant issues raised by liver transplant (11) concerning surgical methods, immediate and long-term survival, immunologic management, physiopathological aspects, we intended, through this project, to improve and fine-tune resection and suture techniques, as well as the cohesion within surgery and anesthesiology teams.

As for the selection of animals submitted to surgical interventions, we were provided with pigs somewhat larger compared to the ideal size as considered by Calne and Chalstrey (8,9), with no inconvenient. They preferred animals

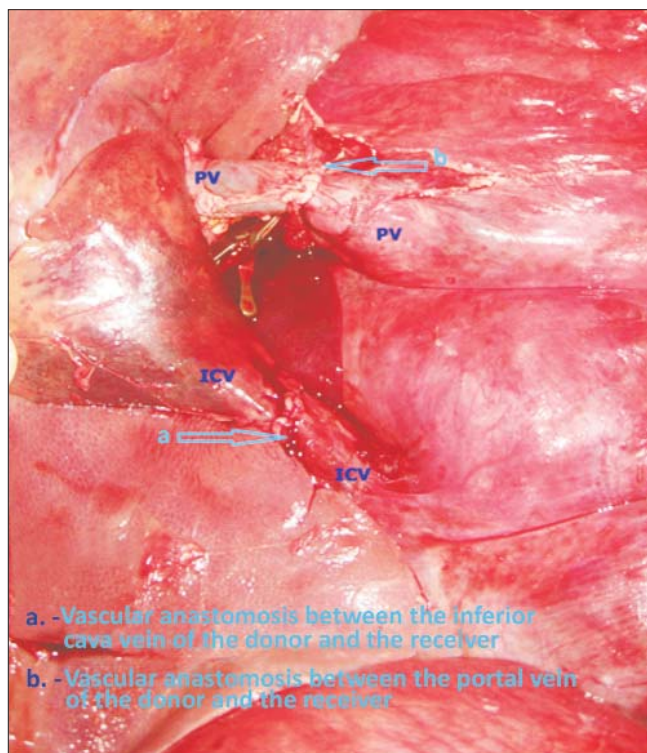


Figure 1.

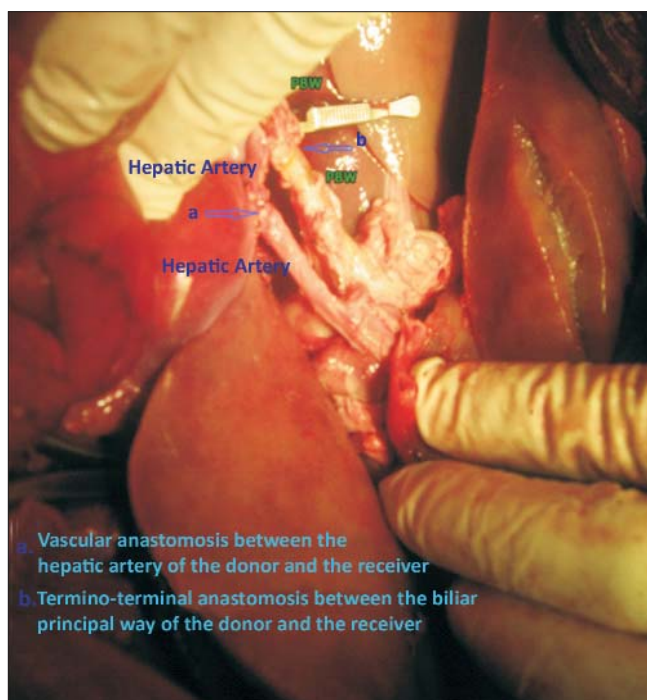


Figure 2.

with a weight of 30 kg, as they have vascular size large enough for cannulation and also reduced fat tissue.

The anatomical features found in donors were represented by a short trunk of portal vein (connection between the splenic vein and the upper mesenteric vein, in the supra-pancreatic area), when we were forced – to gain some length –

to collect it as close as possible to the distal area after the ligation of the splenic vein and of other 2-3 branches - 4 cases. In swine, the lower vena cava (IVC) in the suprapancreatic region is very short (12), since it is not provided with an extrahepatic route, collection being made with a circular diaphragmatic collar. The CBD was of filiform shape, making it difficult to undergo anastomosis, in 5 cases, the cystic was always long, in "rifle barrel" shape with the CBD and low drainage, close to the pancreas, with miscalibration after the cystic junction, and we were forced to use the cystic-choledochal junction like a patch. The hepatic artery was always dissected up to the celiac body, but in 3 cases this was not enough, as the artery was very small in size and we needed to use an aortic arterial patch (Carrel patch), following Calne technique (8).

In both the donor and the receiver CBD dissection was not performed in closest proximity to the CBD edge to prevent unneeded injury of the pericholedochal vascular plexus, more precisely to prevent de-vascularization, which may lead to subsequent biliary complications. In what concerns the suprahepatic lower vena cava, it is known that the actual free area is located in the intrathoracic region, so that dissection was performed up to the vicinity of the right atrium even if subsequently we performed a resection so that the suprahepatic cavo-cava anastomosis was brought slightly closer to diaphragm level with no excess material (13). As for liver lavage, we only used pressure gradient lavage (8). As opposed to traditional techniques (8) we preferred aortic perfusion without accompanying portal perfusion because it is more physiological in nature and, in particular, the lesions to the hepatic sinusoids are smaller (7).

As for difficulties encountered with the receiver, in two cases we had dimensional incompatibilities between the donor liver and the receiver's capacity, resulting in difficulties in positioning the liver and in performing anastomoses. In 4 cases we recorded insertion of low hepatic parenchyma on the intrahepatic lower vena cava, being forced to perform a lower section of the vena cava which resulted in a shorter stump, even more so since we used the porto-cavo-jugular bypass in "Y" with inherent loss of venous material in all receivers (due to venous lesions caused by the circular threads that fasten the tubes of the "Y" device). Still, in 3 cases, due to the short body of the portal vein together with a long emergence of the two portal branches, we were forced to section the portal vein as close to the distal area as possible, right at the ramification point of the portal vein. The choledochal channel was filiform in 5 cases and the hepatic artery had a pennate distribution in 3 cases, where we used an aortic Carrel patch.

Heparinization of the animal (6) was done without using a pump (14) that would provide a moderate systemic heparinization, but by direct administration into circulation and in the venous shunt (7) of approximately 10000 ui heparin. The execution of the bypass may be followed by significant blood loss, with important hemodynamic changes, occasionally very difficult to correct even by administration of blood previously collected from the donor pig. Sudden hemodynamic changes were seen during the anhepatic stage and immediately after

revascularization (15). Metabolic acidosis and hemodynamic changes were rapidly corrected by the anesthesiologist by administration of bicarbonate solutions and tensing agents (16). We did not use the method of maintaining blood flow in vena cava (piggy back), in any of the cases, although this method decreases anhepatic time as well as the amount of blood loss (17). Oike et al (18) claim that if suprahepatic cavo-cava and porto-portal anastomoses are performed within maximum 30 minutes, transplant may be achieved without extracorporeal circulation and therefore preventing complications of the anhepatic stage.

When performing veno-venous, artero-arterial, biliobiliary anastomoses we always used the T-T suture (end to end) although other anastomosis methods were available (termino-lateral, T-L, end to side).

Minor incidents and accidents consisting of failure of vascular suture tightness were corrected with additional sutures in "X" or overlapped stitches, and minor bleedings resulted from dissection were solved with the bipolar cautery or supporting threads. In one case a slight stenosis occurred due to suture of the porto-portal anastomosis. Among major incidents and accidents regarding the receiving pig, we sometimes found a massive blood loss when performing port-cavo-jugular bypass due to size incompatibility of the arms of the "Y" shunt, a maneuver that is dependent on the training curve and that may represent the main cause of deterioration of the animal's hemodynamics, with essential contribution to exitus in all 3 deceased cases. In one of the 3 cases, a bleed from the suprahepatic cavo-cava anastomosis occurred intra-thoracically and not intra-abdominally, therefore noted with delay (a case where lumen recalibration was needed due to the receiver's excess of suprahepatic cava). Out of the 26 transplants, 23 (88.46%) presented heart activity after the completion of the intervention, following which the animal underwent euthanasia.

Conclusions

Upon completion of the 26 experimental liver transplants in pigs, we achieved a significant shortening of the work time: at first, surgical interventions had a total duration of approximately 7 hours, which in the end came to less than 5 hours. Intra-surgical incidents and accidents resulting from anatomical features of the experimental animals decreased progressively, both those due to surgical intervention - accidental venous lesions, faulty or inefficient haemostasis, significant blood losses, failure of tightness of vein sutures, and also those caused by significant hemodynamic changes, acidosis. Blood loss in receivers when performing the shunt dropped from app. 500 ml in first pigs down to app. 250 ml.

For future human transplant activities, we consider that improvement in resection and suture techniques based on experimental activities on pigs is of real value, contributing to a faster completion of the training curve and also to an improvement in hand skills, an increase in suture efficiency, as well as to improvement in the cohesion between anesthetic and surgical teams.

This paper aims to highlight a technical model to future experimental studies of molecular biology in order to determine the factors involved in liver graft rejection, the phenomenon of thrombosis and factors that contribute to biliary degeneration.

References

- Filipponi F, Trivelle MG, Oleggini M, Pardini P, Meacci L, Bellissima G, et al. Surgical research in orthotopic liver transplantation: experiences in the pig model. *G. Chir.* 1996; 17(4):201-9.
- Guiney EJ, O'Connor JB, Fernando A, Healy B, Michaelowich B, Cahil J, et al. A tehnic of liver transplantation in the pig. *Irish Journal of Medical Science.* 1974;143(1):255-63.
- Popescu I. *Transplantul hepatic.* București: Ed. Academiei Române; 2011.
- Popescu I, Ciurea S, Alexandrescu S, Matei E, Sabau D. *Transplantul Hepatic. Transplantul cu ficat întreg.* Enciclopedia de chirurgie. 2007;3(1):1-20.
- Popescu I. *Chirurgia ficatului, vol. I și II.* București: Editura Universitară "Carol Davila"; 2004.
- Hirai Ichihiro, Suto Koichy, Moriya Toshiyuki, Fuse Achira, Endo Junko, Owada Kazuo, et al. Pig liver transplantation using passive by pass of portal vein and inferior vena cava. *Yamada Medical J.* 2002;20(2):29-39. Japan
- Filipponi F, Boggi U, Dell Capanna S, Carmellini M, Meacci M, Mosca F. *Surgical research on orthotopic liver transplantation: toscany experience in the pig model in liver transplantation: from laboratory to clinic.* Casa Editrice Idelson; 1988.
- Calne RY, Yoffa DE, White HJO, Maggin RR. A tehnicque of orthotopic liver transpalntation in the pig. *British Journal Surgery.* 1968;55(3):203-6.
- Chalstrey LJ, Parbhoo SP, Tappin A, Baker GJ, Gracey LRH, Mullen PA, Lester R. *Tehnicque of orthotopic liver transplantation in the pig.* London: Departments of Medicine, Surgery, and Anesthesia, Royal Free Hospital and The Departments of Surgeru And Medicine, Royal Veterinary College. p. 585-587.
- Dorobanțu B, Brașoveanu V, Hrehoreț D, Matei E, Ionescu M, Popescu I. Biliary complications following liver transplantation. *Chirurgia (Bucur).* 2011;106(4):433-8. Romanian
- Wolff H, Otto G. Liver transplantation in animal experiments. *Z Exp Chir.* 1978;11(3):157-76. German
- Mirela Patricia Sirbu Boeti, Sadiq Shoab, Alaa Elshorbagy, Catalin Iulian Efrimescu and Irinel Popescu. *Experimental Liver Transplantation, Liver Transplantation - Technical Issues and Complications, Prof. Hesam, Abdeldayem (Ed.);* 2012.
- Filipponi F, Fabbri LP, Elbetti C, Falcini F, Rontini M. Orthotopic liver transplantation in the pig: a surgical experience with 124 liver transplants. *G. Chir.* 1992;13(3):101-5
- Filipponi F, Falcini F, Banassai C, Martini E. Orthotopic liver transplant in pigs: several variations of the surgical ethnic. *G. Chir.* 1989;10(7-8):374-8.
- Torres OJ, Pantoja PB, Barbosa ES, Barros C de A, Servin ET, Servin SC. Hemodynamic alterations during orthotopic liver experimental transplantation in pigs. *Acta Cir Bras.* 2008; 23(2):135-9.
- de Lange JJ, Hoitsma HF, Meijer S. Anaesthetic management in experimental orthotopic liver transplantation in the pig. *Eur Surg Res.* 1984;16(6):360-5.
- Hunan Yi Ke Da Xue Bao. *The Model of piggy back orthotopic liver transplantation in pigs.* Hunan Medical University, Changsha. 1999;24(1):77-9.
- Oike F, Uryuhara K, Otsuka M, Dehoux JP, Otte JB, Lerut J, et al. Simplified tehnicque of orthotopic liver transplantation in pigs. *Transplantation, Brief Communications.* 2001;71(2):328-39.