

Multifocal Choroidal Metastases from Thyroid Carcinoma: A Case Report

M. Munteanu¹, S. Giuri², C. Roșca³, O. Boruga¹, O. Crețu⁴

¹“Victor Babeș” University of Medicine and Pharmacy, Department of Ophthalmology, Timișoara, Romania

²Private Practice “Dr. Giuri Stela”, Timișoara, Romania

³“Optilens” Clinic of Ophthalmology, Cluj-Napoca, Romania

⁴Department of Surgery, “Victor Babeș” University of Medicine and Pharmacy, Timișoara, Romania

Rezumat

Metastază coroidiană multifocală de la carcinom tiroidian: prezentare de caz

Este prezentat cazul unei paciente în vârstă de 62 de ani, diagnosticată cu carcinom tiroidian papilar varianta foliculară, ce s-a prezentat pentru scăderea accentuată a acuității vizuale la ochiul drept. În pofida tratamentului complex aplicat, ce a cuprins tiroidectomie subtotală, ablația tiroidiană cu I-131, terapie supresivă cu LT4, și radioterapie externă cu cobalt 60, aceasta a dezvoltat metastaze multiple pulmonare, mediastinale, hepatice și osoase, urmate la 1 an, de metastaze coroidiene multifocale. Sunt prezentate investigațiile oculare complexe efectuate pentru evidențierea și urmărirea metastazelor coroidiene ale pacientei. O trecere în revistă a literaturii de specialitate a fost deasemenea realizată. Raritatea metastazelor coroidiene la pacienții cu carcinom tiroidian impune, pentru evidențierea lor, examene oculare periodice.

Cuvinte cheie: tiroidă, carcinom, metastaze, coroidă

Abstract

We present the case of a 62-year-old female patient, with follicular variant of papillary thyroid carcinoma, which presented to our department for a severe decrease in vision

at right eye level. Despite a complex therapy, that included a near-total thyroidectomy, thyroid I-131 ablation, suppressive therapy with LT4, and external beam radiotherapy with cobalt-60, the patient developed multiple lung, mediastinal, liver, and bone metastases, followed after 1 year, by multifocal choroidal metastases. The complex ocular investigations performed for the diagnosis and follow-up of the choroidal metastases are presented. A review of the literature was also performed. The rarity of choroidal metastases in patients with thyroid carcinoma imposes, for their detection, periodic ocular examinations.

Key words: thyroid, carcinoma, metastases, choroid

Introduction

Metastases of thyroid carcinoma to the choroid and/or orbit are rare; a PubMed-based survey for papers and case reports in the English language from 1977 to 2012, revealed 31 reported cases of orbital and/or ocular metastases from the thyroid (1).

Patients who have a cancer (usually a carcinoma) that arises in some organ or tissue other than the eye, occasionally develop metastases within the eye. Most intraocular metastatic tumors involve the choroid, but similar lesions also affect the iris, ciliary body, optic nerve, neural retina, and vitreous in some patients. About 80% of affected persons present with a single tumor in only one eye. The other 20% have multiple tumors, bilateral tumors, or both. The presence of metastatic cancer in the eye poses a substantial risk to the patient for visual deterioration and possibly total blindness in the affected

Corresponding author:

Conf. Dr. Mihnea Munteanu
Gheorghe Marinescu Street, no. 3, ap. 3
300092, Timișoara, Romania
E-mail: mihneam1@gmail.com

eye. Fortunately, treatment of such tumors is usually highly effective in terms of both local tumor control and preservation of sight. Unfortunately, metastatic cancer to the eye is a poor prognostic sign for long-term survival (2).

Material and Method

Herein we report the case of multifocal choroidal metastases in a 62-year-old female with follicular variant of papillary thyroid carcinoma. She was addressed to our service for decreased visual acuity in the right eye, for which she underwent a complete ophthalmologic examination.

The patient was diagnosed 5 years ago with thyroid carcinoma. First, she underwent surgical therapy: a near-total thyroidectomy was performed, with favorable postoperative evolution. The histopathological examination revealed a diffuse, follicular variant of papillary thyroid carcinoma, associated with massive fibrosis. Postoperative, as adjuvant therapy, thyroid I-131 ablation and suppressive therapy with LT4 was performed.

After 2 years, a recurrence in the left later cervical lymph-nodes was found, for which a lateral neck dissection followed by external beam radiotherapy with cobalt-60 was performed, total dose of 40 Gy.

Following the monitoring of our patient by determination of thyroglobulin and anti-thyroglobulin autoantibodies values, and I-131 diagnostic WB scan (Fig. 1), a FDG-PET scan (Fig. 2 A,B) was required. This scan revealed multiple lung, mediastinal, liver, and bone metastases.

One year after that, our patient presented with a decrease in visual acuity at right eye level. The ophthalmoscopic examination revealed three choroidal tumor nodules, well defined, white-yellow, situated superior and temporal to the macula (Fig. 3). The fluorescein angiography (FAG) revealed, in the late phase, three hyperfluorescent choroidal tumors,

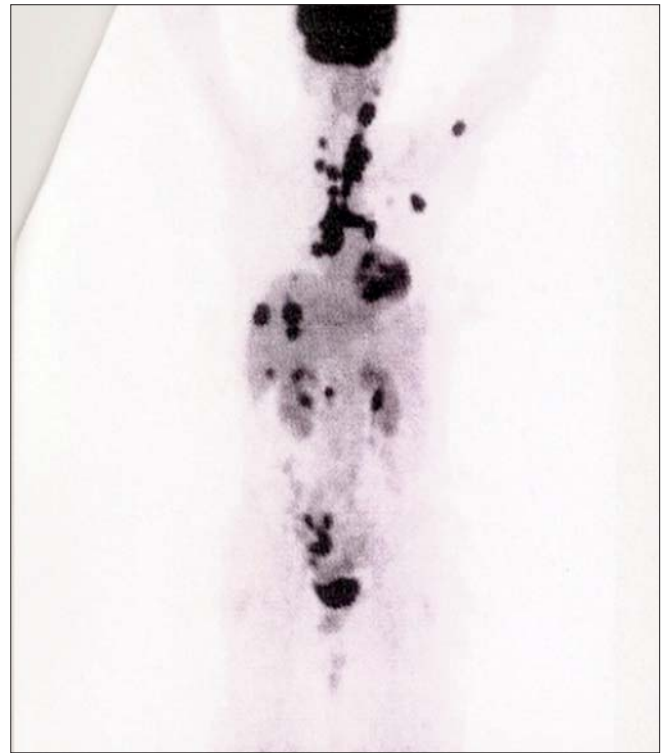


Figure 1. I-131 diagnostic whole-body scan: focal capture of iodine outside the thyroid

surrounded by a crown of fluorescent points. (Fig. 4). B-scan ultrasonography showed a dome-shaped tumor nodule, with inhomogeneous echostructure and high reflectivity (Fig. 5). Optical coherence tomography (OCT) examination revealed the prominence of the retina, areas of neuroepithelium detachment, and high reflective spots in the subretinal space (Fig. 6).

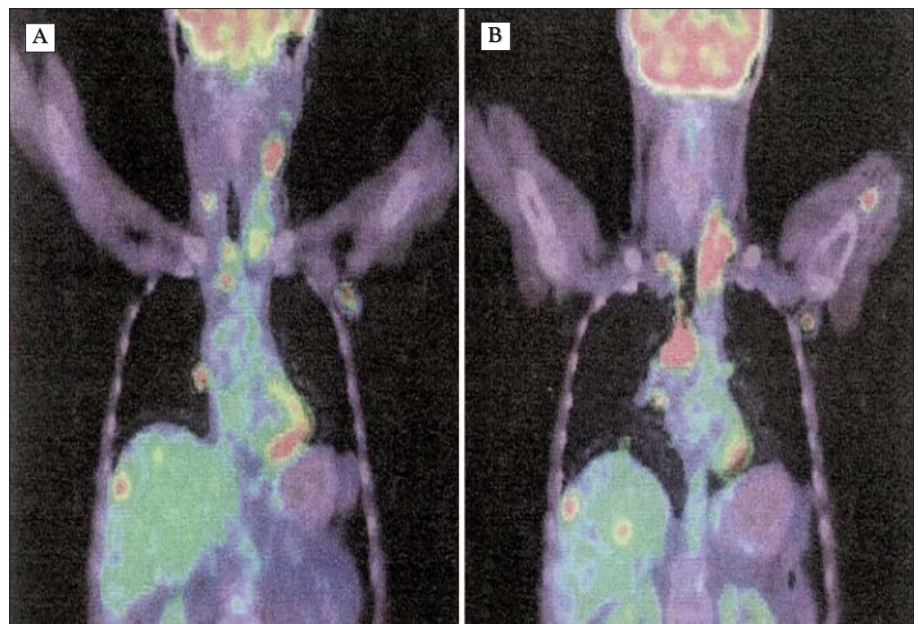


Figure 2. (A,B) FDG-PET scan: multiple lung, mediastinal, liver, and bone metastases

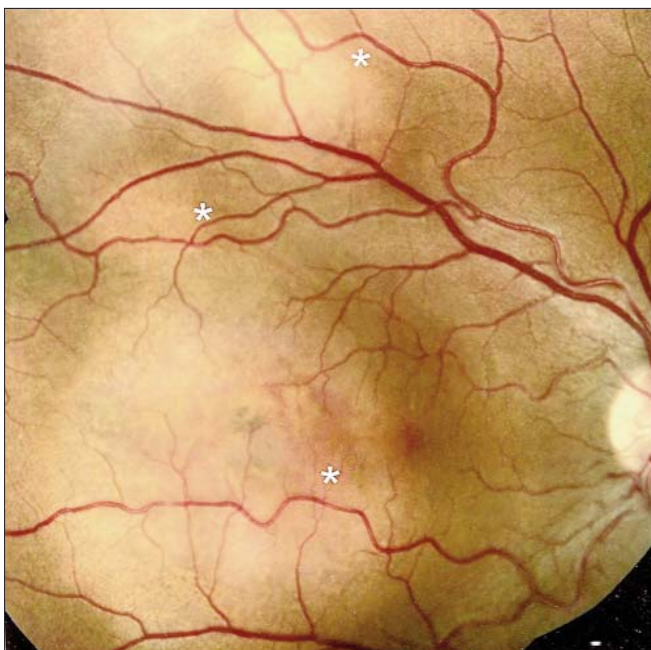

Figure 3. Ophthalmoscopic aspect of the right eye: three choroidal tumor nodules, well defined, white-yellow, situated superior and temporal to the macula.

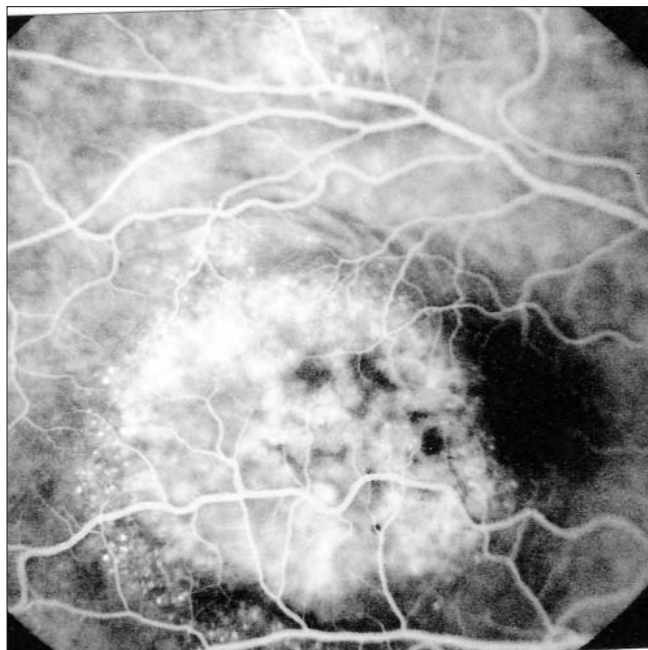


Figure 4. Fluorescein angiography of the right eye: late-phase, three hyperfluorescent choroidal tumors, surrounded by a crown of fluorescent points

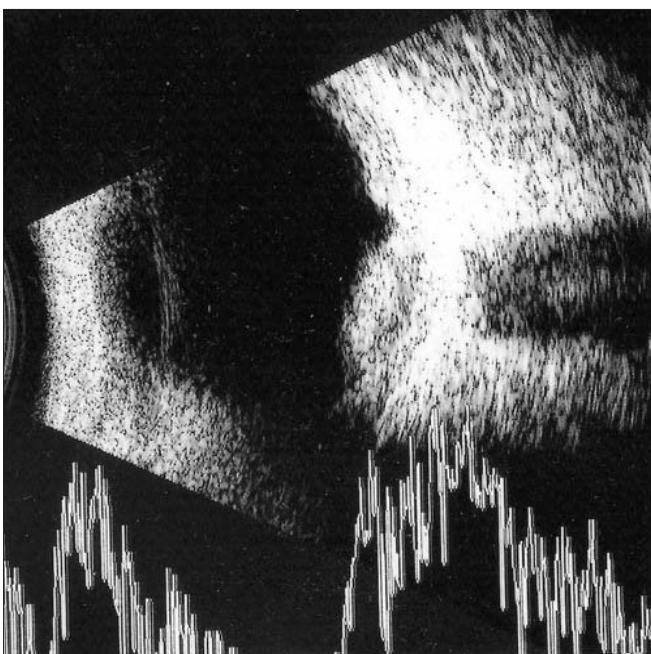


Figure 5. B-scan ultrasonography: dome-shaped tumor nodule, with inhomogeneous echostructure and high reflectivity.

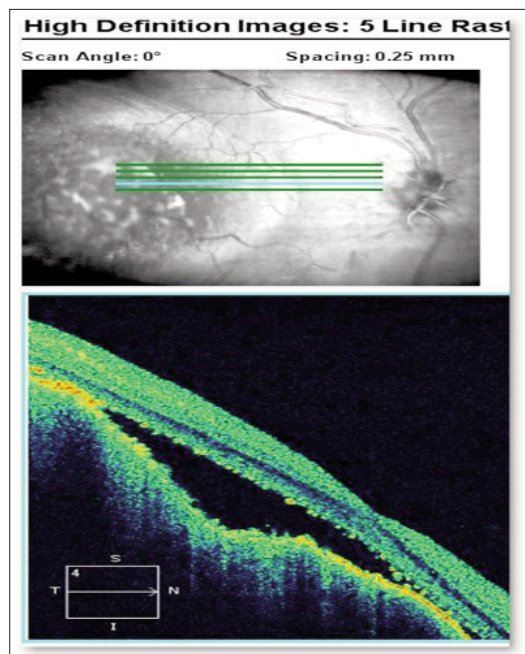


Figure 6. Optical coherence tomography (OCT): prominence of the retina, areas of neuroepithelium detachment, and high reflective spots in the subretinal space

Discussions

Choroidal metastases are the most frequent malignant diseases of the uvea in adults. Prevalence of intraocular metastases is between 2.5 - 9.5 % of patients with metastatic carcinomas. The origin of the primary tumor of the ocular metastases is: breast carcinoma in 47% of cases, lung carcinoma in 21 % of cases, gastrointestinal tract 4%, kidney 2%, thyroid carcinoma

in 0.4% of cases, and primitive tumors of unknown origin in 17% of cases (3). Most ocular metastases are not clinically detected - small tumoral infiltrates, developed in terminal phases. Symptomatic metastases, diagnosed and treated, are 15 times less frequent than choroidal melanomas.

The ophthalmoscopic aspect of choroidal metastasis is

Table 1. Development of choroidal metastases in the late stages of the thyroid metastatic disease – literature data

Author	Patient's age	Age at the moment of thyroid cc diagnosis	General metastases (years of disease)	Choroidal metastases (years of disease)
Senevirante (2011)	74 years	38 years	Bone: > 23 years	> 36 years
Biancetto (2008)	56 years	20 years	Lymphatic: > 33 years	> 36 years
Ahmadi (2001)	43 years	13 years	-	> 30 years.

variable. This can be of two types: nodular, less prominent, with a well-defined or diffuse contour, multilocular, or smooth, uniform, with pigment migration, or white-yellow intensive refringent aggregates, or, more rarely, deposits of orange pigment. The tumoral infiltration of the choroid is frequently more extensive than the ophthalmoscopically revealed tumor.

We would like to mention that in our case, the triple nodular metastasis aspect pleads for metastasis through the bloodstream by dispersion of a metastatic embolus in the choroidal vascular network. The commonest places for metastatic hematogenous spread of thyroid tumors are: the bone, lung and brain, but hematogenous spread may also affect the choroid and the skin (4).

Most authors describe choroidal metastases in the late stages of progressive thyroid metastatic disease (5,6,7) (Table 1).

Specific investigations for patients with thyroid carcinoma are: Serum Thyroglobulin (Tg) and anti-Thyroglobulin antibodies, I¹³¹ - diagnostic - WholeBodyScan (WBS) and FDG-PET/CT. The I¹³¹ WBS shows focal capture of iodine outside the thyroid in patients with detectable levels of serum Tg and the FDG - PET/CT scan is indicated in patients with Tg > 10 ng/ml but with negative I 131-WBS, for restaging of the disease and highlighting recurrences and metastases (8).

As complementary examinations one can undergo: Fluorescein angiography (FAG), Indocyanine green angiography (ICG), A and B-scan Ultrasonography, Computerized Tomodensitometry (CT), Magnetic resonance imaging (MRI) and Optical coherence tomography (OCT). The choroidal metastases of thyroid carcinoma have no specific aspect in angiography - a diminished fluorescence, late onset, absence of double vascularization, peritumoral hyper-fluorescent points that can be observed.

ICG angiography is essential in the differential diagnosis (the metastasis appears as an opaque, avascular mass). There is one exception: metastases of tumors with slow growth, which are intens vascularized (thyroid cc metastases).

The A-scan ultrasound, which shows the internal tumor reflectivity of the choroidal mass, with medium-low intensity and irregular aspect, is relevant for the metastasis; the B-scan ultrasound reveals a uniform tumoral mass, with the same aspect for hemangioma, achromic melanoma, and choroidal metastasis.

CT scan has a limited contribution to the positive diagnosis, but is important for the differentiation between osteoma and sclero-choroidal calcifications.

MRI is able to highlight tumors with a low intake of contrast substance, being useful for differentiation from exudative decollation of the retina, but not from other non-

pigmented choroidal tumors.

OCT is not useful for the histological differentiation of the tumor, presenting just the changes of the retinal pigment epithelium (RPE) and the neurosensory retina.

The differential diagnosis of choroidal metastasis of thyroid carcinoma includes: other types of intraocular tumors (achromic melanoma, achromic naevus, choroidal hemangioma, choroidal osteoma) or other local conditions (nodular scleritis, choroidal granulomas, exudative retinal detachment, sclerochoroidal ossifications).

The diagnosis can also be made by transretinal choroidal biopsy with a 25G vitrector (9).

This type of metastatic tumor can have an aggressive evolution and complicate with scleral invasion, Bruch's membrane rupture, retinal hemorrhages, vitreous hemorrhages, secondary glaucoma through "mass-effect" (10).

Unfortunately the therapeutic strategy is mostly palliative. There are some reported cases of cryo- and photocoagulation for choroidal metastasis from thyroid carcinoma (11). From this point of view we can differentiate two types of metastasis: thyroid metastases that are FDG-PET/CT negative and sensible to I-131 radioablation and the ones that are FDG-PET /CT positive, which are resistant to therapy with radioactive iodine. The treatment remains difficult because metastases from thyroid cancer are very poorly sensitive to radiotherapy and chemotherapy (12). The average survival rate is between 7 and 8 months.

Conclusions

The rarity of choroidal metastases in patients with thyroid carcinoma imposes, for their detection, periodic ocular examinations. The treatment is difficult because metastases from thyroid cancer are poorly sensitive to chemotherapy and radiotherapy, and they appear in most cases in the late stages of the thyroid metastatic disease. Although it is extremely rare, the possibility of choroidal metastases should be considered in any decrease of vision in patients with thyroid cancer.

Early detection of thyroid malignancy should be the main target in this cases, and new methods like real time elastography promise a good potential in diagnosing thyroid malignancy (13).

References

1. Besic N, Luznik Z. Choroidal and orbital metastases from thyroid cancer. *Thyroid*. 2012 Oct 19. [Epub ahead of print]
2. Yanoff M, Druker JS. *Ophthalmology*, third edition, 2008.

3. Shields CL, Shields JA, Gross NE, Schwartz GP, Lally SE. Survey of 520 eyes with uveal metastases. *Ophthalmology*. 1997;104(8):1265-76.
4. Bucierius J, Meyka S, Michael B, Biersack HJ, Eter N. Papillary thyroid carcinoma with an uncommon spread of hematogenous metastases to the choroid and the skin. *J Natl Med Assoc*. 2008;100(1):104-7.
5. Seneviratne DR, Stavrou P, Good P. Late-stage metastasis to the choroid from follicular thyroid carcinoma-case report. *Optometry*. 2011;82(4):215-7.
6. Bianciotto CG, Demirci HY, Shields CL, Shields JA. Simultaneous eyelid and choroidal metastases 36 years after diagnosis of medullary thyroid carcinoma. *Ophthal Plast Reconstr Surg*. 2008;24(1):62-3.
7. Ahmadi MA, Nicholes D, Esmali B. Late choroidal metastasis secondary to papillary thyroid carcinoma. *Am J Ophthalmol*. 2001;132(5):796-8.
8. Kurli M, Reddy S, Tena LB, Pavlick AC, Finger PT. Whole body positron emission tomography/computed tomography staging of metastatic choroidal melanoma. *Am J Ophthalmol*. 2005;140(2):193-9.
9. Scott AW, Cummings TJ, Kirkpatrick JP, Mruthyunjaya P. Choroidal metastasis of follicular thyroid adenocarcinoma diagnosed by 25-gauge transretinal biopsy. *Ann Ophthalmol (Skokie)*. 2008;40(2):110-2.
10. Singh U, Kaushik S, Pandav SS, Dogra MR, Powari M, Das A, Hemachandra M. Papillary carcinoma thyroid presenting as a choroidal metastasis. Report of a case and brief review of literature. *Indian J Ophthalmol* 2003;51:81-3
11. Gysin P, Gloor B. Cryo- and photocoagulation for choroidal metastases of a thyroid carcinoma (author's transl). *Klin Monbl Augenheilkd*. 1979;174(6):978-81.
12. Guignier B, Naoun O, Subilia A, Schneegans O. Choroidal metastasis from follicular thyroid carcinoma: a rare case. *J Fr Ophthalmol*. 2011 May;34(5):329. French
13. Stoian D, Cornianu M, Dobrescu A, Lazăr F. Nodular thyroid cancer. Diagnostic value of real time elastography. *Chirurgia (Bucur)*. 2012;107(1):39-46.