

Transobturator Urethral Suspension Surgical Treatment of Urinary Incontinence in Men

O. Bratu¹, D. Mischianu¹, S. Constantinoiu²

¹Department of Urology, Emergency University Central Military Hospital "Dr. Carol Davila", Bucharest, Romania

²University of Medicine and Pharmacy "Carol Davila", General and Esophageal Surgery, "Sf. Maria" Hospital, Bucharest, Romania

Rezumat

Tratamentul chirurgical al incontinenței urinare la bărbat prin suspensie uretrală transobturatorie

Introducere: Incontinența urinară reprezintă pierderea involuntară de urină pe uretră și este o problemă majoră de sănătate în întreaga lume, mai ales prin implicațiile psiho-sociale pe care le determină. Din punct de vedere chirurgical, se impune tratamentul incontinenței urinare la bărbat în special postoperator și anume după prostatectomia radicală retropubică, transuretro-rezecția sau vaporizarea prostatei, incizia colului vezical etc.

Tehnică: Tehnica chirurgicală este similară cu cea folosită pentru incontinența urinară la femei, respectiv TOT. Plasele sau benzile utilizate sunt de polipropilenă, identice cu cele folosite la femei sau speciale pentru incontinența urinară la bărbat. Maniera de introducere transobturatorie a acelor aplicatoare poate fi "in-out" sau "out-in", în funcție de obișnuința operatorului.

Rezultate: Recuperarea postoperatorie a fost rapidă și în general fără complicații majore. Cateterul uretro-vezical s-a suprimat imediat post-procedură sau la 24 de ore postoperator, iar externarea pacienților s-a făcut după 48-72 de ore de la intervenția chirurgicală. Am observat ameliorarea incontinenței urinare încă din primele zile postoperator, iar simptomatologia a dispărut complet la 30 de zile postoperator la 80% din cazuri.

Complicații: Complicațiile intraoperatorii sunt minime și pot fi datorate leziunilor vasculare, uretrale sau vezicale, dar pot fi evitate în mâini experimentate. Tardiv, în cazuri rare, pot să apară rejetul sau ruptura meșei sau eroziuni ale uretrei.

Concluzii: Tehnica suspensiei uretrale transobturatorii folosită în tratamentul incontinenței urinare la bărbat s-a dovedit a fi eficientă. Procedeu este puțin invaziv, tehnic facil și relativ scurt ca durată a intervenției. Durata spitalizării este redusă, ceea ce face ca acest procedeu să fie eficient și din punct de vedere economic.

Cuvinte cheie: incontinență, transobturator, suspensie uretrală, post-prostatectomie, meșă

Abstract

Introduction: Urinary incontinence represents involuntary urethral loss of urine and represents a major health problem worldwide, mainly due to the psychosocial implications it determines. The surgical treatment of urinary incontinence in men is needed especially postoperatively, after radical retropubic prostatectomy, transurethral resection or vaporization of prostate, bladder neck incision etc. Surgical indications appear when all the other conservatory means of treatment have failed, including antimuscarinic medication or pelvic floor training.

Technique: The surgical procedure is similar to the one used for women, TOT to be more precise. The meshes are made of polypropylene, identical to those used for women or especially designed for urinary incontinence in men. The surgical technique can be "in-out" or "out-in" according to surgeon preferences.

Results: Postoperative recovery was fast and without major complications. The urethral catheter was removed 24 hours

Corresponding author:

Assist. Prof. Bratu Ovidiu, MD, PhD
University of Medicine and Pharmacy
"Carol Davila"
Emergency University Central Military
Hospital "Dr. Carol Davila", Urology Ward
M. Vulcanescu street, no. 88, Bucharest
E-mail: ovi78doc@yahoo.com

after the procedure and the patients were discharged 48-72 hours after surgery. After 30 days postoperative, urodynamics and abdominal echography showed no vesical residue. Success rate is about 80%.

Complications: Intraoperative complications are minimal (urethral, vascular or vesical) and can be avoided in the hands of experienced surgeons. Mesh rejection and rupture or urethral erosion can occur as rare postoperative complications.

Conclusions: Transobturator urethral suspension procedure proved to be efficient. It is a minimally invasive procedure, easy and with relatively short surgical time. Inbound time is short, making this procedure cost-effective.

Key words: incontinence, transobturator, urethral suspension, post-prostatectomy, mesh

Introduction

Urinary incontinence represents involuntary urethral loss of urine and represents a major health problem worldwide, mainly due to the psychosocial implications it determines.

In men, the incidence is reduced to a half, compared to women, and the physiopathologic mechanism is different (1). As such, the majority of men present with urinary imperiosity (40-80%) as a mechanism, next is mixed incontinence (10-30%) and finally stress mechanism (under 10%). In women, the majority of mechanism instances is represented by stress incontinence. Obviously there are other types of incontinence, such as overflow incontinence, (in prostatic and bladder neck disorders), neurological disorder incontinence (mielomeningocele, spina bifida) or idiopathic incontinence (1,2).

The surgical treatment of urinary incontinence in men is needed especially postoperatively, after radical retropubic

prostatectomy, transurethral resection or vaporization of prostate, bladder neck incision etc (3).

Surgical indications appear when all the other conservatory means of treatment have failed, including antimuscarinic medication or pelvic floor training. Based on the type of urologic pathology the surgical timing is different. So, after radical retropubic prostatectomy (for prostate adenocarcinoma) the surgical sanction is after 12 months and for transurethral procedures (for benign prostatic hyperplasia) the best surgical timing is still subject to dispute (3 months period post TUR-P or I-TUP in our clinic) (4).

Urinary incontinence in men appears most frequently after radical retropubic prostatectomy (open or laparoscopic) because of multiple causes: shortage of suprasphincteral urethra, lesions of pudendal nerve or cavernous neurovascular bundle, direct lesions of external striated sphincter, loss of sphincteral pelvic muscle tone, lesions to the sustentaculum urethrae (the so called integral theory) (5,6).

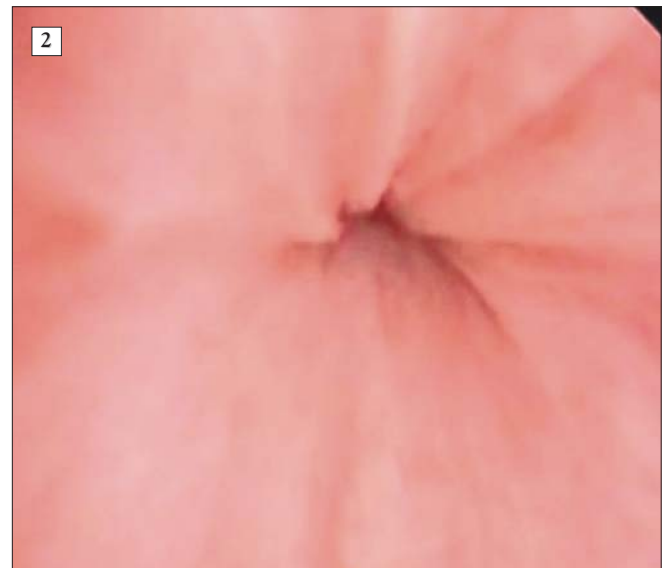
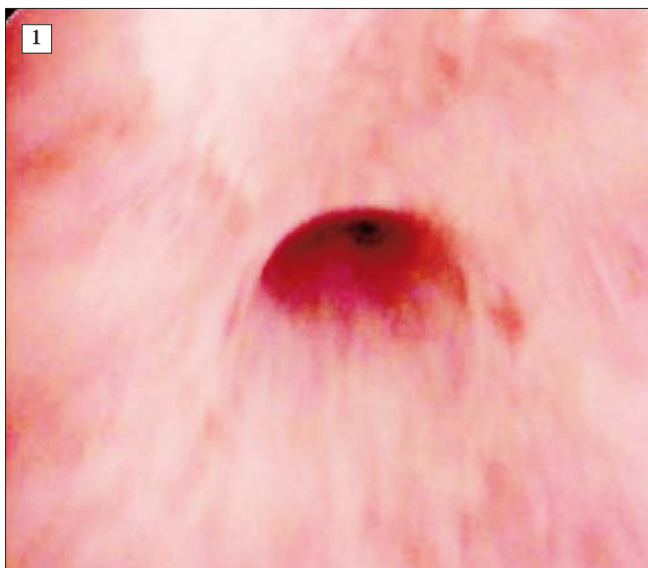Surgical technique

In the surgical treatment of urinary incontinence we used the transobturator urethral suspension technique for patients undergoing radical prostatectomy 12-14 months before, patients with extended TUR-is (for benign prostate hyperplasia) and for patients with no prior surgery but with pelvic radiotherapy or cryotherapy. We excluded patients with overflow incontinence.

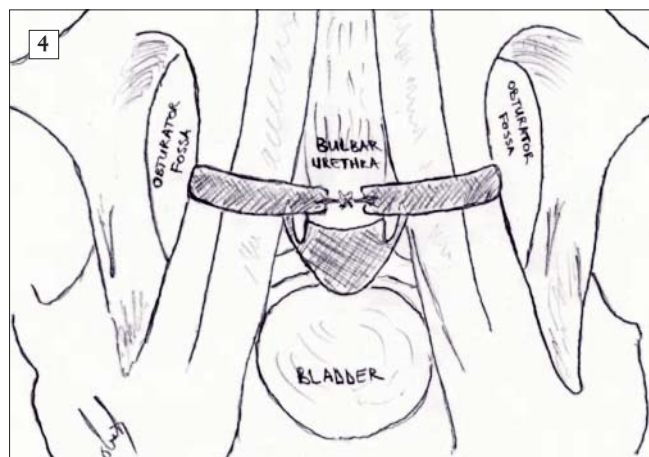
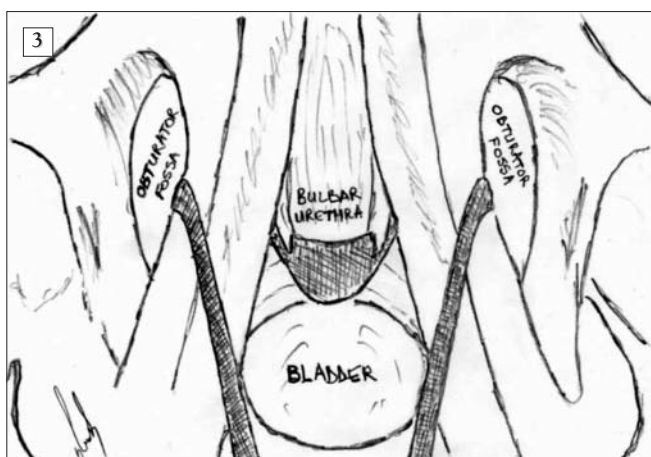
All patients underwent preoperative urodynamics, were all non-responders to conservative therapies associated detrusor instability.

Pre- and postoperative cystoscopy was performed, but this is not a routine procedure although some authors recommend and use it simultaneously with the incontinence procedure (Fig. 1, 2).

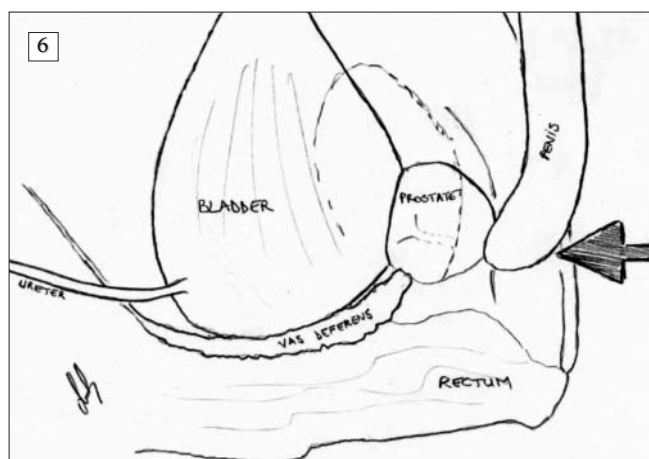
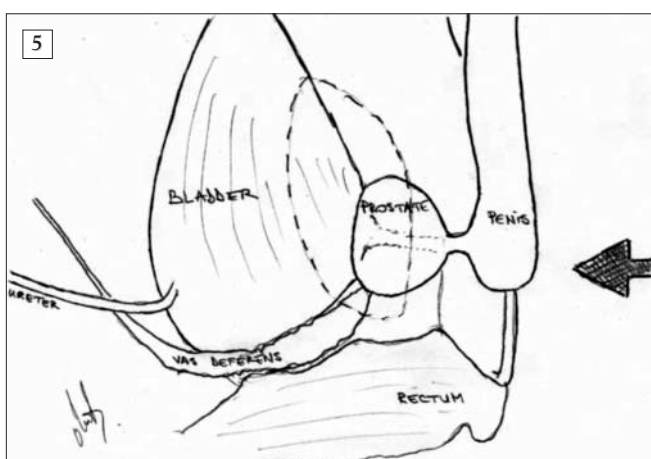
The surgical procedure is similar to the one used in



Figures 1,2. External urethral sphincter before and after the suburethral sling procedure (Cystoscopy images)



Figures 3,4. Placements modalities of suburethral slings



Figures 5,6. Principle of the procedure – pushing up the bulbar urethra

females, TOT to be more precise (Fig. 3, 4). The meshes are made of polypropylene, identical to those used for women or especially designed for urinary incontinence in men. The surgical technique can be “in-out” or “out-in” according to surgeon preferences.

Both ends of the sling can be let loose or can be tied upon the bulbar urethra and the tension applied on the sling rises the urethra 2-3 cm (this is the main principle of the procedure) (Fig. 5, 6).

Preoperative preparation is the usual one used for perineal or subumbilical surgery. Spinal anaesthesia is most frequently used, as well as lithotomy position.

Usual surgical instruments are used. In addition helical tunnelers are needed. They come in different shapes for each hand.

Intraoperatively, before starting the procedure a urethral catheter is inserted and the scrotum is elevated for ease of access.

The procedure starts with the incision of the perineum 2 cm below the scrotum midline and 2 cm above the anus (Fig. 7). Superficial then profound perineal fascia are shown then incised (Fig. 8). Bulbospongiosus and ischiocavernosus

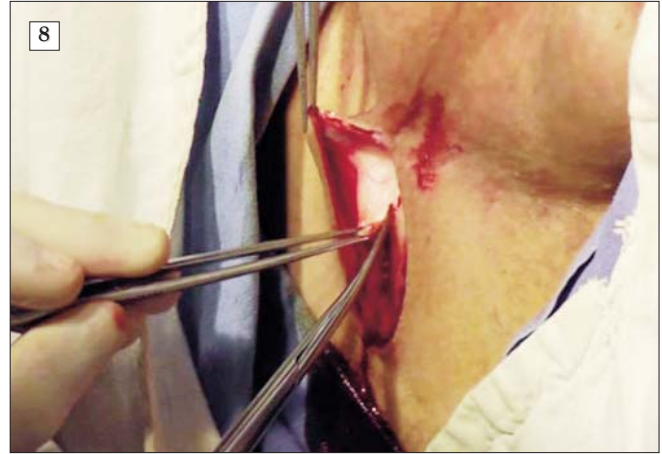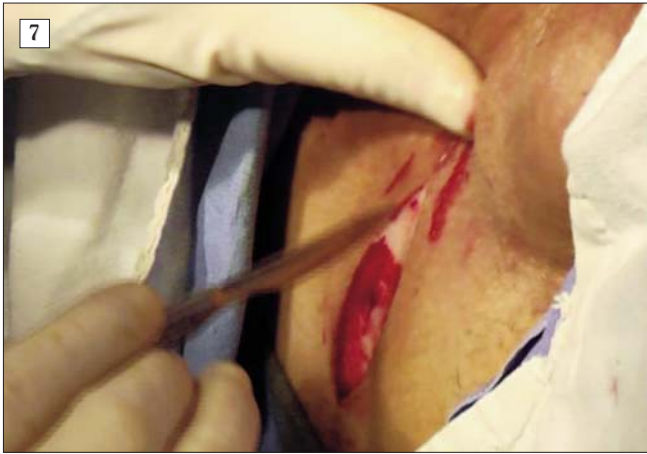muscles appear, they are dissected and dissociated until the tendinous centre of perineum (Fig. 9, 10). Care must be taken when dissecting those muscles because bulbous urethra is situated just beneath these muscles and can be wounded. Bladder catheter is used for palpatory identification of the urethra.

Bleeding is minimal up to this point and can be controlled with the cautery. Use of the electric coagulation must be avoided for the control of urethral bleeding.

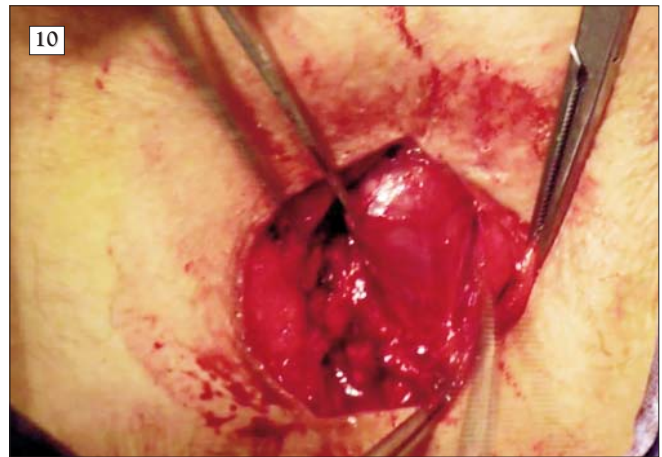
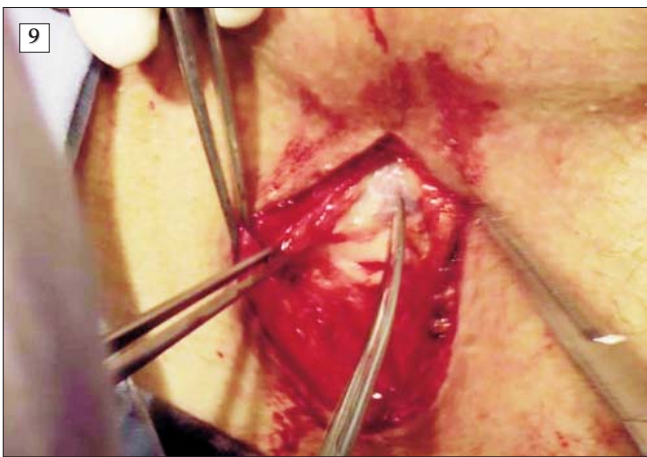
Urethra will not be dissected in the posterior. Laterally, dissection must be performed deeply, with care because of major bleeding risk. The dissected space is medially delimited by the bulbar urethra and laterally by the descending branch of pubic bone.

A skin incision on the medial margin of the descending pubic bone is performed bilaterally (Fig. 11).

The tunneler is introduced through the incision, on the lateral side of the pubis. When obturator membrane is perforated the surgeon must introduce the index in the latero-urethral space in order to identify the tunneler's tip. The helical tunneler is rotated to the exterior maintaining close contact with the bone. When the tip of the tunneler is



Figures 7,8. Incision of perineum (2 cm under the scrotal raphe and 2 cm above the anus) and incision of superficial fascia of perineum



Figures 9,10. Dissection of bulbospongiosus and ischiocavernosus muscle followed by bulbar urethra dissection until the tendinous centre of the perineum

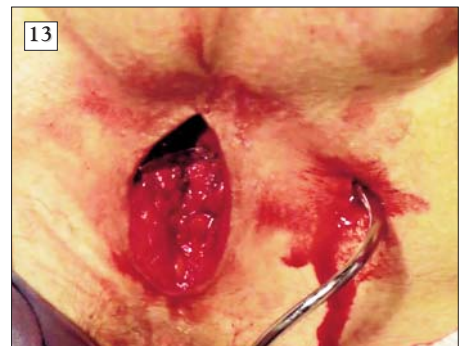
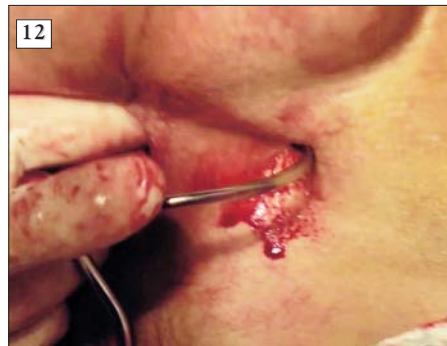
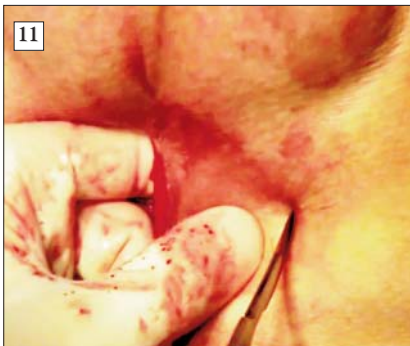Figure 11,12,13. Approximately 1 cm incision of the skin on the ischiopubic bone surface (medial side of the obturator foramen) and insertion of transobturator needle

exteriorised, urethra can be harmed. This operative procedure is performed bilaterally (Fig. 12, 13).

Obturator pedicle is not at risk when introducing the tunneler due to its anatomic position in the obturator foramen. Small pubic blood vessels can be intercepted. Occasionally haemostasis can be obtained only by compression.

The polypropylene mesh is attached to helical tunneler.

The tunnelers are retracted with a reverse rotation, also maintaining close contact with the bone. The polypropylene mesh is placed under the bulbous urethra (Fig. 14, 15).

The mesh is tightened lifting the bulbar urethra for 2-3 cm. The mesh should not be tightened excessively because of post-operative acute urine retention risk. If a clamp can be introduced between the urethra and the mesh it is considered that

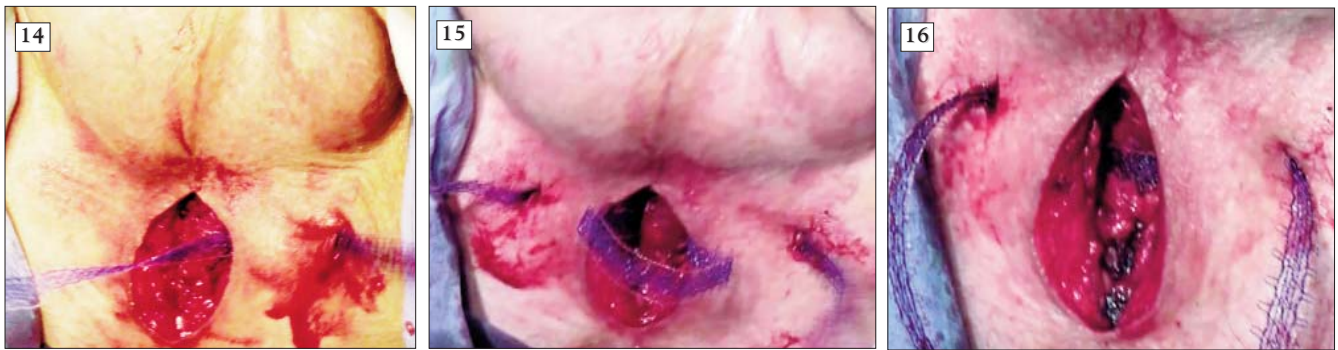


Figure 14,15,16,17. Placement of the polypropylene mesh and suspension of the bulbar urethra free or tied up for tension maintenance

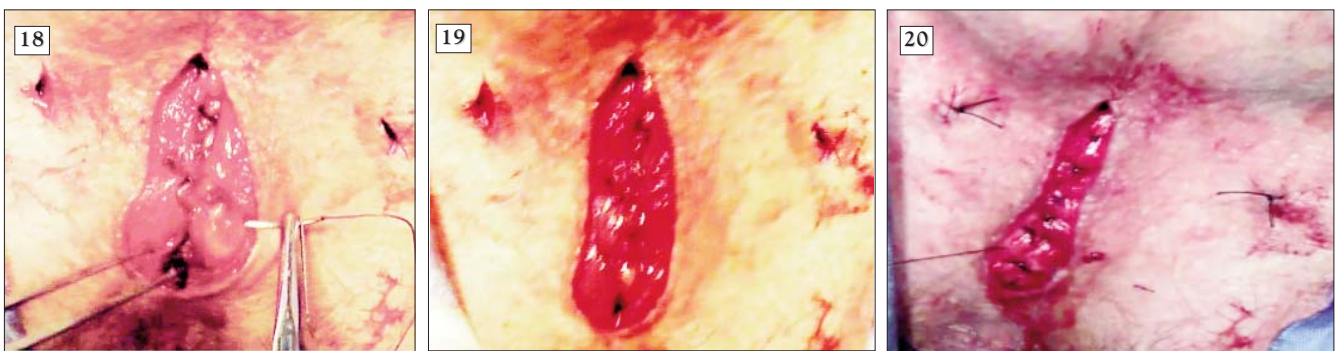
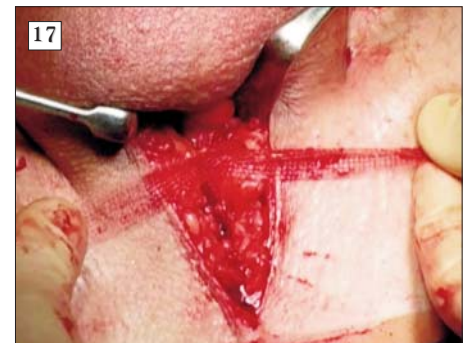
Figure 18,19,20,21. Removal of loose mesh. Anatomic repair of perineum and postoperative aspect

mesh is tensioned enough (Fig. 16, 17).

The mesh can be anchored to the urethra with a couple of absorbable sutures, care must be taken not to perforate the urethra.

Surgery can continue from this point in two ways.

The first method consists in cutting the mesh excess after it is anchored to the urethra and proceeding to the surgical wound closure (Fig. 3).

The second method consists in the reintroduction of the

exterior ends of the mesh through the same skin incision this time not transobturatory, but under muscles layer. The mesh's ends are again sewed to the urethra and the excess is cutted. This second manner is more useful in patients with very intense symptoms or a very weak sphincter shown at the cystoscopic exam (Fig. 4).

Wound closure is performed in an anatomic manner, layer by layer. No perineal drainage is needed (Fig. 18, 19, 20, 21).

Results

Postoperative recovery is fast and without major complications. Urethral catheter is removed immediately after surgery or 24 hours after the procedure and the patients were discharged 48-72 hours postoperative.

Patients are strongly advised not to perform any abdominal pressure (cough, sneeze, weight lifting). The mesh is bio-integrated in 2 to 3 weeks; this is when the patients can get back to their previous life regime. The perineal surgical wound is treated as any surgical wound. It must be cleaned daily for 4-5 days. The stitches can be removed beginning with the fifth day.

Pre- and post-voiding abdominal ultrasound is performed 30 days after surgery in order to evaluate the presence or absence of post-voiding residue. If there is any, the mesh is too tight and the patient can undertake bladder neck relaxing treatment for few months. Urodynamic studies will be performed to assess the bladder's excitability status. If symptoms persist and detrusor instability continues antimuscarinic treatment will be associated for 3-6 months.

Complications

Complications can occur both within the surgery itself and postoperative.

Within the surgery urethra and the urinary bladder can be wounded when maneuvering the tunnel. Intraoperative bleeding can occur when intercepting an abnormal pubic vessel. A lesion of the urethra or bladder can be clinically identified as gross haematuria appearing on the bladder catheter. If urinary path is intercepted the tunnel must be reintroduced through a correct path and the urinary catheter must stay in place for a longer period.

Wounding the exterior anal sphincter can occur but it is a rare complication, if dissection is performed as described above.

After the surgery, bleeding can occur if intraoperative haemostasis wasn't good enough. Urethral erosions with pus exteriorisation on the catheter or when urinating can occur. Acute urine retention, chronic pelvic pain that generally disappears spontaneously, mesh rejection as it happens in any surgical procedure with a polypropylene mesh are also postoperative complications that can occur.

Emergency surgery with extraction of the mesh is needed

in case of erosions, mesh rejections or mesh rupture. Another mesh can be placed when complete healing is accomplished.

Conclusions

We recommend porous, monofilament, polypropylene meshes with no elastic properties which are best suited for this anatomic region and have the best functional outcome.

Cystoscopy exam is recommended for assessing the functionality of the external urethral sphincter.

A urinary catheter is mandatory before starting the procedure.

Transobturator urethral suspension procedure proved to be efficient. It is a minimally invasive procedure, easy and with relatively short surgical time. Inbound time is short which makes this procedure cost-effective (1,2).

Intraoperative complications are minimal (urethral, vascular or vesical) and can be avoided in the hands of experienced surgeons.

We shall try to use this procedure in neurological diseases that cause secondary urinary incontinence, at least for the improvement of symptoms and the quality of life.

Other alternative possibilities worth mentioning are peri-urethral endourethral injection of collagen with time limited results (only one year) or artificial sphincter, an expensive procedure with a success rate of 60-80% (4).

References

1. Migliari R, Pistolesi D, De Angelis M. Polypropylene sling of the bulbar urethra for post-radical prostatectomy incontinence. *Eur Urol.* 2003;43(2):152-7.
2. Rehder P, Gozzi C. Transobturator sling suspension for male urinary incontinence including post-radical prostatectomy. *Eur Urol.* 2007;52(3):860-6. Epub 2007 Feb 12.
3. Franke JJ, Gilbert WB, Grier J, Koch MO, Shyr Y, Smith JA Jr. Early post-prostatectomy pelvic floor biofeedback. *J Urol.* 2000;163(1):191-3.
4. Cespedes RD. Collagen injection or artificial sphincter for post-prostatectomy incontinence: collagen. *Urology.* 2000;55(1):5-7.
5. Kapoor R, Dubey D, Kumar A, Zaman W. Modified bulbar urethral sling procedure for the treatment of male sphincteric incontinence. *J Endourol.* 2001;15(5):545-9.
6. Peyromaure M, Ravery V, Boccon-Gibod L. The management of stress urinary incontinence after radical prostatectomy. *BJU Int.* 2002;90(2):155-61.