

An Effective Method to Release Anastomotic Tension after Repair of Esophageal Atresia Using a Foley Catheter

E.S. Boia¹, A. Nicodin¹, M.C. Popoiu¹, M. Trailescu², V.L. David¹

¹University of Medicine and Pharmacy "Victor Babeș" Timișoara, Romania

²County Hospital, Arad, Romania

Rezumat

O metodă eficientă pentru diminuarea tensiunii anastomozelor după repararea atreziei de esofag utilizând sonda Foley

Atrezia de esofag este cea mai frecventă malformație a esofagului. Anastomoza primară este posibilă în mai mult de 90% din cazuri, iar obiectivul intervenției chirurgicale este anastomoza etanșă și fără tensiune a bonturilor esofagiene. Scopul acestei lucrări este de a prezenta o metodă nouă de diminuare a tensiunii la locul anastomozelor și totodată de a furniza o cale pentru alimentația enterală, la copiii cu atrezie esofagiană la care s-a practicat anastomoză primară. În perioada 2000 – 2012, în departamentul nostru s-a practicat anastomoză primară a esofagului, pentru atrezie congenitală, la 21 de copii. În timpul intervenției chirurgicale se inseră o sonda Foley de calibru French 12 prin una dintre narine apoi prin esofagul anastomozat până în stomac. Balonașul sondei este umflat, iar sonda este tracionată moderat și fixată cu bandă adezivă. Postoperator se menține tracțiunea sondei pentru câteva zile. Nici unul dintre cei 21 de pacienți nu a prezentat o dezinire a anastomozelor, iar o fistulă minoră a apărut la unul dintre cazuri. Rata generală de supraviețuire a fost de 67%. Considerăm că utilizarea sondei Foley transanastomotice pentru eliberarea tensiunii reprezintă o metodă ieftină și eficientă pentru

îmbunătățirea rezultatelor în tratamentul atreziei de esofag la copil.

Cuvinte cheie: atrezia de esofag, sonda transanastomotică, anastomoza esofagiană primară

Abstract

Esophageal atresia (EA) is the most common malformation of the esophagus. Primary anastomosis is achievable in more than 90% of the cases and the milestone of the surgical intervention is achieving a watertight, low-tension anastomosis of the esophageal pouches. The purpose of this paper is to present a new method for releasing tension in the anastomosis and also to provide a safe way for enteral feeding in children with primarily repaired EA. From 2000 to 2012 twenty-one patients underwent primary esophageal anastomosis for EA in our department. During the surgical intervention, a 12-french Foley catheter is inserted through one of the nostrils, through the esophagus down to the site of the anastomosis and passed by into the stomach. After surgery, continuous gentle traction is maintained on the catheter for several days. We had no post-operative disruption of the anastomosis and anastomotic leaks occurred in 1 of the 21 cases. Overall survival rate was 67%. Using the Foley catheter to protect the anastomosis and to release the tension of the sutures provides a cheap and effective means to improve the outcomes of the treatment of EA

Key words: esophageal atresia, transanastomotic catheter, primary esophageal anastomosis

Corresponding author:

Vlad-Laurentiu David, MD
University of Medicine and Pharmacy
"Victor Babeș" Timișoara, Romania
Dr. Iosif Nemoianu Street, No 1-2, 300011
Timișoara, Romania
Fax +40 256 201976
E-mail: david.vlad@yahoo.com

Introduction

Esophageal atresia (EA) is the most common malformation of the esophagus (1). Nowadays the overall survival rate for EA after surgical repair is near to 95% (1). Primary anastomosis is achievable in more than 90% of the cases and the milestone of the surgical intervention is achieving a watertight, low-tension anastomosis of the esophageal pouches (1, 2). A tensioned anastomosis contributes not only to the risk of anastomotic leakage, but also to the risk for stricture or may stretch the distal esophagus providing an etiology for subsequent gastro-esophageal reflux (1,2,3,4). Conventionally a gap between the two pouches less than 2 vertebral bodies or (1 cm) is considered small enough to ensure a safe, tension free primary anastomosis (1,5). A gape longer than 3 vertebral bodies or 2 cm is considered long and supplementary measures are necessary in order to perform a primary anastomosis (6). Various maneuvers have been proposed to overcome a wide gap: extended mobilization of the esophageal pouches (7,8), tubularisation of the upper pouch after creating a flap (9), circular myotomy of the upper pouch (10) or abandoning any attempt at initial primary anastomosis awaiting delayed primary anastomosis or esophageal reconstruction interposing segments of the stomach (11,12), small intestine (13) or colon (6). Complication of these measures include: long-term esophageal dysfunction after myotomy, fibre damage from overstretching the esophageal muscle and dysmotility, perforation and mediastinitis from suture detachment of the tubularised esophagus (1,2,3,6,14).

One of the main factors influencing the postoperative course of the patient is the onset of early enteral feeding. Insertion of a nasogastric tube during surgery for EA will allow early enteral feeding without the risk of gastro-esophageal reflux and/ or disruption of the esophageal suture (15).

The purpose of this paper is to present a new method for releasing tension in the anastomosis and also to provide a safe

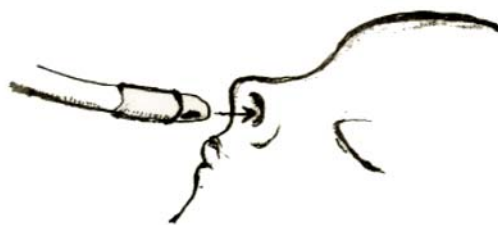


Figure 1. Inserting the Foley catheter through one of the nostrils

way for enteral feeding in children with primarily repaired EA. By using a Foley catheter inserted through the anastomosed esophagus in the stomach we were able to ensure a safe way for enteral feeding, prevent gastro-esophageal reflux and release the tension of the suture. This paper presents the surgical procedure and briefly analyzes the results of this surgical method for the repair of EA in children.

Material and Methods

Surgical procedure

The intervention is performed through a classical right thoracotomy. The esophageal is reached through an extrapleural approach and after the fistula is ligated the two esophageal pouches are mobilized as much as possible in order to achieve a minimum gap between them, without extensive dissection. The two pouches are approached among each other and the posterior half of the anastomosis is performed. A 12-french Foley catheter is inserted through one of the nostrils (Fig. 1), through the esophagus down to the site of the anastomosis (Fig. 2). The catheter is pushed further by the surgeon through the distal esophagus and passed into the stomach (Fig. 3). The balloon is then inflated in the stomach and gentle tension is applied to the Foley catheter (Fig. 4).

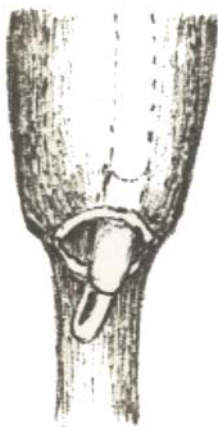


Figure 2. Passing the catheter through the anastomosis

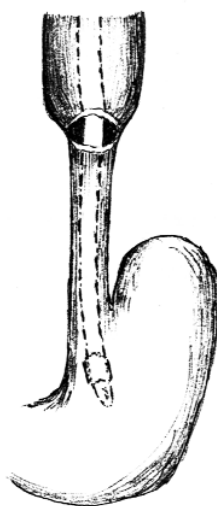


Figure 3. Inserting the catheter into the stomach

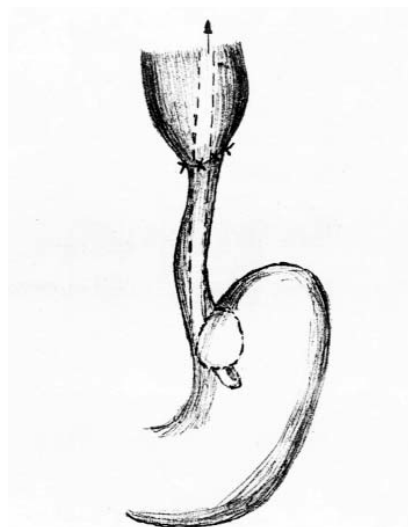


Figure 4. After the balloon is inflated traction is applied to the catheter

The catheter is then fixed to the nose with adhesive tape holding a degree of traction in order to release tension in the anastomosis. The anastomosis is completed anteriorly and the surgical procedure is concluded in the usual manner. Postoperatively the catheter is held in position for 7 days and it also serves for introducing early enteral feeding. Oral, pharyngeal and esophageal secretions are aspirated every 3-4 hours to prevent accumulation in the esophagus and consequent aspiration in the respiratory tract.

From 2000 to 2012 twenty one patients (9 girls and 12 boys) underwent primary esophageal anastomosis for EA. The average birth weight was 2567g ranging from 1800 to 3400g, nine of them having less than 2500g. Associated malformations were present in 10 cases, the majority of them involving cardiac (3), limb malformations (2) and anorectal malformations (1) (Table 1). Esophageal anastomosis was carried out after a median of 62 h after birth. There were 19 EA (90%) with distal fistula, 1 with proximal fistula and one with proximal and distal fistula.

For statistical analysis we used SPSS v19 for Windows.

Results

Complications occurred in 66 % of the cases (Table 2). Overall survival rate was 67%. The majority of the complications were related to lung infection due to prolonged intubation, prematurity and pulmonary immaturity ($p < 0.05$). Sepsis occurred in 8 patients and was associated with higher mortality rates ($p < 0.05$).

None of the other factors, such as cardiac malformations, anorectal malformations, time to surgical intervention had significance over the survival rate, except low birth weight ($p = 0.02$). Anastomotic leaks occurred in 1 of the 21 cases causing mediastinitis, septic shock and death. We had no postoperative disruption of the anastomosis. We did not notice any necrosis of the stomach or of the lower esophagus related to the pressure produced by the Foley balloon.

Discussions

The present study intends to analyze the benefits of our improvement to the treatment of EA. Releasing the tension in the anastomosis, theoretically speaking, should favour the healing and prevent anastomotic leakage or stricture. Previous studies concluded that anastomotic leaks occur in 15–20% of patients, but in only one-third or less did a major disruption appear (16,17). Major leaks may produce life-threatening tension pneumothorax during the first 48 hours (16). Minor leaks are more common and usually have benign course, healing spontaneously, but with increased incidence of stricture formation (16). Mediastinitis complicates both major and minor anastomotic leaks and is usually the cause of severe sepsis or septic shock and death. In our series, leaks occurred in one case (4% of the cases) followed by mediastinitis, severe sepsis and death. As a matter of fact, in our series, the main causes of death were bronchopulmonary infections and not anastomotic leak or disruption. Actually, in 6 of the 7

Table 1. Associated malformations

Malformation	No. of cases
Cardiac malformations	
Atrial septal defect	2
Patent ductus arteriosus	1
Anorectal malformation	1
Unilateral renal agenesis	1
Cryptorchidism	1
Hypospadias	1
Club foot	1
Hemimelia	2

Table 2. Complications

Complications	No. of cases
Bronchopneumonia	9
Sepsis	8
Anastomotic leak	1
Hemothorax	1
Deaths	7

deceased patients, the direct cause was septic shock due to bronchopulmonary infection. The origin of the infection can only be found in a sum of factors: prematurity, low birth weight, pulmonary immaturity, prolonged tracheal intubation and mechanical ventilation.

First Waterston (18) and then Spitz (19) proposed risk classification for EA based on birth weight and associated cardiac malformation. In our series, we found only the low birth weight to have significant influence over the survival of the patients. Cardiac malformations, despite being present in 3 cases (14%), had no statistical significance for mortality ($p > 0.05$). Perhaps more important, and in conjunction with the declared purpose of this study is that we found no association between the anastomotic leaks and mortality, and that complications after anastomotic leaks occurred only in 1 patient (4%), which is far less frequent than previously presented rates (16,17). These findings may be indications that stress releasing by means of the transanastomotic traction of the Foley catheter has positive influence. Moreover, we found no postanastomotic strictures or gastro-esophageal reflux disease in the survivors, but we cannot affirm with confidence that this was the effect of the Foley catheter due to the small amount of patients available for long-term follow up.

Critics of this method may argue that, similar to well-known Stengstaken-Blakemore tube complications (20), the continuous traction and consequent pressure of the balloon on the stomach and lower esophagus will eventually lead to local necrosis. None of the patients treated by us by this method presented this kind of complication. The absence of this complication in our series of patients is in our opinion the consequence of two facts: the balloon of the Foley catheter is inflated only inside the stomach and puts no pressure on the lower esophagus and, secondly, the compliance and the quality of the esophageal and stomach mucosa are different than those of patients suffering from esophageal varices and esophagitis.

Moreover, there is no need in newborn patients for such high traction forces like those applied in adults or older children with esophageal varices.

The improvement to the surgical procedure - proposed by us - is simple, produces no harm, is cheap and is effective in releasing the tension in the anastomosis. All previously described surgical techniques indicated the importance of placing a transanastomotic catheter and maintaining it for 5 to 7 days in order to protect the sutures (1,2,3,15,16). We made a step further and proposed an innovation that is more effective in protecting the esophageal sutures and promoting healing.

Conclusions

Using the Foley catheter to protect the anastomosis and to release the tension of the sutures provides a cheap and effective means to improve the outcomes of the treatment of EA. EA remains a milestone for the pediatric surgeon and despite of the progresses in the medical world there is still a high rate of mortality.

References

- Spitz L. Esophageal atresia. Lessons I have learned in a 40-year experience. *J Pediatr Surg.* 2006;41(10):1635-40.
- González-Hernández J, Lugo-Vicente H. Esophageal atresia: new guidelines in management. *Bol Asoc Med P R.* 2010;102(1):33-8.
- Séguier-Lipszyc E, Bonnard A, Aizenfisz S, Enezian G, Maintenant J, Aigrain Y, et al. The management of long gap esophageal atresia. *J Pediatr Surg.* 2005;40(10):1542-6.
- Nagaya M, Kato J, Niimi N, Tanaka S, Iio K. Proposal of a novel method to evaluate anastomotic tension in esophageal atresia with a distal tracheoesophageal fistula. *Pediatr Surg Int.* 2005; 21(10):780-5. Epub 2005 Oct 21.
- Brown AK, Tam PK. Measurement of gap length in esophageal atresia: a simple predictor of outcome. *J Am Coll Surg.* 1996; 182(1):41-5.
- Naik-Mathuria B, Olutoye OO. Foregut abnormalities. *Surg Clin North Am.* 2006;86(2):261-84, viii.
- Lessin MS, Wesselhoeft CW, Luks FI, DeLuca FG. Primary repair of long-gap esophageal atresia by mobilization of the distal esophagus. *Eur J Pediatr Surg.* 1999;9(6):369-72.
- Davison P, Poenaru D, Kamal I. Esophageal atresia: primary repair of a rare long gap variant involving distal pouch mobilization. *J Pediatr Surg.* 1999;34(12):1881-3.
- Gough MH. Esophageal atresia-use of an anterior flap in the difficult anastomosis. *J Pediatr Surg.* 1980;15(3):310-1.
- Livitidis A. Esophageal atresia: a method of overbrindgin large segment gaps. *Z Kinderchir.* 1973;13:298-306.
- Borgnon J, Tounian P, Auber F, Larroquet M, Boeris Clemen F, Girardet JP, et al. Esophageal replacement in children by an isoperistaltic gastric tube: a 12-year experience. *Pediatr Surg Int.* 2004;20(11-12):829-33. Epub 2004 Jul 9.
- Spitz L, Kiely E, Pierro A. Gastric transposition in children: a 21-year experience. *J Pediatr Surg.* 2004;39(3):276-81; discussion 276-81.
- Bax NM, Van Renterghem KM. Ileal pedicle grafting for esophageal replacement in children. *Pediatr Surg Int.* 2005; 21(5):369-72. Epub 2005 Apr 13.
- Brătucu E, Lucenco L. Gastroesophageal reflux disease - current trends. *Chirurgia (Bucur).* 2012;107(2):147-53.
- Sweed Y, Bar-Maor JA, Shoshany G. Insertion of a soft silastic nasogastric tube at operation for esophageal atresia: a new technical method. *J Pediatr Surg.* 1992;27(5):650-1.
- Spitz L. Oesophageal atresia. *Orphanet J Rare Dis.* 2007; 2:24.
- Chittmittrapap S, Spitz L, Kiely EM, Brereton RJ. Anastomotic leakage following surgery for esophageal atresia. *J Pediatr Surg.* 1992;27(1):29-32.
- Waterston DJ, Carter RE, Aberdeen E: Oesophageal atresia: tracheo-oesophageal fistula. A study of survival in 218 infants. *Lancet.* 1962;1(7234):819-22.
- Spitz L, Kiely EM, Morecroft JA, Drake DP: Oesophageal atresia: at-risk groups for the 1990s. *J Pediatr Surg.* 1994; 29(6):723-5.
- Seet E, Beevee S, Cheng A, Lim E. The Sengstaken-Blakemore tube: uses and abuses. *Singapore Med J.* 2008;49(8):e195-7.