

## Laparoscopic Treatment of Perforated Duodenal Ulcer - A Multicentric Study

F. Vărcuș<sup>1</sup>, F. Lazăr<sup>1</sup>, M. Beuran<sup>2</sup>, I. Lica<sup>2</sup>, C. Turculeț<sup>2</sup>, E.A. Nicolau<sup>2</sup>, R. Anghel<sup>2</sup>, F. Iordache<sup>2</sup>, G. Jinescu<sup>2</sup>, C. Murgu<sup>2</sup>, D. Vintilă<sup>3</sup>, C. Neacșu<sup>3</sup>, C. Bradea<sup>3</sup>, Șt.O. Georgescu<sup>3</sup>, R. Popescu<sup>4</sup>, V. Sârbu<sup>5</sup>, D. Sabău<sup>5</sup>, A. Dumitra<sup>5</sup>, A. Sabău<sup>5</sup>, N. Antonescu<sup>5</sup>, A. Coman<sup>5</sup>, A. Picu<sup>5</sup>, V. Bințișan<sup>6</sup>, C. Ciuce<sup>6</sup>

<sup>1</sup>"Victor Babeș" University of Medicine and Pharmacy, Surgical Department 2, Timișoara, Romania

<sup>2</sup>"Carol Davila" University of Medicine and Pharmacy, Surgical Department, Clinic Emergency Hospital, Bucharest, Romania

<sup>3</sup>"Gr.T. Popa" University of Medicine and Pharmacy, Surgical Department 2, Iași, Romania

<sup>4</sup>Faculty of Medicine, Surgical Department 2, Constanța, Romania

<sup>5</sup>"Victor Papiilian" Faculty of Medicine, Surgical Department 2, Sibiu, Romania

<sup>6</sup>"Iuliu Hațieganu" University of Medicine and Pharmacy, Surgical Department 1, Cluj-Napoca, Romania

### Rezumat

#### *Tratamentul laparoscopic al ulcerului duodenal perforat – studiu multicentric*

**Scop:** Acest studiu și-a propus să evalueze rezultatele tratamentului laparoscopic al UDP efectuat în 6 centre din România cu experiență în chirurgia laparoscopică.

**Material și metodă:** Între 1996 și 2005 în centrele care au participat la realizarea acestui studiu retrospectiv au fost operați 186 de pacienți cu ulcer duodenal perforat, toți fiind ASA I-II. La 39 (20,0%) dintre aceștia a fost vorba de peritonită ușoară, la 120 (64,5%) peritonită medie, iar la 27 (15,5%) peritonită severă mai veche de 6 ore. La 74 (39,8%) pacienți, s-a practicat sutura simplă, la 110 (59,1%) pacienți sutura cu epiplonoplastie, la 1 (0,5%) pacient doar epiplonoplastie și la 1 (0,5%) pacient excizia și sutura perforației.

**Rezultate:** Timpul operator a fost cuprins între 30-120 de minute, cu o medie de 75 de minute. Nu s-a înregistrat nici un deces. Timpul mediu de spitalizare a pacienților a fost de 6 zile, cu perioade cuprinse între 3-18 zile. Complicațiile postoperatorii

au constat în: 5 (2,6%) infecții ale peretelui abdominal, 1 (0,5%) fistulă duodenală, 1 (0,5%) abces intraabdominal, 1 (0,5%) hemoragie digestivă superioară prin "ulcer în oglindă" și 1 (0,5%) stenoză duodenală la 6 luni postoperator. Pacienții au primit cu 50% mai puține medicamente antalgice, au consumat cu 70% mai puține pansamente, cu 30% mai puține antibiotice și au avut cu 60% mai puține complicații comparative cu cei operați pe cale clasică.

**Concluzie:** Abordul laparoscopic al ulcerului duodenal perforat reprezintă alegerea de elecție în cazul pacienților fără comorbidități importante, permițând recuperarea rapidă și reducerea semnificativă a consumului de analgice, antibiotice și materiale de pansament.

**Cuvinte cheie:** ulcer duodenal perforat, chirurgie laparoscopică, peritonită, urgențe abdominale

### Abstract

**Aim:** The aim of this study is to evaluate the results of the laparoscopic treatment of perforated duodenal ulcer performed in 6 Romanian surgical centres with experience in the field of laparoscopic surgery.

**Material and Method:** Between 1996 and 2005, 186 patients with perforated duodenal ulcer were operated on in the centers participating in this retrospective study, all patients being ASA I-II. Thirty-nine patients (20.0%) presented mild peritonitis, 120 (64.5%) medium peritonitis and 27 (15.5%) severe

Corresponding author:

Flore Vărcuș, PhD, MD  
Clinical Emergency County Hospital  
I. Bulbuca Street, No. 10, Timișoara  
Romania  
Fax: 004-025.6273872  
E-mail: varcus.florian@yahoo.com

peritonitis exceeding 6 hours of evolution. For 74 patients (20.0%) simple suture was performed, in 110 (59.1%) suture with epiploonoplasty, for 1 (0.5%) only epiploonoplasty and 1 (0.5%) underwent excision of the perforation and suture.

**Results:** The operative time was between 30-120 minutes, with an average of 75 minutes. No death was noted. Average hospitalization time was 6 days, with periods varying between 3 and 18 days. Postoperative complications included: 5 patients (2,6%) presented infections of the abdominal walls, 1 patient (0.5%) duodenal fistula, 1 patient (0.5%) intra-abdominal abscess, 1 patient (0.5%) a superior digestive hemorrhage by "mirrored ulcer" and 1 patient (0.5%) duodenal stenosis 6 months after operation. The patients were administered 50% less analgesics, used 70% less dressings, 30% less antibiotics and had 60% less complications in comparison with those operated by the classical approach.

**Conclusion:** The laparoscopic approach of perforated duodenal ulcer constitutes the first choice for patients without important co-morbidities, allowing a quick recovery and a significant reduction in the consumption of analgesics, antibiotics and dressing materials.

**Key words:** perforated duodenal ulcer, laparoscopic surgery, peritonitis, emergency

## Introduction

Surgical interventions for perforated duodenal ulcer (PDU) have decreased substantially because of the treatment with proton pump inhibitors. The medication for eradicating *Helicobacter Pylori* has improved even more the medical therapy performance in duodenal ulcer (1). Even if less frequent, due the successful medication treatment, ulcer perforation can still occur in up to 10% of the patients suffering from ulcer (2), in some of them representing the onset event.

The laparoscopic approach of the PDU treatment, according to Ph. Mouret and L.K. Nathanson publications in 1990 (3,4), has represented an important step forward in the surgery of this complication type. In Romania, this procedure has been practised in the clinics of the university centres since 2000.

It is not easy to evaluate the outcomes of laparoscopic treatment in perforated duodenal ulcer because there are less and less cases with this kind of pathology. Hence, studies on large series of patients (even multicentric studies) were difficult to be carried out. Though less frequent than before applying the treatment with proton pump blockers, in Romania PDU has been treated for the last twenty years in emergency surgery, making this multicentric study possible.

The aim of this retrospective study was to evaluate the results of laparoscopic treatment in PDU, performed in six Romanian surgical centres with experience in laparoscopic surgery.

## Material and Methods

Between 1996 and 2005, 186 patients with perforated duodenal ulcer were operated on in the 6 centres participating in this study. Out of them, 35 (18.2%) were females and 151 (81.8%) males. Their age ranged between 18 and 64 years, with an average of 42.5 years (Fig. 1). The preoperative diagnosis was established based on clinical signs (pain, muscle contraction) and radiological signs (pneumoperitoneum).

As to medical preoperative treatment, 11 patients (5.9%) followed an appropriate antiulcer therapy whereas 72 patients (38.7%) underwent no preoperative antiulcer treatment. In 103 patients (55.4%), perforation and peritonitis were the first manifestation of an unknown duodenal ulcer. Associated diseases (respiratory, digestive, urinary and so forth) were encountered in 53 of the operated patients, but all surgically treated patients were ASA I and II. In principle, the ASA III and IV patients with perforated ulcer were treated by classical procedure.

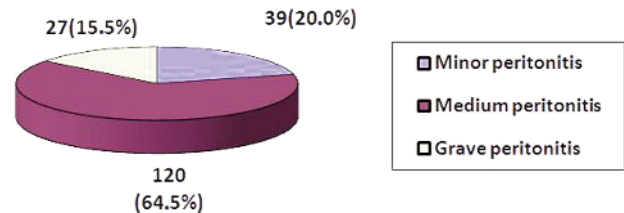
In 111 cases (59.67%), the operation was performed following the American position, 75 patients (40.32%) underwent the surgical treatment according to the French position. The pneumoperitoneum pressure ranged between 12-13 mm Hg. In 93 patients (50.0%) three trocars were used, in 64 (34.4%) four, whereas in 27 patients (14.6%) five trocars.

All operated patients presented signs of peritoneal irritation. In 39 patients, meaning 20.0% of the patients, a mild peritonitis, blocked/inhibited or with a small liquid quantity in the peritoneal cavity was registered. Medium peritonitis with a moderate liquid quantity and false membranes was identified in 120 patients (64.5%) whereas generalized severe peritonitis exceeding 6 hours from its onset was noticed in 27 patients (15.5%) (Fig. 1).

In 9 patients (4.8%) the perforation was pinpointed, in 135 (72.5%) its size was < 5 mm and in 42 patients (22.7%) it was between 5 and 10 mm (Table 1).

As to surgical procedure, in 74 patients (39.8%) simple suture was performed, in 110 patients (59.1%) suture with epiploonoplasty, in 1 patient (0.5%) only epiploonoplasty and 1 patient (0.5%) underwent excision and perforation suture. All patients received an abundant peritoneal cavity lavage (Table 2).

The abdominal toilet was performed in all operated patients. Saline was used for peritoneal lavage. In 16 patients



**Figure 1.** Patients according to the gravity of the peritonitis

**Table 1.** The size of the perforations

The dimension of the perforations	Number (%)
Millimeter perforation	9 (4.8%)
< 5 mm	135 (72.5%)
5-10 mm	42 (22.7%)

(8.6%) < 3l, in 159 patients (85.5%) 3-5l and in 11 (5.9%) > 5l were used.

The peritoneal cavity was drained in all cases. One to four drainage tubes were utilized. One drainage tube, placed subhepatically, in 25 patients (26.6%), two tubes (subhepatic location + Douglas + splenic space) in 7 patients (7.5%), and four tubes (a subdiaphragmatic drainage left + the three previous ones) in 2 patients (2.1%).

The drainage tubes were preserved for 2 to 10 days with a mean duration of 5 days.

The nasogastric tube was systematically used in 169 patients (90.9%) whereas 17 (9.1%) had no tube or probe. Liquids readministration after 24 hours was allowed in 96 patients (51.6%). The other 90 patients (48.4%) received liquids only after the obvious onset of the bowel gas. The moment of restarting eating was decided and implicitly chosen depending on the severity of the peritonitis and perforation size.

Throughout the postoperative time, dressings, infused analgesic medication, antibiotherapy and hospital stay were quantified.

## Results

The operative time was between 30 – 120 minutes, with an average of 75 minutes. The duration depended both on the surgeon's experience and on the complexity and severity of the peritonitis. For all surgical teams, the operating time was longer in the first cases. Once experience acquired, this time was gradually shorter. The surgeons participating in this study have estimated that an experienced surgeon, at least in laparoscopic cholecystectomy, needs 10 interventions for PDU in order to achieve an optimal operating time.

There were no conversions to classical technique. In some cases, a larger perforation hole and friable edges, 2-3 threads were set at a distance from ulcer edges, sutures were made by joining the edges, putting them into contact, and then plated with epiplon.

No death was registered one month after surgery.

There was no inconsistency between the preoperative and the intraoperative diagnoses.

Bowel transit was started between 1-6 days, with a mean duration of 3 days. The mean hospital stay was of 6 days, with periods between 3-18 days.

Postoperative complications consisted in: 5 (2.6%) abdominal wall infections, 1 (0.5%) duodenal fistula, 1 (0.5%) intraabdominal abscess, 1 (0.5%) superior digestive hemorrhage by "mirror ulcer" and 1 (0.5%) duodenal stenosis 6 months after the operation (Table 3).

The patients treated in these clinics by laparoscopic

**Table 2.** Surgical procedures performed

Procedures	Number (%)
Simple suture	74 (39.8%)
Suture and epiplooplasty	110 (59.1%)
Epiplooplasty	1 (0.5%)
Excision and suture of the perforation	1 (0.5%)

**Table 3.** Postoperative complications

Complications	Number (%)
Abdominal wall infections	5 (2.6%)
Duodenal fistula	1 (0.5%)
Intraabdominal abscess	1 (0.5%)
Superior digestive hemorrhage	1 (0.5%)
Duodenal stenosis	1 (0.5%)

procedures were administered the same perfusion quantity, but received 50% less antialgic medication, consumed 70% less dressings, 30% less antibiotics and presented 60% less complications. At the beginning, the duration of hospital stay was equal to that of the patients operated classically. Once experience was acquired, the stay registered a shortening tendency to 4-6 days.

## Discussions

Despite the successful medication therapy applied in duodenal ulcer, perforation still remains an encountered complication, requiring an emergency surgical treatment.

Prior to laparoscopic treatment, the classical surgery approach dominated the field of perforated duodenal ulcer, despite of studies pointing out that healing of perforated ulcer can be reached by conservative medical treatment - Taylor Method (5) – in 75-80% of the cases (6). Surgical treatment was, however, preferred because conservative therapy was marked by more complications, mainly in elderly patients.

Laparoscopic approach occurred in a favourable moment. Due to antisecretory medication efficiency, the surgical intervention aimed only at perforation hole closing, another intervention intercepting gastric secretory mechanisms not being necessary. Generally, this was accomplished by perforation suture (simple or with omentoplasty), by omentoplasty only or by using a biological adhesive (8,9,10). What is still to be solved is the fear of bacteria dispersion engendered by pneumoperitoneum (11), the risk of duodenal fistulae occurrence and, mainly, the risk of residual abscesses in the peritoneal cavity.

In this study, either the French or the American position have been chosen by the surgeon. Romanian surgeons have preferred the American position since most of them practise cholecystectomy in this position. Furthermore, the positioning of the patient on the surgery table is simpler than in case of the patient with spread legs. This explains why 33% of the surgeons prefer to operate PDU from the left side of the patient

(12), according to 29 worldwide studies.

The number of trocars was diminished once experience in laparoscopic approach was acquired. At the end of the study, most surgeons used 3 trocars.

This is due to the fact that duodenal perforation to be sutured is at the anterior liver edge. No other additional instrument was required for its raising. According to available literature data, 60% of the surgeons would use 4 trocars and 30% 3 trocars with identical outcomes.

The operative time duration depended on the surgeon's training and the lesion type. Since the onset of the laparoscopic approach, authors have agreed that more time is consumed mostly with the peritoneal cavity cleaning than with the ulcer suture itself (13).

There were no conversions in our study, a fact reported by other authors as well (14,15). This is due to the surgeons experienced in laparoscopic treatment and emergency who performed the surgical interventions, even when the operations were performed during night duty. In some cases with perforations of friable edges, the suture was made with difficulty. In these cases, the suture thread was passed far from the friable edges and intracorporeal sutures/knots were softly made – no tightening – and the edges joined. A part of the epiploon was brought over this suture.

Treatment in most cases was suture with epiploonoplasty. In approximately 40% of the patients a simple suture was performed. No considerable evolutionary difference between those two types of operations was noticed. According to our experience, epiploonoplasty is thought to be necessary, especially when the perforation hole is larger and where the edges are friable. In small perforations with good margins, simple suture is sufficient (16). Some authors have reported efficient results performing only perforation plating with epiploon or using biological adhesives (17).

The flowing lavage of the peritoneal cavity is of utmost importance. In our opinion, based on the experience acquired, the fears of some surgeons that laparoscopic approach might not allow a proper lavage, with false membrane removal, giving thus room to residual abscesses, are unjustified. Our experience confirms the remarks of those authors who sustain laparoscopic peritoneal lavage to be more efficient than in open surgery, since it allows a more successful exploration of the peritoneal cavity than by a xiphosupraumbilical incision.

The number of drainage tubes was diminished once experience was acquired. At present, most teams leave only one tube in the peritoneal cavity after an abundant lavage. The tube is usually placed in the right subhepatic location. A meta-analysis on 29 studies regarding laparoscopic PDU has shown that on 21% of the operated patients no draining tube was left. No notable complications were reported (12).

At first, oral feeding was resumed cautiously. Towards the end of the period under study liquid ingestion started 24 hours after the operation (18). Exceptionally, less disciplined patients took out the nasogastric tube 12 hours after the operation and started nutrition with solid food. No complications were reported.

The outstanding results highlighted in our study are due

to the surgeons experienced in laparoscopic treatment and emergency since all the clinics taking part in this study have always included an experienced surgeon (as a rule the chief of the team) in the duty team. There were no deaths registered. Only ASA I and II patients underwent laparoscopic treatment. Most studies on laparoscopically treated PDU reporting deaths included ASA III and ASA IV patients with associated pathology. Hence, in a metaanalysis including 29% ASA III and IV patients, an average mortality of 5.8% (12) was registered.

In our study, the postoperative results were as good as in severe peritonitis since laparoscopic approach has allowed a very efficient peritoneal lavage, a fact confirmed by other authors as well (19,20).

## Conclusion

This study shows that laparoscopic approach of perforated duodenal ulcer is feasible; the procedure is safe with no risk increase of duodenal fistulae or residual intraperitoneal abscesses. It points out the advantage of decreasing postoperative pain and abdominal wall infections as well as a reduction in antibiotherapy and material consumption. These reasons in view, based on the accumulated experience, the authors have considered that laparoscopic approach of perforated duodenal ulcer represents the election method in the surgical treatment of this complication.

## References

1. Yeomans ND. Overview of 50 years' progress in upper gastrointestinal diseases. *J Gastroenterol Hepatol.* 2009;24 suppl 3:S2-4.
2. Druart ML, Van Hee R, Etienne J, Cadière GB, Gigot JF, Legrand M, et al, Yvergneaux JP. Laparoscopic repair of perforated duodenal ulcer. A prospective multicenter clinical trial. *Surg Endosc.* 1997;11(10):1017-20.
3. Mouret P, François Y, Vignal J, Barth X, Lombard-Platet R. Laparoscopic treatment of perforated peptic ulcer. *Br J Surg.* 1990;77(9):1006.
4. Nathanson LK, Easter DW, Cuschieri A. Laparoscopic repair/peritoneal toilet of perforated duodenal ulcer. *Surg Endosc.* 1990;4(4):232-3.
5. Taylor H. Perforated peptic ulcer treated without operation. *Lancet.* 1946;2(6422):441-4.
6. Crofts TJ, Steele RJC, Cheung SCS, Park K, Li AKC. Prospective randomised controlled trial of conservative therapy versus surgery for perforated duodenal ulcer. *Gut.* 1987;28:A1375.
7. Kulber DA, Hartunian S, Schiller D, Morgenstern L. The current spectrum of peptic ulcer disease in the older age groups. *Am Surg.* 1990;56(12):737-41.
8. Bornman PC, Theodorou NA, Jeffery PC, Marks IN, Essel HP, Wright JP, et al. Simple closure of perforated duodenal ulcer; a prospective evaluation of a conservative management policy. *Br J Surg.* 1990;77(1):73-5.
9. Tate JJ, Dawson JW, Lau WY, Li AK. Sutureless laparoscopic treatment of perforated duodenal ulcer. *Br J Surg.* 1993;80(2):235.
10. Dubois F. New surgical strategy for gastroduodenal ulcer: laparoscopic approach. *World J Surg.* 2000;24(3):270-6.

11. Bloechle C, Emmermann A, Treu H, Achilles E, Mack D, Zornig C, et al. Effect of pneumoperitoneum on the extent and severity of peritonitis induced by gastric ulcer perforation in the rat. *Surg Endosc.* 1995;9(8):898-901.
12. Bertleff MJ, Lange JF. Laparoscopic correction of perforated peptic ulcer: first choice? A review of literature. *Surg Endosc.* 2010;24(6):1231-9.
13. Bergamaschi R, Mørvik R, Johnsen G, Thoresen JE, Ystgaard B, Myrvold HE. Open vs laparoscopic repair of perforated peptic ulcer. *Surg Endosc.* 1999;13(7):679-82.
14. Palanivelu C, Jani K, Senthilnathan P. Laparoscopic management of duodenal ulcer perforation: is it advantageous? *Indian J Gastroenterol.* 2007;26(2):64-6.
15. Malkov IS, Zaynutdinov AM, Veliyev NA, Tagirov MR, Merrell RC. Laparoscopic and endoscopic management of perforated duodenal ulcers. *J Am Coll Surg.* 2004;198(3):352-5.
16. Lo HC, Wu SC, Huang HC, Yeh CC, Huang JC, Hsieh CH. Laparoscopic simple closure alone is adequate for low risk patients with perforated peptic ulcer. *World J Surg.* 2011;35(8):1873-8.
17. Lau WY, Leung KL, Kwong KH, Davey IC, Robertson C, Dawson JJ, et al. A randomized study comparing laparoscopic versus open repair of perforated peptic ulcer using suture or sutureless technique. *Ann Surg.* 1996;224(2):131-8.
18. Nicolau AE, Merlan V, Veste V, Micu B, Beuran M. Laparoscopic suture repair of perforated duodenal peptic ulcer for patients without risk factors. *Chirurgia (Bucur).* 2008;103(6):629-33.
19. Vaidya BB, Garg CP, Shah JB. Laparoscopic repair of perforated peptic ulcer with delayed presentation. *J Laparoendosc Adv Surg Tech A.* 2009;19(2):153-6.
20. Sârbu V. Old and new concepts in surgical therapy of gastroduodenal ulcers complicated or resistant to treatment. *Chirurgia (Bucur).* 2011;106(6):709-13. Romanian