

Feasibility Study of EUS-NOTES as a Novel Approach for Peroral Cholecysto-Gastrostomy

A. Saftoiu^{1,2*}, P. Vilmann^{2*}, M.S. Bhutani^{3*}

¹Research Center of Gastroenterology and Hepatology, University of Medicine and Pharmacy Craiova, Romania

²Gastrointestinal Unit, Copenhagen University Hospital Herlev, Denmark

³Department of Gastroenterology, Hepatology and Nutrition, University of Texas MD Anderson Cancer Center, USA

Rezumat

Studiu de fezabilitate al procedurilor de chirurgie endoscopică transluminală prin orificii naturale (NOTES) ghidate prin endoscopie ultrasonografică (EUS) pentru efectuarea de colecisto-gastrostomii perorale

Introducere: Colecisto-gastrostomia ghidată prin endoscopie ultrasonografică (EUS) poate reprezenta o procedură minim-invazivă folosită pentru drenajul colecistului, fie la pacienți cu cancer pancreatico-biliare avansate, fie la pacienți cu colecistită acută care nu sunt considerați candidați pentru o posibilă intervenție chirurgicală laparoscopică.

Obiectiv: Colecisto-gastrostomie directă ghidată ecoendoscopic prin plasarea unui stent metalic expandabil dublu.

Design: Studiu de fezabilitate pilot la un model experimental animal.

Material și metode: Studiul a testat fezabilitatea colecisto-gastrostomiei ghidate ecoendoscopic prin abord transgastric la un model experimental porcine. Au fost folosite dispozitive

speciale pentru accesul transgastric al colecistului prin abord ecoendoscopic prin canalul de biopsie, respectiv un stent metalic expandabil cu capete proeminente.

Rezultate: Rezultatele au indicat că procedura este dificilă dar fezabilă, pe baza unor dispozitive prototip pentru accesul transgastric al colecistului, prin plasarea transgastrică a unui stent metalic expandabil.

Limitări: Studiu de fezabilitate de supraviețuire folosind dispozitive prototip pentru drenaj ecoendoscopic al colecistului la un număr mic de animale (5 porci).

Concluzii: Colecisto-gastrostomia ghidată ecoendoscopic prin abord transgastric la un model experimental porcine este o procedură fezabilă, dar dificilă tehnic datorită limitărilor anatomice ale modelului experimental porcine, dar în special datorită complexității procedurii și a stadiului preliminar de dezvoltare al accesoriilor endoscopice.

Cuvinte cheie: chirurgie endoscopică transluminală prin orificii naturale (NOTES), endoscopie ultrasonografică (EUS), colecisto-gastrostomie, anastomoze bilio-digestive

Corresponding author: Manoop S. Bhutani, MD, FASGE, FACP, AGAF,
Professor of Medicine, Experimental Diagnostic Imaging and Biomedical Engineering
Director of Endoscopic Research and Development
Department of Gastroenterology, Hepatology and Nutrition-Unit 1466
UT MD Anderson Cancer Center
1515 Holcombe Blvd., Houston, Texas, USA
77030-4009
Phone: 713-794-5073, Fax: 713-563-4398
E-mail: manoop.bhutani@mdanderson.org

* All three authors contributed equally to the study.

Abstract

Background: EUS-guided cholecysto-gastrostomy might be a useful minimally invasive procedure used for salvage drainage in advanced pancreaticobiliary cancers, but also for drainage of the gallbladder in acute cholecystitis in patients deemed unfit for laparoscopic surgery.

Objective: Direct EUS-guided cholecysto-gastrostomy with placement of a double flanged expandable metal stents.

Design/Setting: This was an animal pilot/feasibility study.

Interventions: The feasibility of EUS-guided cholecysto-gastrostomy through a transgastric approach was tested in five pigs. Specially designed EUS-guided devices for initial access in the gallbladder and a double flanged expandable metal stent were used in this study.

Result: The results showed the feasibility of EUS-guided cholecysto-gastrostomy based on prototype devices for access in the gallbladder and transgastric stent placement.

Limitations: Survival feasibility study with prototype devices in a small number of animals.

Conclusions: EUS guided cholecysto-gastrostomy in a porcine model is feasible but technically demanding due to anatomical limitations of the pig and/or complexity of the procedure and the preliminary stage of development of the accessory devices.

Abbreviations: NOTES - Natural Orifice Translumenal Endoscopic Surgery; EUS - Endoscopic Ultrasound; EUS-FNA - Endoscopic Ultrasound Fine Needle Aspiration.

Key words: NOTES, EUS, cholecysto-gastrostomy, biliodigestive anastomoses

Introduction

Cholecysto-gastrostomy represents a surgical procedure performed for salvage biliary drainage in advanced pancreatico-biliary cancers, where other methods of internal or external drainage fail or are deemed too risky or relatively contraindicated. Thus, for locally unresectable or metastatic advanced pancreatic cancer, treatment of bile duct or duodenal obstruction is an essential part of the palliative therapy algorithm. Both endoscopic/percutaneous stenting procedures and surgical bypass techniques constitute safe and highly effective therapeutic alternatives in this context. The decision on a surgical versus an endoscopic procedure for palliation still depends considerably on the tumour stage and the estimated prognosis of the patient. This has to be determined in an interdisciplinary fashion and individually in each case, based also on local expertise and availability (1).

Surgical biliodigestive bypass procedures include among others various choledoco-duodenal, cholecysto-gastric or hepatico-jejuno anastomoses, being useful in patients with advanced pancreatico-biliary cancers, with a relatively longer survival predicted at the moment of initial diagnosis, thus reducing the need of repeated endoscopic or percutaneous procedures (2,3).

Conventional endoscopic/percutaneous stenting procedures performed through endoscopic retrograde cholangio-pancreatography (ERCP) or percutaneous transhepatic cholangiography (PTC) are already established procedures, having excellent results with minimal complications in expert hands. Based on recent advances of endoscopic ultrasound (EUS), an antegrade approach from the stomach / duodenum through the left hepatic liver lobe / common bile duct can be successfully used

to perform EUS-assisted rendez-vous procedures, followed immediately by ERCP (4,5). Also, direct EUS-guided transhepatic antegrade self-expandable metal stent placement across malignant biliary obstruction has been employed in a limited number of patients, treated in expert centers (6-8).

EUS-guided or EUS-assisted procedures have been used for the placement of covered expandable metallic stents directly from the stomach or duodenum into the dilated bile ducts of the left liver lobe or the dilated common bile duct, without crossing the malignant obstruction. Most of the recent studies used covered expandable metal stents, with an overall technical and functional success rate of approximately 90%, but also with adverse events consisting of bile peritonitis, bleeding and self-limited pneumoperitoneum.

The aim of this study was to use EUS-guidance and natural orifice transluminal endoscopic surgery (NOTES) techniques to test and develop in a systematic approach, a direct peroral transgastric method used for cholecysto-gastrostomy created by placement of a prototype covered expandable double flanged metallic stent.

Material and Methods

Five live animals were used in this pilot/feasibility study. This number was based on the minimal number of animals needed to obtain preliminary data. Swine models have been used in many endoscopic preclinical studies due to the similarity to human anatomy and ability to accommodate adult size endoscopic instruments that are used in humans, allowing translation of animal results to human trials. The endoscopic views and anatomy are well-described in the gastrointestinal literature, and identical endoscopes and equipment are used as in humans. The protocol for this study was approved by the Institutional Animal Care and Use Committee of UT MD Anderson Cancer Center.

Live animal study

Five live Yorkshire cross pigs underwent general anesthesia for upper gastrointestinal endoscopy (EGD) and EUS. Initial sedation was performed with ketamine (22-33 mg/kg) and acepromazine (0.22-1.1 mg/kg) IM. Anesthesia was maintained with isoflurane 1-3% inhalant. We subsequently tested the feasibility of EUS-guided cholecysto-gastric anastomoses, performed with novel prototype accessories and a double flanged covered expandable metallic stent (Xlumena). Continuous video recordings of the procedures were obtained. Specifically, the following parameters were measured: complete time of procedure from sedation until gastrotomy closure, traumatic injuries during the procedure and intraoperative mortality before euthanasia.

EUS-guided cholecysto-gastrostomy

After anesthesia, an upper GI endoscopy was initially performed to clear the stomach. The gastroscope was then removed and a therapeutic linear endoscopic ultrasound

(EUS)scope (Olympus Medical Systems, Boston, MA, USA) with a 3.7 mm channel was passed into the stomach. The gallbladder was identified through the antrum by EUS and a place devoid of vessels was identified at the level of the gastric wall by using the Doppler color flow mode. A 19G EUS-FNA needle with stylet (Olympus Medical Systems, Boston, MA, USA) was introduced through the biopsy channel of the scope and a EUS-guided puncture into the gallbladder was performed (Fig. 1). The stylet was removed and exchanged with a specially designed anchor wire (Xlumena, Mountainview, CA, USA) loaded into the 19G needle. The anchor wire was then pushed into the gall bladder (Fig. 2A), and the 19G EUS needle was removed after confirming placement of the anchor wire inside the gallbladder. The EUS scope was removed leaving the anchor wire in situ, but subsequently reinserted next to anchor wire. The puncture site of the anchor wire was visualized endoscopically, while the wire was pulled back until the anchor base was seen by direct endoscopic vision (Fig. 2B). A special access device (Navix, Xlumena, Mountainview, CA, USA) with a 20G trocar, a small blade and anchor balloon catheter, was passed through the biopsy channel. The trocar was used to puncture the stomach and gallbladder which were kept into close apposition by gentle traction on the anchor wire (Fig. 3). The trocar was removed and a 0.035 guide wire (Hydra Jagwire, Boston Scientific, Natick, MA, USA) was placed in the gallbladder via the trocar port. The access device was removed with the guide wire kept *in situ* inside the gallbladder. An expandable stent delivery system (Axios, Xlumena, Mountainview, CA, USA) was loaded into the biopsy channel over the guide wire, and the stent was further passed into gallbladder. The distal flange of the stent was deployed (Fig. 4A), the flange was pulled back and the proximal stent deployed after the stent sleeve was seen in the stomach (Fig. 4B). The stent was further expanded with a 10 mm biliary balloon dilator (Cook Endoscopy, Winston-Salem, NC, USA) passed over guide wire into the stent, with the balloon dilated at 6 atm pressure for one minute. The EUS scope was then removed and replaced with a

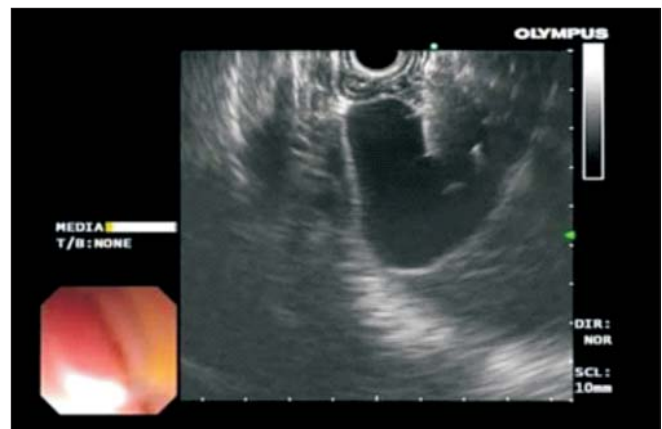

Figure 1. EUS-guided puncture of the gallbladder was performed through the antrum in a place devoid of vessels, based on color Doppler

pediatric gastroscope which allowed inspection of the stent and the cholecysto-gastrostomy (Fig. 5). The pediatric gastroscope was advanced through the cholecysto-gastrostomy into the gallbladder. Biopsies of the gallbladder mucosa were taken with a biopsy forceps and sent to pathology for confirmation.

Results

A total number of five pigs were used for this initial pilot study of cholecysto-gastrostomy. Details of the procedures are included in Table 1. EUS-guidance was used for the initial trans-gastric access of the gallbladder using usual, commercially available, 19G EUS-FNA needles (Fig. 1). After initial access and placement of a hydrophilic guide wire into the gallbladder, different accessories (a special anchor wire or T-tags) were used in order to keep the gallbladder in apposition with the stomach wall (Fig. 2). A special access device (Navix, Xlumena, Mountainview, CA, USA) was further used for initial puncture and cutting / dilation of the stomach and gallbladder wall, under direct EUS-guidance (Fig. 3). The special double-flanged

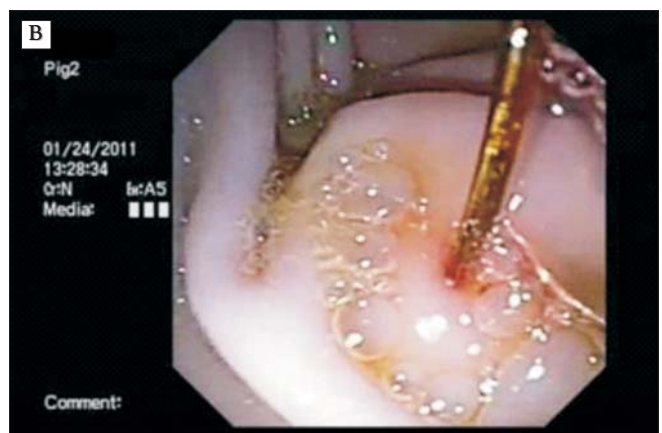
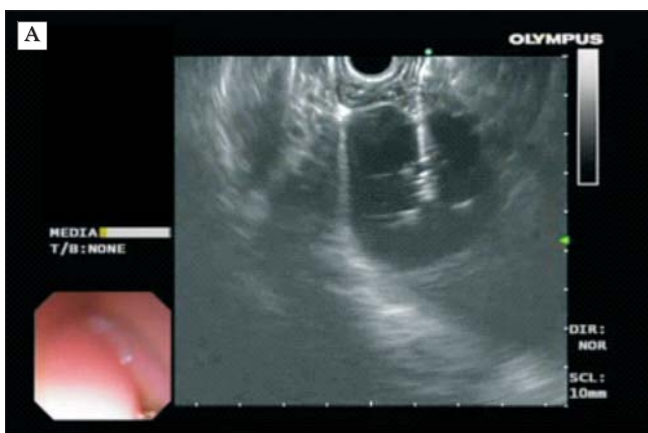

Figure 2. (A) Insertion of a specially designed anchor wire, used to keep traction and apposition of the gallbladder and stomach wall. (B) Re-insertion of the EUS scope near the anchor wire

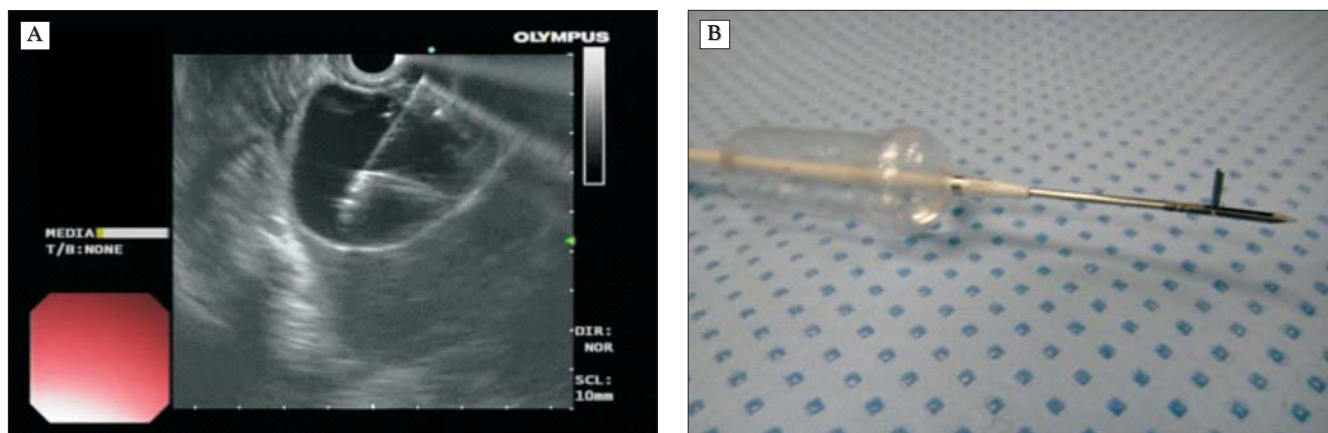


Figure 3. (A) EUS-guided insertion of the special access device with a trocar, blade and anchor balloon. (B) Appearance of the access device

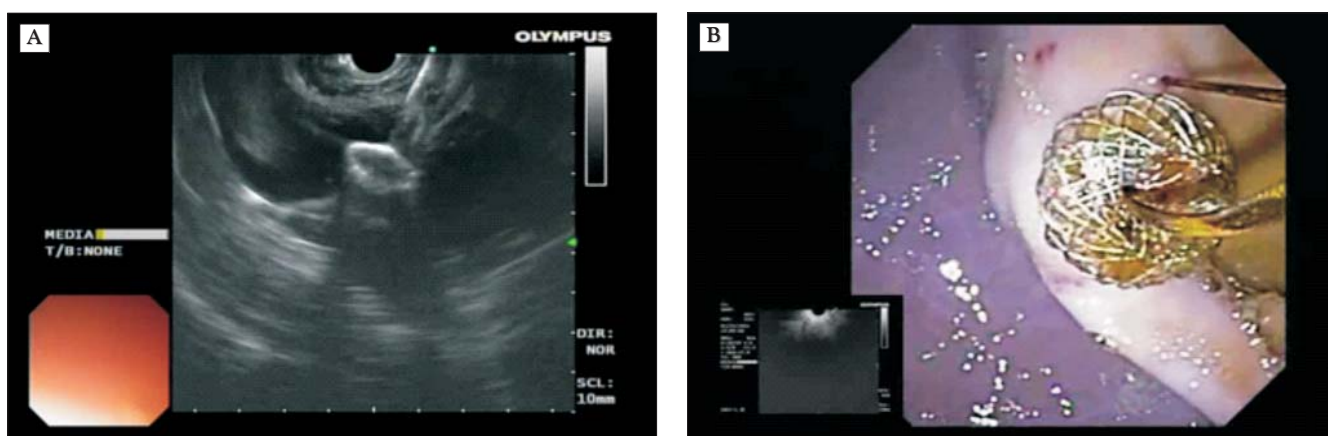


Figure 4. (A) Deployment of the distal flange of the expandable stent inside the gallbladder, under direct EUS-guidance. (B) Deployment of the proximal flange of the expandable stent inside the stomach, under direct endoscopic visualization. The anchor wire can be also visualized

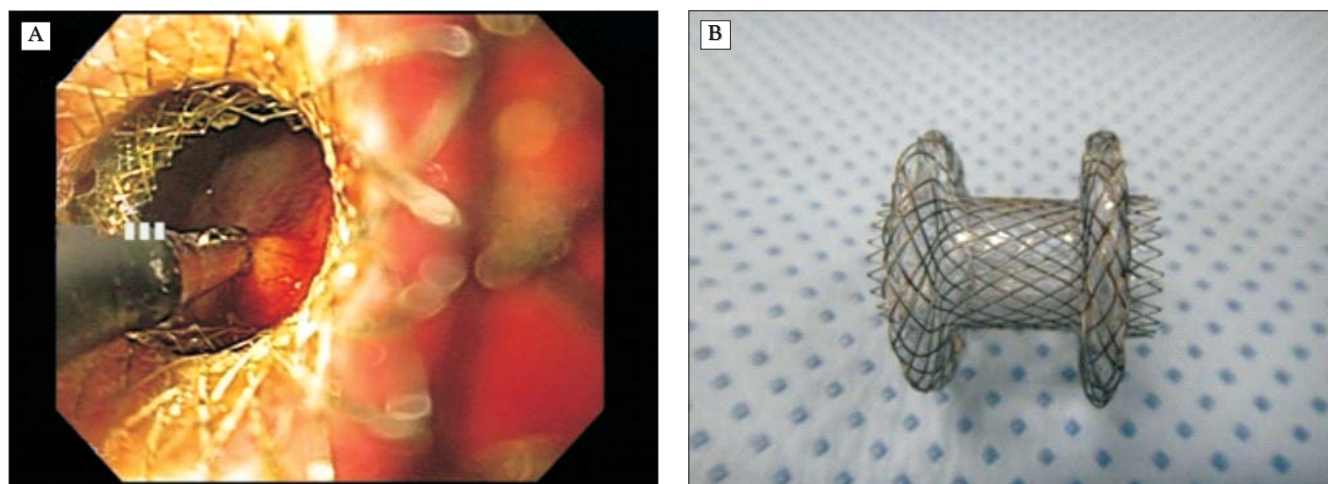


Figure 5. (A) Visualization of the gallbladder mucosa through the stent and cholecysto-gastrostomy, which was confirmed by endoscopic forceps biopsies and pathology analysis. (B) Appearance of the double flanged expandable stent

Table 1. Succession of procedures performed during EUS-guided cholecysto-gastrostomy in each of the five pigs

Pig no.	19G EUS-guided puncture	Anchor wire / T-tag insertion	20G Navix device puncture	Guide wire + Navix removal	Stent catheter insertion	Distal flange deployment	Proximal flange deployment	Salvage procedure	Obs.
1	Yes	Yes (A)	Yes	Yes	Yes	Yes, but outside gallbladder	Yes (gastric wall deployment)	Not successful	Distal flange deployed outside gallbladder
2	Yes	Yes (A)	Yes	Yes	Yes	Yes	Yes	10 mm balloon dilation of the stent	Successful procedure
3	Yes	Yes (A)	Yes	Yes	Yes	Yes, but outside gallbladder	Yes	Not successful (gallbladder re-inflation)	Distal flange deployed outside gallbladder with water)
4	Yes	Yes (A)	Yes	Yes, but access device balloon could not be passed inside	No, stent catheter not passed	No	No	Pediatric scope with dilation balloon, passed into peritoneum	Stent catheter impossible to be passed in the gallbladder
5	Yes	Yes (T)	Yes	Yes	No, stent catheter not passed	No	No	Gastroscope with dilation balloon, passed into peritoneum	Stent catheter impossible to be passed in the gallbladder

expandable stent was further passed and deployed under EUS-guidance inside the gallbladder, but the procedure was successful in only 3 out of 5 pigs (Fig. 4). Furthermore, the distal flange of the stent was not deployed correctly in one pig, while the proximal flange deployed inappropriately at the level of the gastric wall in another pig. None of the salvage procedures tried was useful; consequently the procedure was completely successful in one out of five pigs.

The reason for failure was either due to difficulty to obtain a correct apposition between the transducer and the gallbladder and stomach wall or technical problems related to the complexity of the entire procedure including limitations of accessories. These consisted in the inability to pass the

relatively large catheter of the expandable stent through the stomach and gallbladder wall (2 pigs), as well as an incorrect opening of the stent, either in the distal (2 pigs) or proximal (1 pig) double flanged ends. Although the procedure was performed by experienced EUS operators with over 10 to 20 years of experience of therapeutic EUS, it was still regarded as difficult due to the pig stomach anatomy (J-shaped stomach, with a long and unstable position of the scope in the antrum in order to access the gallbladder). The exchange of several accessories with a large diameter was also considered cumbersome and difficult, despite the combined ultrasound and radiological guidance, while a one-step system would have been preferable.

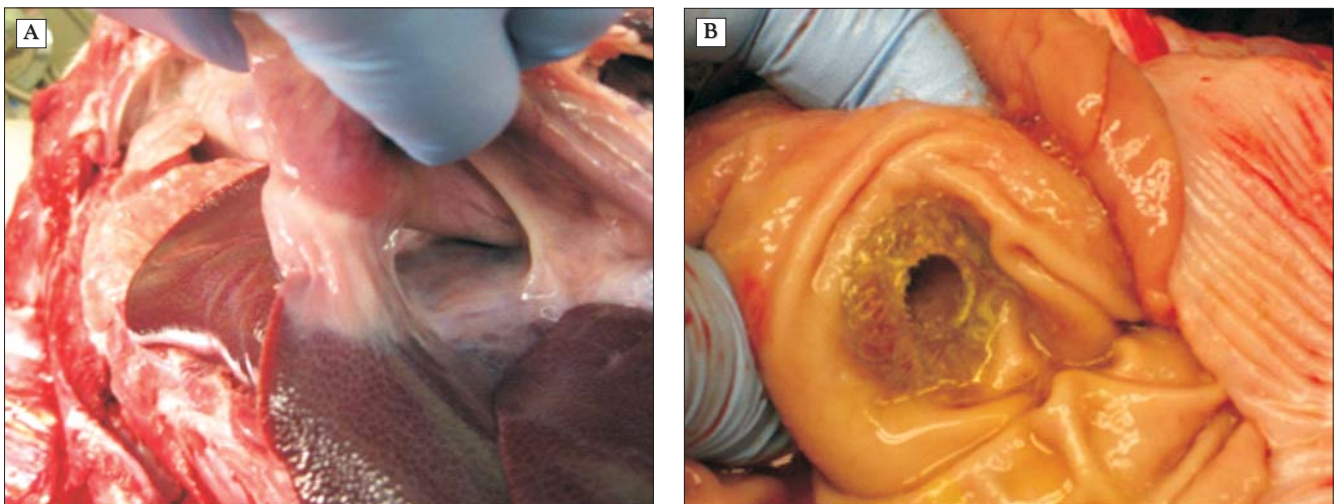


Figure 6. (A) Pathology examination after a survival of one month, showing a fibrotic tract developed between the gallbladder and stomach. (B) Patent cholecysto-gastrostomy with the stent in place, visualized after opening of the stomach.

Only one animal survived the acute procedures prior to euthanasia. Pathology examination after 1 month showed a patent cholecysto-gastrostomy with the stent in place and a fibrotic tract developed between the gallbladder and stomach (Fig. 6 A,B).

Discussion

Recently, both EUS and NOTES have gained increased interest as minimal invasive procedures while many feasibility studies and even randomized clinical trials of applications in surgical procedures have already been performed in experimental porcine models or even in humans (18-22). EUS-guidance has been the backbone of multiple therapeutic procedures, starting with celiac plexus neurolysis and pancreatic pseudocyst drainage, with a plethora of new applications that were recently described (23). Recently, expandable stents were used for the drainage of pancreatic pseudocysts, with satisfactory results and suggestions of a decreased rate of obstruction and thus recurrence (24). Several technical improvements were further developed in order to prevent stent migration, including placement of flared plastic stents inside the metallic stent (25), as well as development of a lumen-apposing double flanged metallic stent (26,27). Initial experience in 4 pigs (26) and 20 human patients (27), although still limited, showed that expandable stents are feasible and can be safely used for both the transluminal drainage of pseudocysts and the gallbladder. The same group recently proposed the same approach with endoscopic tools (including the lumen-apposing stent) for gastroenteric anastomoses, with the procedure being technically successful in 5 pigs (28). Nevertheless, we have tried to replicate the same EUS-guided cholecysto-gastrostomy procedures in the pig model and we highlighted the technical problems and difficulties associated with a demanding procedure and prototype accessories.

NOTES cholecystectomy has been the most studied application of natural orifice surgery. Several studies, including human studies already proved the feasibility and safety of such procedures (27-35). EUS-guided or EUS-assisted choledochoduodeno-anastomosis and hepatico-gastro-anastomosis have already proven feasible and reasonably safe in expert hands (36-37), although future randomized studies should clarify the potential role and risks of these procedures compared with percutaneous transhepatic cholangiography (PTC) guided access. Most of these EUS-guided procedures assume the placement of covered expandable stents in order to prevent bile leakage. The most probable application of combined EUS-NOTES procedures might be the performance of cholecysto-gastrostomy, because EUS-guided access of the gallbladder is easy to be accomplished with 19G needles from the antrum. After the apposition of the gallbladder and stomach wall (obtained for example with T-tags or special anchors), the communication between both structures might be easily obtained, followed by the placement of a covered expandable stent, which should also prevent bile leakage. Further randomized controlled trials are eagerly expected in this field, mainly because palliative procedures might be more

tempting to be performed through EUS-NOTES, in a minimally invasive way, with minimal morbidity and mortality as compared to open surgical procedures.

Cholecysto-gastrostomy might represent a useful salvage method used for the pancreatico-biliary cancer patients treated initially by endoscopic methods that have ensuing recurrent cholangitis or stent occlusion. Moreover, minimally invasive laparoscopic surgical bypass procedures do not have an established role for the palliation of advanced cancer patients, at least based on the currently available literature (2,3). One distinct application of cholecysto-gastrostomy would be the treatment of acute or chronic cholecystitis, with or without removal of gallstones from the gallbladder inside the stomach (27,29). This might be especially important in elderly patients or patients with significant comorbidities where emergency cholecystectomy for acute cholecystitis is accompanied with a high risk of morbidity and mortality. These patients usually receive percutaneous gallbladder drainage, with the consequent discomfort of external drainage and complications induced by incidental possible drain removal (38). Nevertheless, various transgastric or transduodenal EUS-guided approaches have been already described (39-44). More studies should be however conducted in the future in order to establish the feasibility and safety of these procedures.

In conclusion, EUS guided cholecysto-gastrostomy in a porcine model is feasible but technically demanding, due to anatomical limitations of the pig and/or complexity of the procedure, as well as the preliminary stage of development of the accessory devices.

Location

All the procedures mentioned in this study were performed at the University of Texas, MD Anderson Cancer Center, USA.

Conflict of interest/disclosures

Funded by a Research Award by UT MD Anderson Cancer Center to Dr. Manoop S. Bhutani. Equipment for this study was provided by Olympus Corp. to MD Anderson Cancer Center for endoscopic research by any investigator at the institution. Parts of the consumables for this study were supplied at no charge by Cook and Xlumena.

References

1. Hüser N, Assfalg V, Michalski CW, Gillen S, Kleeff J, Friess H. Unresectable pancreatic cancer-palliative interventional and surgical treatment. *Zentralbl Chir.* 2010;135(6):502-7. doi: 10.1055/s-0030-1262549. Epub 2010 Dec 13. German
2. Bahra M, Jacob D. Surgical palliation of advanced pancreatic cancer. *Recent Results Cancer Res* 2008;177:111-20.
3. Andtbacka RH, Evans DB, Pisters PW. Surgical and endoscopic palliation for pancreatic cancer. *Minerva Chir.* 2004;59(2):123-36.
4. Kim YS, Gupta K, Mallery S, Li R, Kinney T, Freeman ML. Endoscopic ultrasound rendezvous for bile duct access using a transduodenal approach: cumulative experience at a single

- center. A case series. *Endoscopy*. 2010;42(6):496-502. doi: 10.1055/s-0029-1244082. Epub 2010 Apr 23.
5. Iwashita T, Lee JG, Shinoura S, Nakai Y, Park DH, Muthusamy VR, et al. Endoscopic ultrasound-guided rendezvous for biliary access after failed cannulation. *Endoscopy*. 2012;44(1):60-5. doi: 10.1055/s-0030-1256871. Epub 2011 Nov 29.
6. Nguyen-Tang T, Binmoeller KF, Sanchez-Yague A, Shah JN. Endoscopic ultrasound (EUS)-guided transhepatic antegrade self-expandable metal stent (SEMS) placement across malignant biliary obstruction. *Endoscopy*. 2010;42(3):232-6. doi: 10.1055/s-0029-1243858. Epub 2010 Jan 29.
7. Weilert F, Binmoeller KF, Marson F, Bhat Y, Shah JN. Endoscopic ultrasound-guided antegrade treatment of biliary stones following gastric bypass. *Endoscopy*. 2011;43(12):1105-8. doi: 10.1055/s-0030-1256961. Epub 2011 Nov 4.
8. Shah JN, Marson F, Weilert F, Bhat YM, Nguyen-Tang T, Shaw RE, et al. Single-operator, single-session EUS-guided antegrade cholangiopancreatography in failed ERCP or inaccessible papilla. *Gastrointest Endosc*. 2012;75(1):56-64. doi: 10.1016/j.gie.2011.08.032. Epub 2011 Oct 21.
9. Park H, Jang JW, Lee SS, Seo DW, Lee SK, Kim MH. EUS-guided biliary drainage with transluminal stenting after failed ERCP: predictors of adverse events and long-term results. *Gastrointest Endosc*. 2011;74(6):1276-84. doi: 10.1016/j.gie.2011.07.054. Epub 2011 Oct 1.
10. Giovannini M, Bories E. EUS-Guided Biliary Drainage. *Gastroenterol Res Pract*. 2012;2012:348719. Epub 2011 Aug 14.
11. Hara K, Yamao K, Niwa Y, Sawaki A, Mizuno N, Hijioka S, et al. Prospective clinical study of EUS-guided choledochoduodenostomy for malignant lower biliary tract obstruction. *Am J Gastroenterol*. 2011;106:1239-45.
12. Eum J, Park do H, Ryu CH, Kim HJ, Lee SS, Seo DW, et al. EUS-guided biliary drainage with a fully covered metal stent as a novel route for natural orifice transluminal endoscopic biliary interventions: a pilot study (with videos). *Gastrointest Endosc*. 2010;72(6):1279-84. doi: 10.1016/j.gie.2010.07.026. Epub 2010 Sep 25.
13. Yamao K, Bhatia V, Mizuno N, Sawaki A, Ishikawa H, Tajika M, et al. EUS-guided choledochoduodenostomy for palliative biliary drainage in patients with malignant biliary obstruction: results of long-term follow-up. *Endoscopy*. 2008;40(4):340-2. doi: 10.1055/s-2007-995485.
14. Khashab MA, Fujii LL, Baron TH, Canto MI, Gostout CJ, Petersen BT, et al. EUS-guided biliary drainage for patients with malignant biliary obstruction with an indwelling duodenal stent (with videos). *Gastrointest Endosc*. 2012;76(1):209-13. doi: 10.1016/j.gie.2012.03.170.
15. Nicholson JA, Johnstone M, Raraty MG, Evans JC. Endoscopic ultrasound-guided choledoco-duodenostomy as an alternative to percutaneous trans-hepatic cholangiography. *HPB (Oxford)*. 2012;14(7):483-6. doi: 10.1111/j.1477-2574.2012.00480.x.
16. Attasaranya S, Netinasunton N, Jongboonyanuparp T, Sottisuporn J, Witeerungrot T, Pirathvisuth T, et al. The Spectrum of Endoscopic Ultrasound Intervention in Biliary Diseases: A Single Center's Experience in 31 Cases. *Gastroenterol Res Pract* 2012; in press. Epub ahead of print 2012 May 10.
17. Kim TH, Kim SH, Oh HJ, Sohn YW, Lee SO. Endoscopic ultrasound-guided biliary drainage with placement of a fully covered metal stent for malignant biliary obstruction. *World J Gastroenterol*. 2012;18(20):2526-32. doi: 10.3748/wjg.v18.i20.2526.
18. Elmunzer BJ, Schomisch SJ, Trunzo JA, Poulouse BK, Delaney CP, McGee MF, et al. EUS in localizing safe alternate access sites for natural orificetransluminal endoscopic surgery: initial experience in a porcine model. *Gastrointest Endosc*. 2009;69(1):108-14. doi: 10.1016/j.gie.2008.04.030. Epub 2008 Jul 16.
19. Fritscher-Ravens A, Ghanbari A, Cuming T, Kahle E, Niemann H, et al. Comparative study of NOTES alone vs. EUS-guided NOTES procedures. *Endoscopy*. 2008;40(11):925-30. doi: 10.1055/s-2008-1077732. Epub 2008 Nov 13.
20. Şurlin V, Săftoiu A, Rimbaş M, Vilmann P. Notes "state of the art" surgical gastro-enterology: the beginning of the voyage. *Hepatogastroenterology*. 2010;57(97):54-61.
21. Tomulescu V, Gheorghe C, Piţigoi D, Kosa A, Ciocarlan M, Pietrăreanu D, et al. An experimental model of transgastricofoforectomy using a porcine model. *Chirurgia (Bucur)*. 2010;105(3):331-7.
22. Tomulescu V, Popescu I. NOTES (Natural orifice transluminal endoscopic surgery) - present and perspectives. *Chirurgia (Bucur)*. 2008;103(2):135-8. Romanian
23. Bhutani MS. The year of improved tissue acquisition, randomized trials, and endoscopic ultrasound-guided therapy. *Endoscopy*. 2011;43(11):993-9. doi: 10.1055/s-0031-1291444. Epub 2011 Nov 4.
24. Belle S, Collet P, Post S, Kaehler G. Temporary cystogastrostomy with self-expanding metallic stents for pancreatic necrosis. *Endoscopy*. 2010;42(6):493-5. doi: 10.1055/s-0029-1244021. Epub 2010 Apr 29.
25. Tarantino I, Di Pisa M, Barresi L, Curcio G, Granata A, Traina M. Covered self expandable metallic stent with flared plastic one inside for pancreatic pseudocyst avoiding stent dislodgement. *World J Gastrointest Endosc*. 2012;4(4):148-50. doi: 10.4253/wjge.v4.i4.148.
26. Binmoeller KF, Shah J. A novel lumen-apposing stent for transluminal drainage of nonadherent extraintestinal fluid collections. *Endoscopy*. 2011;43(4):337-42. doi: 10.1055/s-0030-1256127. Epub 2011 Jan 24.
27. Itoi T, Binmoeller KF, Shah J, Sofuni A, Itokawa F, Kurihara T, et al. Clinical evaluation of a novel lumen-apposing metal stent for endosonography-guided pancreatic pseudocyst and gallbladder drainage (with videos). *Gastrointest Endosc*. 2012;75(4):870-6. doi: 10.1016/j.gie.2011.10.020. Epub 2012 Jan 31.
28. Binmoeller KF, Shah JN. Endoscopic ultrasound-guided gastroenterostomy using novel tools designed for transluminal therapy: a porcine study. *Endoscopy*. 2012;44(5):499-503. doi: 10.1055/s-0032-1309382. Epub 2012 Apr 24.
29. Park PO, Bergström M, Ikeda K, Fritscher-Ravens A, Swain P. Experimental studies of transgastric gallbladder surgery: cholecystectomy and cholecystogastric anastomosis (videos). *Gastrointest Endosc*. 2005;61(4):601-6.
30. Pai RD, Fong DG, Bundga ME, Odze RD, Rattner DW, Thompson CC. Transcolonic endoscopic cholecystectomy: a NOTES survival study in a porcine model (with video). *Gastrointest Endosc*. 2006;64(3):428-34.
31. Perretta S, Dallemagne B, Coumaros D, Marescaux J. Natural orifice transluminal endoscopic surgery: transgastric cholecystectomy in a survival porcine model. *Surg Endosc*. 2008;22(4):1126-30. Epub 2007 Oct 11.
32. Rolanda C, Lima E, Pêgo JM, Henriques-Coelho T, Silva D, Moreira I, et al. Third-generation cholecystectomy by natural orifices: transgastric and transvesical combined approach (with video). *Gastrointest Endosc*. 2007;65(1):111-7.
33. Sumiyama K, Gostout CJ, Rajan E, Bakken TA, Knipschild MA, Chung S, et al. Transgastric cholecystectomy: transgastric

- accessibility to the gallbladder improved with the SEMF method and a novel multibending therapeutic endoscope. *Gastrointest Endosc.* 2007;65(7):1028-34.
34. Străin M, Chişevescu D, Blaj S, Hoinoiu B, Barac S, Jiga L, et al. The first NOTE (Natural Orifice Translumenal Endoscopic) cholecystectomy in Romania: an experimental model in pig. *Chirurgia (Bucur).* 2009;104(2):173-9. Romanian
 35. Astudillo JA, Sporn E, Bachman S, Miedema B, Thaler K. Transgastric cholecystectomy using a prototype endoscope with 2 deflecting working channels (with video). *Gastrointest Endosc.* 2009;69(2):297-302. doi: 10.1016/j.gie.2008.05.035.
 36. Itoi T, Sofuni A, Itokawa F, Tsuchiya, et al Endoscopic ultrasonography-guided biliary drainage. *J Hepatobiliary Pancreat Surg.* 2009 (Epub ahead of print)
 37. Artifon EL, Ferreira FC, Otoch JP, Rasslan S, Itoi T, Perez-Miranda M. EUS-guided biliary drainage: a review article. *JOP.* 2012;13(1):7-17.
 38. Sosna J, Copel L, Kane RA, Kruskal JB. Ultrasound-guided percutaneous cholecystostomy: update on technique and clinical applications. *Surg Technol Int.* 2003;11:135-9.
 39. Kwan V, Eisendrath P, Antaki F, Le Moine O, Devière J. EUS-guided cholecysto-enterostomy: a new technique (with videos). *Gastrointest Endosc.* 2007;66(3):582-6.
 40. Baron TH, Topazian MD. Endoscopic transduodenal drainage of the gallbladder: implications for endoluminal treatment of gallbladder disease. *Gastrointest Endosc.* 2007;65(4):735-7. Epub 2006 Dec 1.
 41. Lee SS, Park DH, Hwang CY, Ahn CS, Lee TY, Seo DW, et al. EUS-guided transmural cholecystostomy as rescue management for acute cholecystitis in elderly or high-risk patients: a prospective feasibility study. *Gastrointest Endosc* 2007;66:1008-1012.
 42. Song TJ, Park dH, Eum JB, Moon SH, Lee SS, Seo DW, et al. EUS-guided cholecysto-enterostomy with single-step placement of a 7F double-pigtail plastic stent in patients who are unsuitable for cholecystectomy: a pilot study (with video). *Gastrointest Endosc.* 2010;71(3):634-40. doi: 10.1016/j.gie.2009.11.024.
 43. Kamata K, Kitano M, Komaki T, Sakamoto H, Kudo M. Transgastric endoscopic ultrasound (EUS)-guided gallbladder drainage for acute cholecystitis. *Endoscopy* 2009;41 Suppl 2:E315-E316.
 44. Jang JW, Lee SS, Park dH, Seo DW, Lee SK, Kim MH. Feasibility and safety of EUS-guided transgastric/transduodenal gallbladder drainage with single-step placement of a modified covered self-expandable metal stent in patients unsuitable for cholecystectomy. *Gastrointest Endosc.* 2011;74(1):176-81. doi: 10.1016/j.gie.2011.03.1120.