

Emergency pancreaticoduodenectomy in a patient with an ampullary adenocarcinoma associated with severe acute pancreatitis: a case report

T. Dumitrașcu, M.I. Ionescu, L. David, I. Popescu

Center of General Surgery and Liver Transplantation, Fundeni Clinical Institute, Bucharest, Romania

Rezumat

Duodenopancreatectomie cefalică de urgență pentru ampulom Vaterian asociat cu pancreatită acută severă: prezentare de caz

Duodenopancreatectomia cefalică este rareori practică ca și intervenție chirurgicală în urgență. Este prezentat cazul unui pacient de 58 de ani diagnosticat cu ampulom Vaterian malign asociat cu pancreatită acută severă necrotico-hemoragică. Indicația de urgență a fost dictată de criteriile clinice. Astfel, a fost practică duodenopancreatectomie cefalică tip Whipple asociată cu necrectomie. Bontul pancreatic distal a fost abandonat și dirijat într-o fistulă pancreatică externă. Într-un al doilea timp operator s-a realizat anastomoza pancreatică. Evoluția postoperatorie a pacientului a fost simplă, fără complicații notabile. La peste 5 ani de la rezecție pacientul este în viață, fără semne clinice și imagistice de boală. În concluzie, duodenopancreatectomia cefalică în urgență este o procedură chirurgicală fezabilă și sigură atunci când este practică în centre specializate, în cazuri selecționate.

Cuvinte cheie: duodenopancreatectomie cefalică în urgență, ampulom Vaterian, pancreatită acută necrotico-hemoragică

Abstract

Emergency pancreaticoduodenectomy is an infrequent surgical procedure. Herein, it is reported the case of a 58-year old man with ampullary carcinoma revealed by acute necrotizing pancreatitis. Due to clinical features, an emergency two-step pancreaticoduodenectomy was performed, accomplished by pancreatic and peripancreatic necrosectomy. The distal remnant pancreas was drained as an external pancreatic fistula. A time later, after complete remittance of local inflammation, the pancreas was anastomosed to the jejunum. The postoperative outcome was uneventful, the patient being disease-free at more than 5 years after surgery. Thus, pancreaticoduodenectomy is a feasible and safe operation when performed in tertiary hepato-bilio-pancreatic centers, in selected cases.

Key words: emergency pancreaticoduodenectomy, ampullary carcinoma, acute necrotizing pancreatitis

Introduction

Pancreaticoduodenectomy (PD) is a demanding and complex surgical procedure, requiring expertise. PD as an emergency indication is an added challenge for the surgeon. However, most of the PDs are performed as an elective procedure (1).

Nowadays, the postoperative mortality and severe morbidity after PD has been significantly improved due to a better per operative management of these patients, along with centralisation of pancreatic resections (2).

Carcinoma of the ampulla of Vater is the second most common periampullary malignancy (3). Ampullary tumours

Corresponding author:

Irinel Popescu, MD, PhD, FACS, FEBS
Center of General Surgery and Liver
Transplantation, Fundeni Clinical Institute
Fundeni Street no 258, 022328, Bucharest,
Romania
Tel. / Fax: +40213180417
E-mail: irinel.popescu220@gmail.com
traian.dumitrascu@srchirurgie.ro

may present as acute pancreatitis in up to 15% of cases (4-6). Preoperative pancreatitis considerably influences the surgical management of ampullary tumours (7). However, PD is the single curative intent surgery for malignant tumours in the ampulla of Vater (8).

Acute necrotizing pancreatitis is a serious disease with significant mortality (9) and the extensive necrosis can be itself a contraindication for PD; when it is associated with sepsis and a dramatic systemic response, it can preclude a curative intent, resectional treatment of the periampullary tumours. Thus, a dilemma arises: can PD be successfully performed in a patient with ampullary adenocarcinoma in the setting of acute necrotizing pancreatitis?

Herein, it is reported a rare case of severe acute pancreatitis secondary to ampullary adenocarcinoma, which was treated by an emergency PD. This case is particularly interesting because the patient had a disease-free long term survival (more than 5 years) after surgery.

Case Report

A 58-year-old male was admitted as an emergency in the Center of General Surgery and Liver Transplantation, of Fundeni Clinical Institute, in February 2006, for upper abdominal pain, irradiated in the dorsal region, associated with fever (39-40°C), nausea and emesis. Clinical examination revealed a palpable mass in the right upper quadrant and in the epigastric area. The patient reported occasional alcohol consumption.

Laboratory test results on admission included an elevated white blood cell count (13000/mm³), hyperglycaemia (145 mg/dl), elevated serum amylase (4200 U/l) and lipase (1530 U/l) and conjugated bilirubinemia of 2 mg/dl.

An upper gastrointestinal endoscopy revealed an

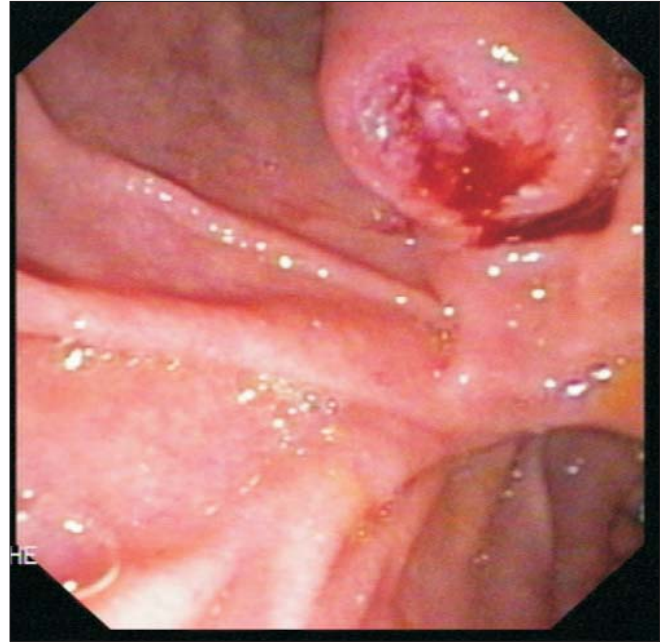

Figure 1. Upper gastrointestinal endoscopy revealing an ulcerated ampullary tumour

ampullary mass whose histological examination showed well differentiated (low grade) adenocarcinoma (Fig. 1).

An abdominal ultrasound examination followed by a contrast enhanced CT scan were performed in an emergency setting, showing peripancreatic fluid collections and liquid in the omental bursa, as well as areas of necrosis in the pancreatic head (Fig. 2).

The patient was admitted in the Intensive Care Unit where he received fluid resuscitation, analgesics, oxygen

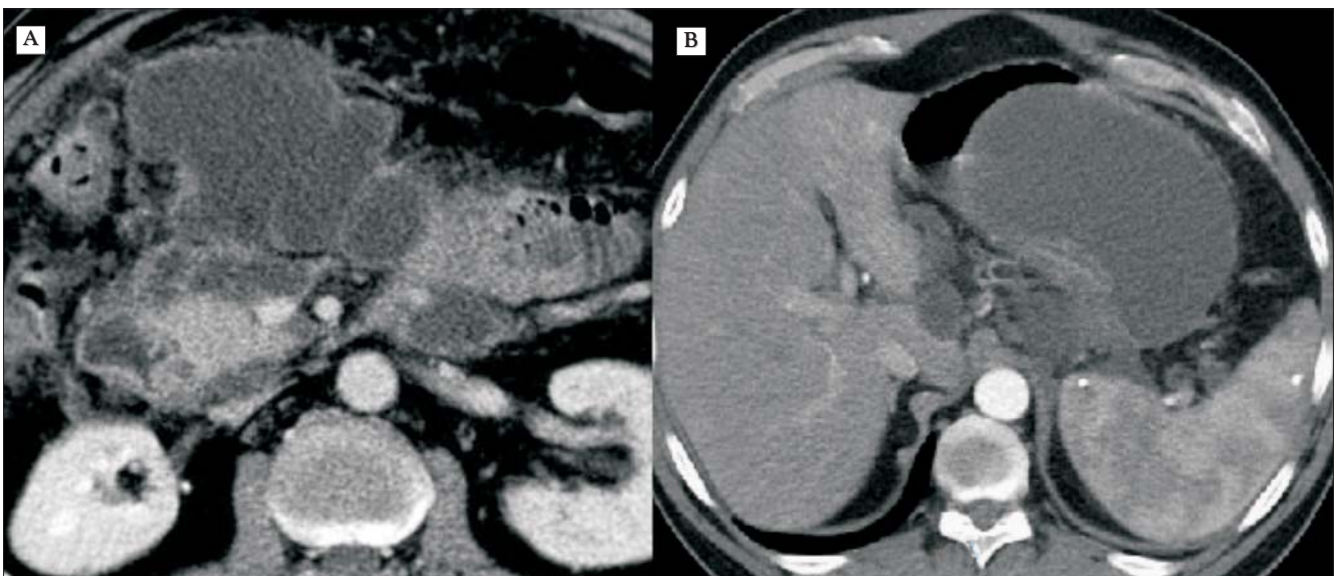


Figure 2. Abdominal CT scan showing (A) acute necrotizing pancreatitis with intra pancreatic necrosis and peripancreatic fluid collections; (B) large intergastro-pancreatic collection

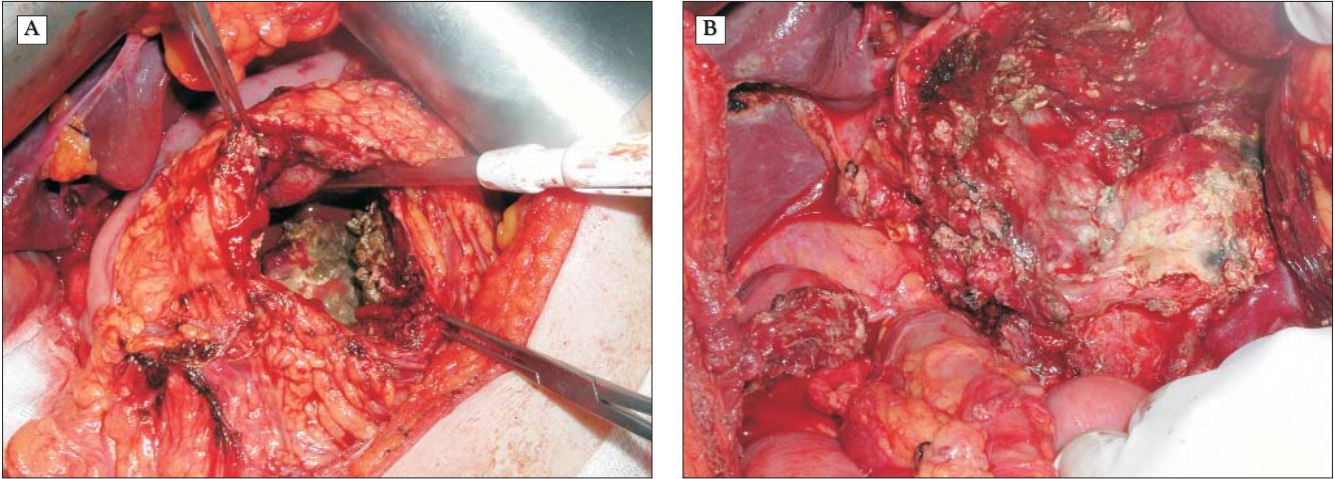


Figure 3. Intraoperative aspects after removal of pancreatic and peripancreatic necrosis (A) and after resection (PD) (B)

therapy and antibiotics. The intensification of the abdominal pain combined with the continuous fever (40 °C) urged the surgical intervention.

The intraoperative findings showed the ampullary tumour and necrotizing pancreatitis (Fig. 3).

A classical Whipple procedure was performed along with pancreatic and peripancreatic necrosectomy; multiple drainages were left in place in the peripancreatic region.

The reconstruction after resection was made using a termino-lateral hepatico-jejunostomy and a termino-lateral gastro-jejunostomy. Due to the poor general status of the patient, the distal remnant pancreas was not anastomosed and it was drained as an external pancreatic fistula.

The patient had an overall uneventful postoperative outcome. However, he developed an external pancreatic fistula with an average flow of 200-400 ml per day and diabetes mellitus compensated by diet and oral anti hyperglycaemic drugs. The patient was discharged 21 days after admission, with an external pancreatic fistula drained on two drainage tubes.

The pathological examination of the operative specimen showed an ulcerated tumour of the ampulla of Vater, with 2 cm in length (Fig. 4). Microscopically it was identified a well-differentiated (G1) tubular adenocarcinoma (Fig. 5), with a papillary and tubulo-papillary cytoarchitecture; no metastasis in the harvested lymph nodes were detected. The periampullary duodenal mucosa was elevated (2 cm), while the tumour did not reached the duodenal wall (pT1). The pathological examination also revealed acute necrotizing pancreatitis, focal cytosteatonecrosis and a pancreatic acute pseudocyst.

The fistula's flow kept on running (100-300 ml per day). As a consequence, 14 months after the initial operation, another surgical procedure was performed: the fistula was suppressed by creating an anastomosis between the leaking pancreatic duct and a Roux-en-Y limb of jejunum (duct-to-mucosa) with uneventful postoperative outcome. The patient was discharged on the 12th postoperative day.

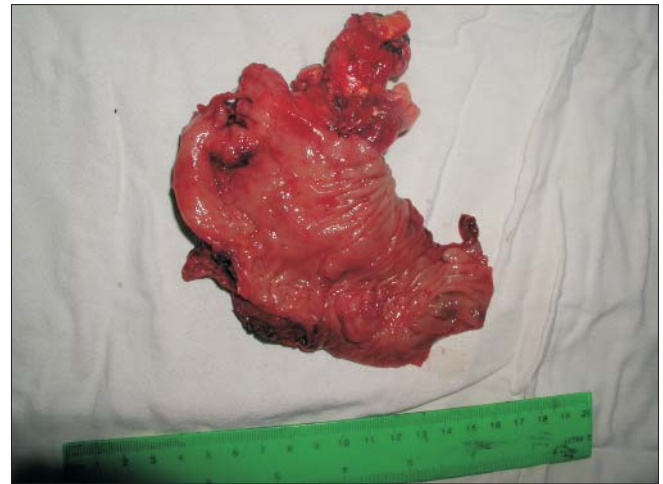

Figure 4. Macroscopic aspect of the ampullary tumour (operative specimen of pancreatico-duodenectomy)

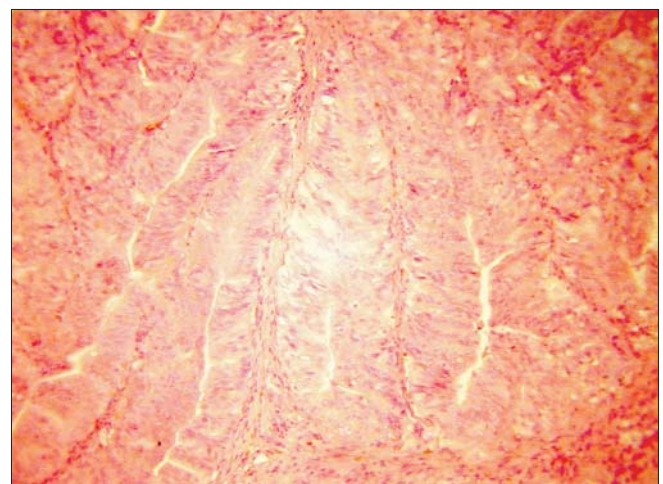


Figure 5. Microscopic aspect of the ampullary tumour (haematoxylin and eosin-stained slides examined at 100x magnification)

At 5 years after resection the patient is with an acceptable nutritional status, with mild diabetes (not requiring insulin therapy) and a slight exocrine pancreatic insufficiency (requiring occasional pancreatic enzyme administration). Moreover, from oncological point of view, the patient is disease-free (no clinical, tumour marker CA 19-9 or imaging signs of local or distant recurrence).

Discussion

In current medical literature, the cases of PD performed as an emergency are quite exceptional, being reported mainly for trauma including massive uncontrollable retropancreatic haemorrhage or in cases of complex and unreconstructable injuries of the pancreatic head region (10).

The most commonly reported cases of non-trauma emergency PD are: severe complications after therapeutical endoscopies (perforation or bleeding), intractable duodenal or ampullary bleeding (ulcers or tumors) (11-14). Other exceptional causes for an emergency PD are: acute abdomen due to mucinous cystic neoplasm (15), bleeding from varices of the duodenum due to pancreatic arterio-venous malformation (16) and spontaneous hemorag for a metastatic tumour of the pancreatic head invading the duodenum (17).

However, emergency PD represents less than 2% of the indications of PD(11,14).

The indication for an emergency PD should take into consideration mainly clinical aspects, rather than imaging features (11), as in presented case.

Surgery-related complications after emergency PD are reported to be quite similar to those after elective PD, although the overall morbidity is higher due to the altered general status of the patients with emergency indications (11,14).

Two stage PD may be a valid option that has been proven to be a safe attitude in selected cases (16,18-21) being proposed for the first time by Makuuchi group (22) in emergency situations and high-risk patients. Rationale of this attitude is to decrease the morbidity and mortality related to distal pancreatic stump anastomosis in a group of patients with a prior high risk. Indeed, life-treatening pancreatic fistula after PD (grade C fistula) is encountered in about 5% of elective PD and it is associated with 40% mortality (23). Reconstruction of the pancreatic stump is made at a later time.

Generally, ampullary carcinoma has an overall good prognosis, patients with negative lymph nodes after PD having a potential for cure in 80% of the cases (24).

Although, jaundice is the main sign in ampullary carcinoma, some patients may exhibit symptoms and signs of acute pancreatitis (4-6).

Acute necrotizing pancreatitis has a very high risk potential, with a reported mortality rate of more than 25% (25); the perioperative risk is amplified by the complications and risks associated with PD. However, if the surgical treatment is performed in experienced centres, the procedure will render considerably better results. Moreover, if the surgical interven-

tion is performed in an emergency manner, it will prevent potential life-threatening episodes of pancreatitis in an already seriously diseased individual.

Local resection is not a good option even for early invasive adenocarcinoma of the ampulla of Vater since lymph nodes metastasis are encountered in about 30% of T1 patients. Thus, PD should be the preferred approach in ampullary carcinoma as a curative intent surgery (8).

There is no agreement concerning the management of pancreatitis caused by ampullary neoplasms, yet histopathological examination of the bioptic material obtained via endoscopy should be performed when this situation occurs(6). For patients with a malignant tumour at biopsy, extensive surgical resection in the form of PD should be considered.

Conclusions

Ampullary tumors can be revealed by acute necrotizing pancreatitis symptoms in exceptional cases. The surgical treatment should address to both diseases with curative intent.

Emergency PD is a feasible and safe operation when performed in tertiary hepato-bilio-pancreatic centers. However, it should be reserved only for selected cases (i.e. life-threatening duodenal bleeding not solved by radiological or endoscopy methods, postoperative or post endoscopy duodenal lacerations, periampullary malignant lesions associated with acute severe complications like acute necrotizing pancreatitis, perforation or bleeding).

Delayed pancreatic reconstruction could be a life-saving attitude after emergency PD in high-risk patients.

References

1. Ionescu M, Stroescu C, Barbuta S, Ciurea S, Popescu I. Pancreaticoduodenectomy - the rutin surgery? *Chirurgia (Bucur)*. 2003; 98(2):103-8.
2. Dumitrascu T, David L, Popescu I. Posterior versus standard approach in pancreaticoduodenectomy: a case-match study. *Langenbecks Arch Surg*. 2010; 395(6):677-84.
3. Yeo CJ, Cameron JL, Sohn TA, Lillemoe KD, Pitt HA, Talamini MA et al. Six hundred fifty consecutive pancreaticoduodenectomies in the 1990s: pathology, complications, and outcomes. *Ann Surg*. 1997;226(3):248-57.
4. Kim MH, Lee SK, Seo DW, Won SY, Lee SS, Min YI. Tumors of the major duodenal papilla. *Gastrointest Endosc*. 2001; 54(5):609-20.
5. Robertson JF, Imrie CW. Acute pancreatitis associated with carcinoma of the ampulla of Vater. *Br J Surg*. 1987;74(5):395-7.
6. Tanasijtchouk T, Vaisbein E, Lachter J, Nassar F. Carcinoma of Papilla Vateri presenting as recurrent acute pancreatitis. *Acta Gastroenterol Belg*. 2004;67(3):309-310.
7. Erkan M, Kleeff J, Reiser C, Hinz U, Esposito I, Friess H et al. Preoperative acute pancreatitis in periampullary tumors: implications for surgical management. *Digestion*. 2007;75(2-3): 165-171.
8. Winter JM, Cameron JL, Olinio K, Herman JM, de Jong MC, Hruban RH et al. Clinicopathologic analysis of ampullary neo-

- plasms in 450 patients: implications for surgical strategy and long-term prognosis. *J Gastrointest Surg.* 2010; 14(2):379-387.
9. Wittau M, Scheele J, Golz I, Henne-Bruns D, Isenmann R. Changing role of surgery in necrotizing pancreatitis: a single-center experience. *Hepatogastroenterology.* 2010; 57(102-103):1300-1304.
 10. Asensio JA, Petrone P, Roldan G, Kuncir E, Demetriades D. Pancreaticoduodenectomy: a rare procedure for the management of complex pancreaticoduodenal injuries. *J Am Coll Surg.* 2003; 197(6):937-942.
 11. Standop J, Glowka T, Schmitz V, Schaefer N, Hirner A, Kalff JC. Emergency Kausch-Whipple procedure: indications and experiences. *Pancreas.* 2010;39(2):156-159.
 12. Stratigos P, Kouskos E, Kouroglou M, Chrisafis I, Fois L, Mavrogiorgis A et al. Emergency pancreatoduodenectomy (whipple procedure) for massive upper gastrointestinal bleeding caused by a diffuse B-cell lymphoma of the duodenum: report of a case. *Surg Today.* 2007;37(8):680-84.
 13. Vladov NN, Takorov IR, Mutafchiiski VM, Kjossev KT, Kazarov K, Mladenov N et al. Successful emergency pancreatoduodenectomy in a non-trauma patient. *Hepatogastroenterology.* 2007; 54(78):1844-1846.
 14. Z'graggen K, Strobel O, Schmied BM, Zimmermann A, Buchler MW. Emergency pancreatoduodenectomy in nontrauma patients. *Pancreas.* 2002;24(3):258-63.
 15. Naganuma S, Honda K, Noriki S, Kimura S, Murakami M, Koneri K et al. Ruptured mucinous cystic neoplasm with an associated invasive carcinoma of pancreatic head in a pregnant woman: report of a case and review of literature. *Pathol Int.* 2011; 61(1):28-33.
 16. Perera MT, Shimoda M, Kato M, Abe A, Yamazaki R, Sawada T et al. Life-threatening bleeding from duodenal varices due to pancreatic arterio-venous malformation: role of emergency pancreatoduodenectomy. *Hepatogastroenterology.* 2008; 55(86-87):1553-1556.
 17. Maeda H, Okabayashi T, Kobayashi M, Araki K, Kohsaki T, Nishimori I et al. Emergency pancreatoduodenectomy for pancreatic metastasis from renal cell carcinoma in a patient with von Hippel-Lindau disease: a case report. *Dig Dis Sci.* 2006;51(8):1383-1387.
 18. Koniaris LG, Mandal AK, Genuit T, Cameron JL. Two-stage trauma pancreaticoduodenectomy: delay facilitates anastomotic reconstruction. *J Gastrointest Surg* 2000; 4(4):366-369.
 19. Sakakima Y, Inoue S, Fujii T, Hatsuno T, Takeda S, Kaneko T et al. Emergency pylorus-preserving pancreatoduodenectomy followed by second-stage pancreatojejunostomy for a gastrointestinal stromal tumor of the duodenum with an intratumoral gas figure: report of a case. *Surg Today.* 2004;34(8):701-705.
 20. Sekino Y, Kobayashi A, Takagi S, Miwa S, Miyagawa S. Successful treatment for combined pancreatoduodenal injury by a second-stage pancreatojejunostomy following pancreatoduodenectomy. *Hepatogastroenterology.* 2004;51(60):1674-1675.
 21. Tuech JJ, Pessaux P, Regenet N, Bergamaschi R, Arnaud JP. Emergency pancreaticoduodenectomy with delayed reconstruction for bleeding: a life saving procedure. *Int J Pancreatol.* 2001;29(1):59-62.
 22. Miyagawa S, Makuuchi M, Kawasaki S, Ogiwara M. Second-stage pancreatojejunostomy following pancreatoduodenectomy in high-risk patients. *Am J Surg.* 1994;168(1):66-68.
 23. Fuks D, Piessen G, Huet E, Tavernier M, Zerbib P, Michot F et al. Life-threatening postoperative pancreatic fistula (grade C) after pancreaticoduodenectomy: incidence, prognosis, and risk factors. *Am J Surg.* 2009;197(6):702-709.
 24. Shimizu Y, Kimura F, Shimizu H, Yoshidome H, Ohtsuka M, Miyazaki M. The morbidity, mortality, and prognostic factors for ampullary carcinoma and distal cholangiocarcinoma. *Hepatogastroenterology.* 2008;55(82-83):699-703.
 25. Hartwig W, Maksan SM, Foitzik T, Schmidt J, Herfarth C, Klar E. Reduction in mortality with delayed surgical therapy of severe pancreatitis. *J Gastrointest Surg.* 2002;6(3):481-487.