

## Complex anatomical variant of inferior vena cava – a case study

C.M. Tanasi, F.D. Ungureanu, T. Hârşovescu, B. Balmeş

Faculty of Medicine and Dental Medicine, “Titu Maiorescu” University, Bucharest, Romania

### Rezumat

#### *Varianta anatomică complexă a venei cave inferioare - prezentare de caz*

Cazul prezintă multiple variante anatomice ale venei cave inferioare și afluenților acesteia care determină apariția de anomalii arteriale asociate. Materialul de studiu a fost prelevat de la un cadavru de sex feminin, cu vârsta de aproximativ 60 de ani în momentul decesului, care nu prezenta alte modificări morfologice ale vaselor sau viscerelor retroperitoneale. Metoda folosită a fost disecția clasică. Am descris o variantă de formare a venei cave inferioare asociată cu persistența arterelor renale duble bilaterale și modificarea raporturilor arterio-venoase în pediculii renali. Am stabilit corelații între dezvoltarea embriologică a venei cave inferioare și a vaselor renale, explicând mecanismele de apariție. Particularitățile acestui caz sunt legate de perturbarea dezvoltării succesive a arterelor renale în perioada procesului de ascensionare a rinichilor ca urmare a anomaliilor de dezvoltare a sistemului venei cave inferioare. Considerăm importantă cunoașterea de către chirurg a posibilelor variante anatomice ale vaselor mari retroperitoneale pentru interpretarea imagisticii angio CT și angio RMN în asemenea cazuri.

**Cuvinte cheie:** vena cavă inferioară, artera renală, vene postcardinale, anastomoza intersubcardinală

### Abstract

This case has multiple anatomical variants of the inferior vena cava and its branches which determine the appearance of associated arterial abnormalities. The study has been performed on a female corpse, aged average 60, with no other morphological changes of the blood vessels or retroperitoneal viscera. The method we used was classical dissection. We described a variant of the inferior vena cava formation and persistence of bilateral double renal arteries with changes of arterio-venous relations in the renal pedicles. We established correlations between the embryological development of the inferior vena cava and the renal vessels and we explained its appearance mechanisms. The peculiar aspect of the study is that anomalies in development of the inferior vena cava system have determined the disturbance of successive development of renal arteries during “ascensus renis” process. We consider important for the surgeon to have knowledge of possible anatomical variants of large retroperitoneal vessels in order to have a clear interpretation of the CT Angiography and Magnetic Resonance Angiography in such cases.

**Key words:** inferior vena cava, renal artery, post cardinal veins, intersubcardinal anastomosis

---

#### Corresponding author:

Dr. C.M. Tanasi  
Intr. Școlii nr. 10, Otopeni, jud. Ilfov,  
Romania  
E-mail: mihaitanasi@yahoo.com

---

### Introduction

Retroperitoneal space represents a topographic area with a specific pathology due to possibility of occurrence of certain anatomical variants that can complicate the surgical approach. Pathology of the retroperitoneal space involves a thoroughness

of surgical maneuvers based on good knowledge of that area topography and possible anatomical variants (1).

The hereinafter case represents an inferior vena cava formation variant, associated with variants of tributaries of this vein and abdominal aorta branches.

Clinical implications of inferior vena cava formation variants associated with originating variants of aorta branches are not usually obvious (2). Even though, vascular relations can determine changes in the hemodynamics – the angle between aorta and superior mesenteric artery has a compressing effect on duodenum; an anterior course of the right renal artery, due to arterial blood pressure, can induce stasis in the postrenal segment of inferior vena cava.

## Materials and Methods

The study has been performed on a female corpse, aged average 60, with no other morphological changes of the blood vessels or retroperitoneal viscera.

Dissection has pointed out the following pathological changes:

- large hepato- and splenomegaly with extended hepatic fibrosis;
- mediastinal and retroperitoneal large lymphadenitis which requested extended ablation of great retroperitoneal vessels together with kidneys and ureters.
- inferior vena cava has been cut off in the infrahepatic segment, in an angular plane, due to presence of lymphadenitis formations extremely adhesive to the excised portion (Fig. 1).

## Results and Discussions

We have noticed that inferior vena cava is formed from the convergence of the exterior right iliac vein and the resulting venous trunk by junction of left common iliac vein with the right internal iliac vein (Fig. 2).

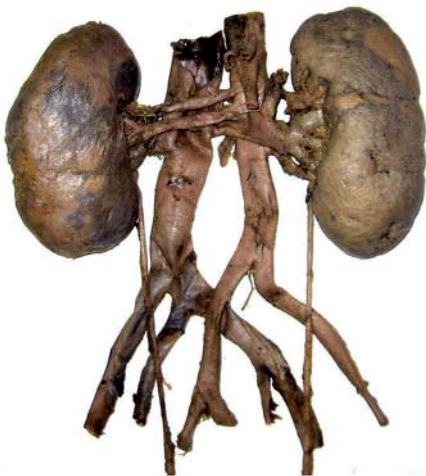

Figure 1.



Figure 2.



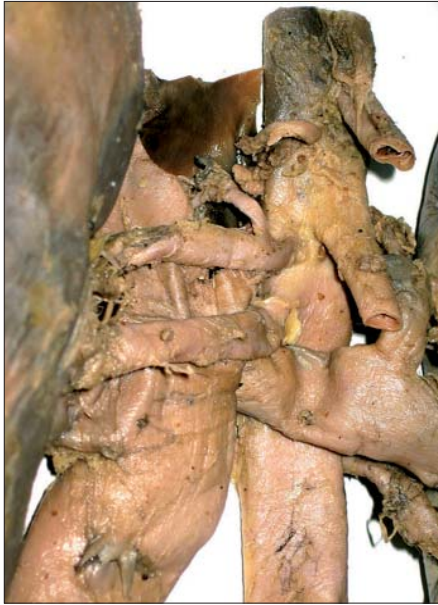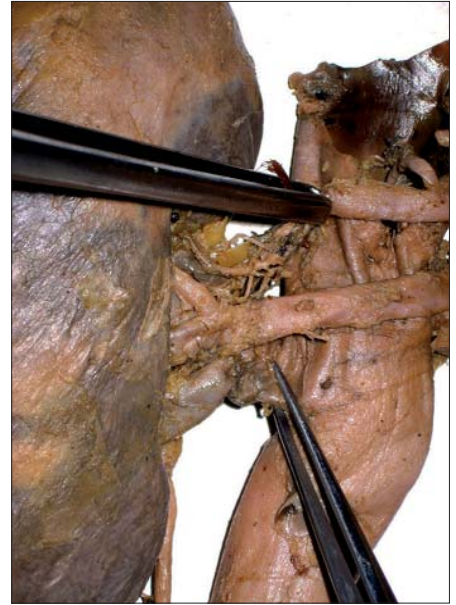
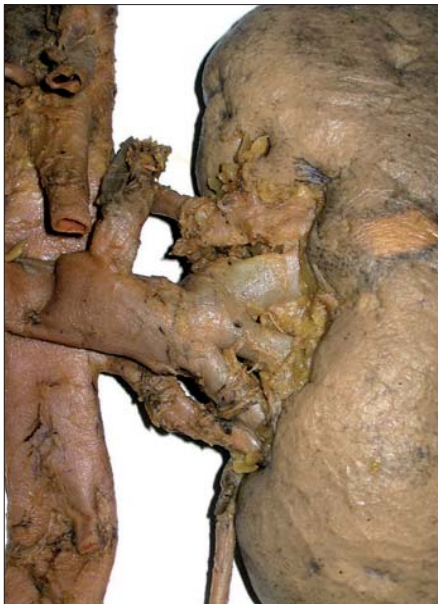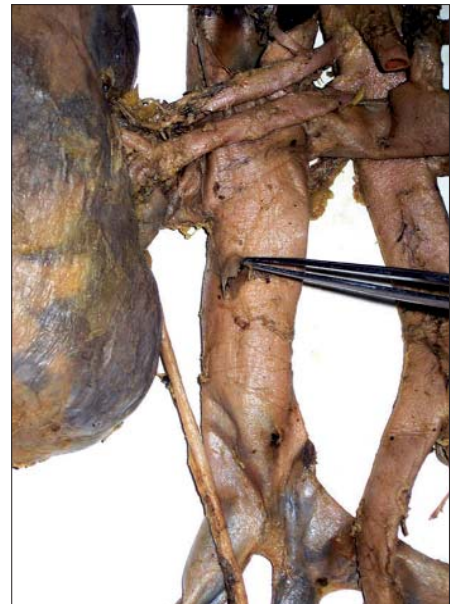Figure 3.

Bilaterally, accessory renal arteries are present (Fig. 3).

On the right side, renal arteries have an abnormal course, crossing anterior to the inferior vena cava (Fig. 4); therefore this anterior course of the right renal arteries induce modified intrinsic relations in the pedicle and right renal hilum (Fig. 5), the venous element being placed between the arteries and the renal pelvis.

By dissection, we have studied the relations and distribution of renal arteries.

On the right side, renal arteries have the following distribution (3): inferior renal artery gives a large arterial trunk for the inferior (classic, polar inferior) and middle (classic, antero-inferior) segments and a superior branch for the superior (classic, antero-superior) segment, all of them placed anterior to the veins. Superior renal artery gives a thin branch for the apical (classic, polar superior) segment and after detours the pedicle and distributes to the

*Figure 4.**Figure 5.**Figure 6.**Figure 7.*

posterior segment, coursing posterior to the renal pelvis.

On the left side, the origin of the superior renal artery is abnormally (4) placed posterior to the central vein of the right adrenal gland (Fig. 6).

Inferior renal artery origin is placed posterior and inferior to the left renal vein. Reaching nearby the hilum, both renal arteries are placed in the same plane with the left renal vein tributaries. The arteries are disposed superior and inferior to the veins.

On the left side, renal arteries have the following distribution: superior renal artery gives a branch that courses posterior the renal pelvis and distributes to the posterior segment, and then enter into the hilum and gives branches for the apical (classic, polar superior) segment and superior (classic, antero-superior) segment. Inferior renal artery gives

branches for the inferior (classic, polar inferior) and middle (classic, antero-inferior) segments.

We have also noticed the emergence of median sacral artery from the posterior part of aortic bifurcation as well as the right ovarian vein convergence on the anterior part of inferior vena cava (Fig. 7).

### ***Embryological correlations***

Due to complexity of its development stages, numerous anomalies may occur in the anatomy of the inferior vena cava system (3,5).

Initially, the embryonic infracardiac somatic venous circulation is represented by the two postcardinal veins, left and right, communicating caudally through the interpostcardinal

anastomosis which shall persist as left common iliac vein. While the abdominal viscera develops, the caliber of the two postcardinal veins becomes insufficient, and for this reason, another three pairs of venous channels develops. Therefore, from the medial towards lateral part of the embryo there are:

- subcardinal veins, in which drain the mesonephric veins (intersubcardinal anastomosis, a radial network placed anterior to the aorta, also called “renal collar”); from the intersubcardinal anastomosis develops the renal and gonadal veins;
- future azygos venous system that, in the end persists in the thorax;
- supracardinal veins, placed posterior to the aortic plane, will take over the intersegmentary venous drainage from the posterior cardinal veins.

Finally, inferior vena cava, from the inferior to the superior segments (6), develops from:

- junction of interpostcardinal anastomosis with the inferior right limb bud vein;
- a short segment of the initial portion of the right postcardinal vein;
- supracardinal right vein and intersubcardinal anastomosis will form the renal segment of the inferior vena cava;
- anastomosis with the umbilical-vitelline system will form the prerenal segment area of the inferior vena cava.

## Conclusions

We consider important for the surgeon to have the knowledge of possible anatomical variants of the great retroperitoneal vessels in order to have a clear interpretation of the CT Angiography and Magnetic Resonance Angiography in such cases.

Anatomical variants noticed at the inferior vena cava level, both in formation and renal segment, represent a complex of changes due to a main cause: origin, postrenal segment and junction between post- and prerenal segments develops only from the right supracardinal vein, associated with excessive involution of subcardinal and postcardinal veins.

Formation and involution disorders of radial intersubcardinal anastomosis determine the course variants and relations of renal veins with the great retroperitoneal vessels.

Venous anomalies have determined the disturbance of successive development of renal arteries during “ascensus renis” process.

## Reference

1. Andros G. The relationship of the inferior vena cava and its branches to aortoiliac surgery. *Vasc Endovascular Surg.* 2000; 34:67-76.
2. Sharaf M. Recurrent left-leg venous thrombosis in a woman despite a therapeutic international normalized ratio. *CMAJ.* 2005;173(9):1032.
3. Standring S. *Gray's anatomy*, 39th edition. Edinburgh: Elsevier Churchill Livingstone; 2005. p. 1045-1049, 1120-1122, 1274-1277
4. Stack SP, Rösch J, Cook DM, Sheppard BC, Keller FS. Anomalous left adrenalvenous drainage directly into the inferior vena cava. *J Vasc Interv Radiol.* 2001;12(3):385-7.
5. Minniti S, Visentini S, Procacci C. Congenital anomalies of the venae cavae: embryological origin, imaging features and report of three new variants. *Eur Radiol.* 2002;12(8):2040-55. Epub 2002 Mar 19.
6. Sadler TW. *Langman's Medical Embriology*, 10th edition, Philadelphia: Lippincott, Williams & Wilkins; 2006. p. 186-189.