

## Cannieu-Riche anastomosis of the ulnar to median nerve in the hand: case report

G. Paraskevas, O. Ioannidis, S. Martoglou

Department of Anatomy, Medical School, Aristotle University of Thessaloniki, Thessaloniki, Greece

### Rezumat

#### *Anastomoza Cannieu-Riche a nervului ulnar cu nervul median: prezentare de caz*

Am decelat la un cadavru de sex masculin un tip nou de anastomoză Cannieu-Riche foarte lungă între partea proximală a trunchiului profund a nervului ulnar pentru adductorul policelui și ramul trunchiului recurent al nervului median pentru capătul superficial al flexorului scurt al policelui. Semnificația clinică a unei astfel de comunicații este posibilă prezervare a funcției, totală sau parțială, mușchilor tenari prin nervul ulnar în cazul leziunilor nervului median. Ignorarea acestei anomalii poate duce la dificultăți în interpretarea datelor clinice, chirurgicale și electroneuromiografice. Prezentăm incidența, dubla inervație și semnificația clinică a anastomozei Cannieu-Riche și propunem o nouă clasificare a tipurilor variate a acestei anastomoze nervoase.

**Cuvinte cheie:** anastomoză Cannieu-Riche, nervul ulnar, nervul median

### Abstract

We observed in a male cadaver the presence of a new type of very long Cannieu-Riche anastomosis between the proximal portion of the deep branch of the ulnar nerve for the adductor

pollicis and ramus of the recurrent branch of the median nerve to the superficial head of the flexor pollicis brevis. The clinical relevance of such a communication is the possible preservation of the function of all or part of thenar muscles from the ulnar nerve in case of median nerve lesion. The ignorance of that anomaly can induce obscure clinical, surgical and electroneuromyographical findings. We report on the incidence, the double innervation and the clinical significance of Cannieu-Riche anastomosis and provide a new classification of the various types of this neural connection.

**Key words:** Cannieu-Riche anastomosis, neural loop, ulnar nerve, median nerve

### Introduction

As it is known communication between branches of motor nerves is of high significance for the physician because it may be a causal factor for double motor innervation of a specific muscle. Anastomosis between the muscular-motor branch of the median nerve in the palm of the hand and the profundus ramus of the ulnar nerve is called Cannieu-Riche anastomosis. Cannieu in 1896 reported an anastomosis between the recurrent branch of the median nerve and the deep branch of the ulnar nerve in 3 out of the 20 hands, which he dissected (1). Riche in 1897 reported the presence of an anastomotic loop in 3 out of 12 dissected hands (2). Cannieu and Riche found that the communication was mostly taken part between a ramus of the recurrent branch of the median nerve for the superficial head of the flexor pollicis brevis and the ulnar nerve branch for the deep head of the same muscle. The anastomotic loop in all their cases was passing through the remaining

Corresponding author:


Dr. George Paraskevas  
Amfoterou 38, 54250, Thessaloniki  
Greece  
E-mail: g\_paraskevas@yahoo.gr

space between the two heads of the adductor pollicis muscle. Cannieu and Riche hadn't investigated the case of likely double innervation of thenar muscles (1,2). However, earlier Brooks in 1886 had already found double innervation of the flexor pollicis brevis in 19 out of 31 hands (3).

That relative unknown neural anastomosis, which in view of its ansiform direction through the thenar muscles has been called "thenar ansa" by Harness et al in 1971 (4), in cases of a median or ulnar nerve damage could lead the physician in misdiagnosis based upon an erroneous interpretation of the clinical, electroneuromyographical and surgical findings.

## Case report

During the dissection research taking part to our Department of Anatomy we noticed in a 65 year-old male cadaver an unusual neural anastomosis in his left hand. That anastomosis was observed between the deep branch of the ulnar nerve for the adductor pollicis 1cm approximately below the lower orifice of Guyon's canal and the ramus of the recurrent branch of the median nerve to the superficial head of flexor pollicis brevis. That Cannieu-Riche anastomosis was extremely long (2.7 cm). We didn't know if it contains motor, sensory or mixed fibers; we supposed that this neural loop supplies motor innervation to the superficial head of the flexor pollicis brevis. Previously, we resected the flexor tendons in order to make the deep branch of ulnar nerve more visible (Fig. 1). Our finding was detected by photograph and supplementary diagram. The measurement has been made by the use of a digital caliper with a sensitivity of 0.01 cm, while the cadaver's medical history didn't reveal



**Figure 1.** Cannieu-Riche anastomosis (left hand) between the deep branch of the ulnar nerve for the adductor pollicis and the ramus of the recurrent branch of the median nerve to the superficial head of the flexor pollicis brevis. That communication is extremely long (2.7 cm) and painted in white color. (A: Cannieu-Riche anastomosis, 1: deep branch of ulnar nerve, 2: recurrent branch of median nerve, 3: ramus of the recurrent branch to the superficial head of flexor pollicis brevis, 4: common palmar digital branches of median nerve)

any previous pathological conditions or surgical procedures undertaken on the left hand.

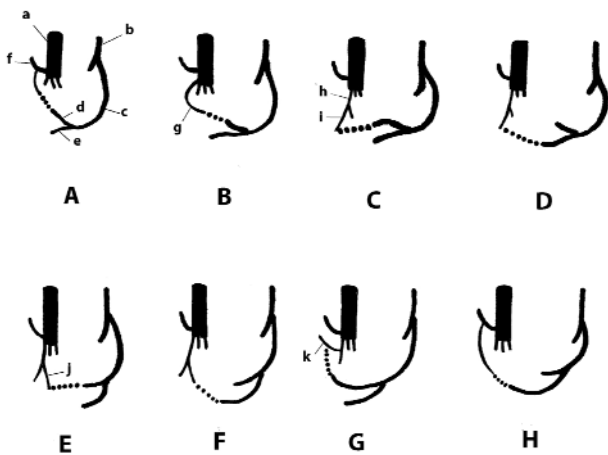
## Discussion

The incidence of Cannieu-Riche anastomosis is a controversial matter. It was found in 0 out of 216 hands (5), in 3 out of 20 hands (1), and in 1 out of 32 hands (6). Also, Day et al found double innervation of the deep head of the flexor pollicis brevis in 5 out of 24 hands and in 7 out of 30 hands of the superficial head of the same muscle (7). That thenar ansa may be found more frequent; so many investigators refer to this connection as being a common arrangement of thenar innervation. Harness et al found it in 27 out of 35 hands (77%) (4), while Sala after electromyographical examinations combined with percutaneous stimulation reported double innervation of the flexor pollicis brevis in three out of every four hands examined (75%) (8). Cruveilhier found that the superficial head of the flexor pollicis brevis received double innervation by ulnar and median nerve branches in 17 out of 25 cases (68%) (9). Homma et al found a Cannieu - Riche anastomosis in four of six hands (66.6%) (10). In clinical cases Hight reported that out of 45 patients with complete division of the ulnar and median nerves, only 5 presented complete paralysis of the flexor pollicis brevis (11).

After electrophysiological examination of the ulnar and median nerve, Riche-Cannieu anastomosis was detected in 125 out of 150 hands (83,3%) (12). Day et al when used better dissection techniques, found higher percentage of double innervation of the flexor pollicis brevis (7), whereas Harness et al speculated that in their cases which were no anastomosis it is possible that the fibres forming it were so few that the anastomosis was not encountered (4).

The double innervation which is due to the thenar ansa concerns usually the flexor pollicis brevis. Rami originating from the ansa may innervate the medial part of the adductor pollicis muscle. Kimura et al found that the mean ulnar nerve innervation ratio (UNIR) in the abductor pollicis brevis, that is usually innervated by median nerve was 27.6% ( $\pm$  16.4%). In the American black population, this UNIR percentage was statistically smaller than in the American caucasian or hispanic population (12). In our case the Cannieu-Riche anastomosis innervates completely or the greatest portion of the flexor pollicis brevis. The nature, incidence and direction of fibres that a Cannieu - Riche anastomosis conveys is relatively unknown (13). The normal distribution of digital afferents suggests that such anastomoses are formed primarily by motor axons (14).

We propose the following classification of the various types of Cannieu-Riche anastomosis: i) the most common type of anastomosis is the one between the profundus ramus of the ulnar nerve for the deep head of flexor pollicis brevis and the ramus of the recurrent branch of the median nerve (1,2) (Fig. 2A). ii) The anastomosis takes place between a separate branch of the median nerve to the superficial head and the ulnar branch to deep head of flexor pollicis brevis (15) (Fig. 2B). iii) The anastomosis is between the digital branch to



**Figure 2.** Schematic drawing of the classification of the various types of Cannieu – Riche anastomosis. (a: median nerve, b: ulnar nerve, c: deep branch of ulnar nerve, d: branch to deep head of flexor pollicis brevis, e: branch to adductor pollicis, f: recurrent branch, g: separate branch of median nerve to the superficial head of flexor pollicis brevis, h: first common digital nerve, i: digital branch to thumb, j: digital branch to index finger, k: distal accessory thenar branch). The symbol (.....) indicates the Cannieu – Riche anastomosis

thumb and the ulnar branch to deep head of flexor pollicis brevis (4,16) (Fig. 2C). iv) The anastomosis is between branch of the digital nerve of the thumb and the ulnar branch to the adductor pollicis (Riche D cited by 16) (Fig. 2D). v) The anastomosis is between digital branch to index finger and ulnar branch to profundus head of flexor pollicis brevis (17) (Fig. 2E). vi) The anastomosis is between the digital palmar branch to the index finger and the ulnar branch to adductor pollicis (6) (Fig. 2F). vii) The anastomosis is between the distal accessory thenar branch of the first common digital nerve and the deep branch of the ulnar nerve for the deep head of the flexor pollicis brevis (10,17) (Fig. 2G). viii) The anastomosis of our case is between the ramus of the recurrent branch of median nerve to the superficial head of flexor pollicis brevis and the deep branch of ulnar nerve to the adductor pollicis and constitutes a new type of Cannieu – Riche anastomosis (Fig. 2H).

We report on the following cases of Cannieu – Riche anastomosis that seem to appear significant clinical value: a) A left median nerve lesion in which there was a paradoxical preservation of the mobility of the left abductor pollicis brevis muscle (18). b) Two cases of bilateral carpal tunnel syndrome in which the patients had significant preservation of function and minimal muscle atrophy (19). c) Two cases with nearly exclusive ulnar innervation of thenar muscles because of the presence of palmar communication between ulnar and median nerve (14). d) An ulnar neuropathy at the elbow with only partial paralysis of the abductor pollicis brevis (20). e) Two patients with carpal tunnel syndrome with partial and complete innervation, respectively, of abductor digiti minimi

by a ramus of the median nerve branching at the carpal tunnel region (21). f) A case of a deep branch ulnar neuropathy complicated by a Riche-Cannieu anastomosis. The clinical presentation was similar to that of motor neuron disease (22). At last, it is worth to mention that erroneous diagnosis regarding the median nerve function after injury at the wrist is presumably occurring in approximately one-third of cases (23).

The knowledge of this anastomosis is essential because the presence of such a neural loop can cause confusing clinical, surgical and electromyographical findings in case of median or ulnar damage or entrapment.

## References

1. Cannieu A. Recherche sur l'innervation de l'eminence thenar par le cubital. J Med Mordeaux. 1896;377-9.
2. Riche D. Le nerf cubital et les muscles de l'eminence thenar. Bull Mem Soc Anat Paris 1897;251-2.
3. Brooks H. Variation in the nerve supply of the flexor brevis pollicis muscle. J Anat 1886;20:641-4.
4. Harness D, Sekeles E. The double anastomotic innervation of thenar muscles. J Anat 1971;109:461-6.
5. Budak F, Bolukbas O, Ozmenoglu M. Innervation anomalies in the upper and lower extremities. Norol Bil D 1994;11:61-5.
6. Sarikcioglu L, Sindel M. A variant of the Cannieu-Riche communication: Case report. Morphologie. 2000;86:35-7.
7. Day M, Napier J. The two heads of flexor pollicis brevis. J Anat 1961;95:123-30.
8. Sala E. Electromyographic study of the innervation of the flexor brevis and opponent muscles of the thumb. Riv Patol Nerv Ment. 1958;80:131-9.
9. Cruveilhier J. Anatomie descriptive, 1st Ed. Paris: Bechet Jeune; 1834.
10. Homma T, Sakai T. Thenar and hypothenar muscles and their innervation by the ulnar and median nerves in the human hand. Acta Anat. 1992;145:44-49.
11. Highet WB. Innervation and function of the thenar muscles. Lancet. 1943;i:227-30.
12. Kimura I, Ayyar DR, Lippmann SM. Electrophysiological verification of the ulnar to median nerve communications in the hand and forearm. Tohoku J Exp Med. 1983;141(3):269-74.
13. Mannerfelt L. Studies on the hand in the ulnar nerve paralysis. Acta Orthop Scand (Suppl). 1996;87:1-176.
14. Sahcs G, Raynor E, Shefner J. The all ulnar motor hand without forearm anastomosis. Muslce Nerve. 1995;18:309-13.
15. Chevrier G. Note sur l'anastomose de Riche et Cannieu. Bull Mem Soc Anat. Paris. 1904.
16. Hovelacque A. Anatomie des nerfs craniens et rachidiens et du systeme grand sympathique. Paris: Ed. Doin; 1927.
17. Stancić MF, Eskinja N, Stosić A. Anatomical variations of the median nerve in the carpal tunnel. Int Orthop. 1995;19(1):30-4.
18. Tamagawa C, Shiga K, Ohsima Y, Tokunaga D, Nakagawa M. Riche-Cannieu anastomosis and a paradoxical preservation of the thenar muscles in carpal tunnel syndrome: a case report. No To Shinkei. 2004 Jan;56(1):53-8. [Article in Japanese]
19. Refaian M, King J, Dumitru D, Cuetter A. Carpal tunnel syndrome and the Riche-Cannieu anastomosis: electrophysiologic findings. Electromyogr Clin Neurophysiol. 2001;41:377-82.
20. Dumitru D, Walsh NE, Weber CF. Electrophysiologic study of the Riche-Cannieu anomaly. Electromyogr Clin Neurophysiol.

- 1988;28(1):27-31.
21. Seradge H, Seradge E. Median innervated hypothenar muscle: anomalous branch of median nerve in the carpal tunnel. *J Hand Surg Am.* 1990;15(2):356-9.
22. Saperstein DS, King RB. Motor neuron presentation of an ulnar neuropathy and Riche-Cannieu anastomosis. *Electromyogr Clin Neurophysiol.* 2000;40(2):119-22.
23. Kline DG, Hubson AR. Acute injuries of the peripheral nerve. In: Voumans JR, editor. *Neurological surgery*, 3rd edition. Philadelphia: Saunders; 1990.