

Primary biliary cystadenocarcinoma mimicking a complicated hydatid cyst

V. Genç, A. Çakmak, M. Akbari, E. Orozakunov, S. Ersöz

Department of Surgery, Ankara University Medical School, Ankara, Turkey

Rezumat

Chistadenocarcinom biliar primar mimând chist hidatic complicat

Chistadenocarcinomul ficatului este o neoplazie rară cu origine în epiteliul hepatobiliar. Localizarea primară a acestei tumori este în general intrahepatică la nivelul lobului drept. Prezentăm cazul unui pacient de 53 ani cu un chistadenocarcinom intrahepatic aflat în urmărire pentru chist hidatic hepatic de 8 ani. El a fost admis în centrul nostru cu icter și scăderea apetitului. Ecografia și tomografia computerizată evidențiază o leziune chistică asemănătoare cu un chist hidatic stadiu II. Rezonanța magnetică, relevă leziunea chistică deschisă în arborele biliar. Laparotomia exploratorie a relevat infiltrație peritoneală care histopatologic a fost chistadenocarcinom biliar. Din nefericire diagnosticul corect a fost tardiv și managementul curativ nu a fost posibil.

Cuvinte cheie: chistadenocarcinom, biliar, chist hidatic

Abstract

Cystadenocarcinoma of the liver is a rare neoplasm that originates from hepatobiliary epithelium. Primary location of this tumor is generally intrahepatic and most cases are in the right hepatic lobe. Herein we present a case of intra-

hepatic cystadenocarcinoma in a 53-year-old man who had been followed up for 8 years as hydatid cyst disease of the liver. He was admitted to our hospital with jaundice and loss of appetite. Ultrasound and computed tomography showed a cystic lesion that looked like type II cyst hidatic. Thereafter magnetic resonance imaging revealed a cystic lesion associated with biliary tree. On diagnostic laparotomy peritoneal infiltrations were observed and pathologic examination revealed a biliary cystadenocarcinoma and peritonitis carcinomatosa was diagnosed. Unfortunately correct diagnosis was extremely late and no curative management was possible.

Key words: cystadenocarcinoma, biliary, hydatid cyst

Introduction

Cystadenocarcinoma of the liver is a rare neoplasm that originates from hepatobiliary epithelium.(1) Primary location of this tumor is generally intrahepatic and most cases are in the right hepatic lobe.(2) Herein we present a case of intrahepatic cystadenocarcinoma in a 53-year-old man who had been followed up for 8 years as hydatid cyst disease of the liver.

Case Report

A 53 year-old-man who had been followed up for 8 years as hydatid cyst disease of the liver was admitted to our hospital with the complaint of jaundice, loss of appetite, pallid stool and urine darkness. The patient first applied to the hospital because of intermittent abdominal pain in the year 2000. Ultrasonography (US) and computed tomography (CT) was performed and a cystic mass was detected. Serological markers for hydatid disease were negative. An operation was

Corresponding author: Volkan Genç MD.
Çiğdem Mah. 28. cad. 13/23, 06520
Çankaya Ankara Turkey
Tel.: +90 312 3103333 - 2676
Fax: +90 312 3103989
E-mail: volkan@medicine.ankara.edu.tr

proposed for this mass which was thought as a cyst hydatidic by the radiologists, but the patient declined. So the patient was being followed up with US and CT which were performed for three times from 2000 to 2008 and all of them showed a cystic mass that was described as a cyst hydatidic.

The patient's complaints were increasing for the last 3 months when he was last admitted to our hospital. On physical examination a mass about 5 cm in size was palpated in upper right quadrant of abdomen. Blood tests revealed mild anemia (11.8 g/dL), hyperbilirubinemia (total bilirubin: 2.86 mg/dl, direct bilirubin: 1.6 mg/dl), elevated liver function tests (LDH: 422 UI/L, AST: 162 UI/L, ALT: 84 IU/L, GGT: 84 IU/L, ALP: 1680 IU/L) and moderate leucocytosis (WBC: 15.4×10^3). Serological markers for hydatid disease were still negative. Serum alpha-fetoprotein (AFP), carcinoembryonic antigene (CEA) and CA19-9 were all within normal limits.

Hepatobiliary US showed a mass 5 x 7 cm in size that looked like type II cyst hidatic. CT showed a cyst in the right liver lobe with a largest diameter of 8 cm and this cyst was suspected as hydatidic cyst (Fig. 1). The next step consisted of MRI (magnetic resonance imaging) and MRCP (magnetic resonance cholangiopancreatography) due to suspicion of hydatidic cyst perforating biliary tree. MRI and MRCP showed moderate hepatomegaly with a cystic lesion with solid components and septated wall in right hepatic lobe, 8,5 x 7 cm in size with irregularity in shape and compressing adjacent bile ducts, dilatation of right intrahepatic biliary tree and perihepatic minimal fluid level. Common hepatic duct could not be visualized but paraceliac, portocaval, periportal and para-aortic multiple lymphadenopathy were seen (Fig. 2-3).

He underwent a subcostal laparotomy with a suspicion of complicated hydatidic cyst. A tumoral lesion of 8-9 cm in size in right hepatic lobe was found. Moderate ascitis and disseminated metastatic implants were also detected on omentum and Douglas' cavity. Biopsy from these lesions was done and frozen sectioning study revealed malignancy implants. Advanced pathologic studies documented biliary cystadenocarcinoma.

Discussion

Hepatobiliary cystadenomas and cystadenocarcinomas are rare neoplasm. While they constitute less than 5% of all solitary nonparasitic liver cysts, the incidence of biliary cystadenocarcinoma among hepatic malignant epithelial tumors has been reported to be as low as 0.41% (1,2). Biliary cystadenocarcinoma arise from an intra-extrahepatic bile duct or pre-malignant cystadenoma. However malignant transformation of biliary cystadenomas has been described in about 25% of cases. Primary location of this tumor is generally intrahepatic and most cases are located near the hepatic hilum, particularly in segment 4 (3).

Cystadenocarcinomas are usually detected incidentally while diagnostic imaging for other complaints. Most of these patients are asymptomatic until the tumor reaches a considerable size and this time most commonly reported symptoms are right abdominal pain, abdominal swelling, palpable mass, anorexia and nausea. Rarely, patients present

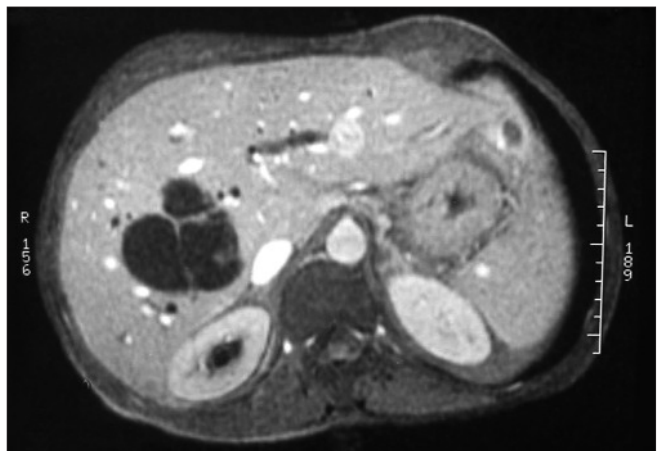


Figure 1. CT scan appearance of the intrahepatic cystic mass

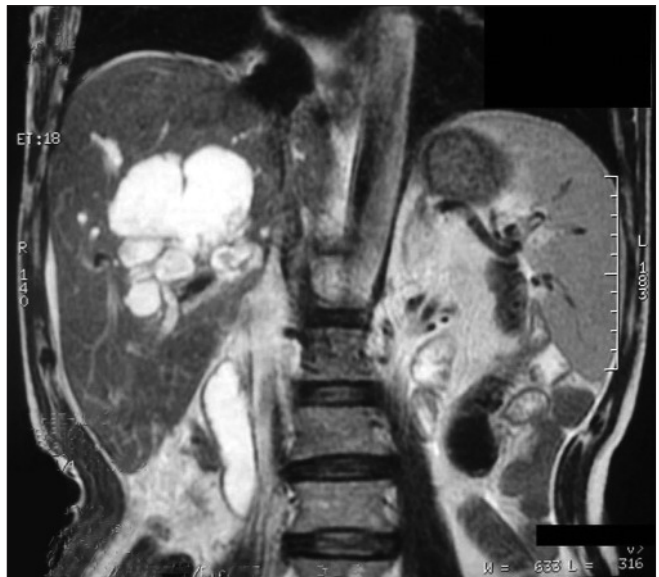

Figure 2. MRI appearance of the mass

with jaundice secondary to obstruction or compression of the biliary system (4,5).

Common laboratory findings are hyperbilirubinemia, increased serum level of ALT, AST, GGT and ALP. Some authors have suggested that CA19-9 serum levels can be increased significantly in patients with cystadenocarcinoma (6,7), but some authors also have reported that there are no distinct tumor markers (4,5). We also detected normal serum level of tumor markers.

Abdominal CT, US and MRI are the most useful diagnostic measures for these neoplasm. While ultrasound usually reveals a cystic lesion, CT may be helpful to see mural nodules or wall thickness that should increase the suspicion of cystadenocarcinoma (8). Nevertheless MRI in combination with MRCP is a helpful technique to determine the diagnosis and the extension of hepatobiliary cystic tumors (9). But it is not always possible to accurately distinguish biliary cystadeno-

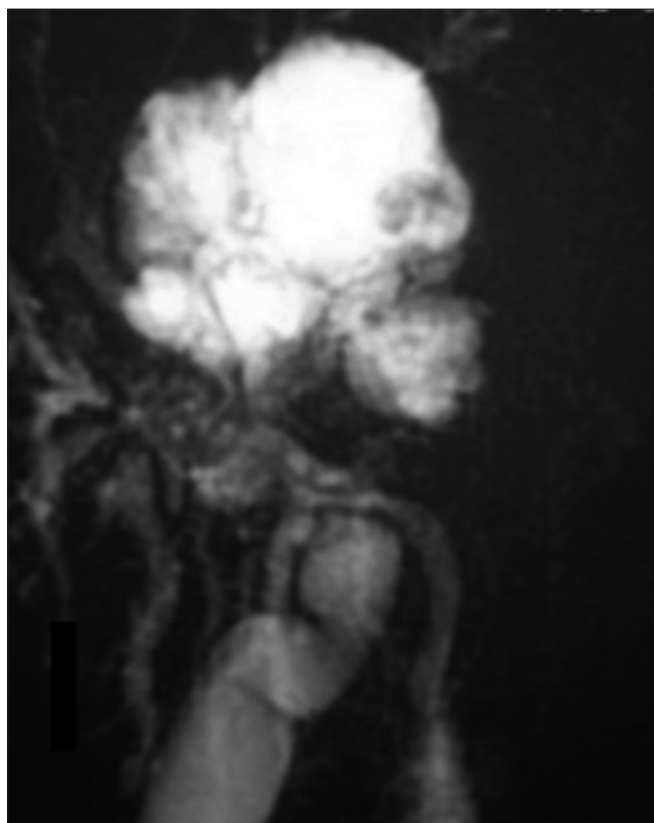


Figure 3. MRCP appearance of the mass association with intrahepatic biliary tree

carcinoma from other hepatic cysts such as hydatid cyst pre-operatively. So that histopathological examination is required for definitive diagnosis.

The use of percutaneous biopsy for this aim is not adequate due to peritoneal dissemination in case of malignancy (4). Biopsy is done with laparoscopy or open abdominal surgery for correct diagnosis.

Serologic tests of hydatid disease are very important in the diagnosis and should not underestimated by clinicians. Our patient had been followed up for 8 years as hydatid cyst disease of the liver although serologic tests was negative. Because of

this, investigators should suspect a cystadenomatous tumor when negative serologic tests are combined with a liver cyst in countries with a high prevalence of hydatid disease. Complete surgical resection is the recommended therapy for such lesions. Clinically these tumors can be observed incidentally at laparoscopic or open abdominal surgery. Although abdominal CT, USG and MRCP are the most useful diagnostic measures for these neoplasm, excisional biopsy is needed to confirm the diagnosis

References

1. Ishak KG, Willis GW, Cummins SD, Bullock AA. Biliary cystadenoma and cystadenocarcinoma: report of 14 cases and review of the literature. *Cancer*. 1977;39(1):322-38.
2. Takayasu K, Muramatsu Y, Moriyama N, Yamada T, Hasegawa H, Hirohashi S, et al. Imaging diagnosis of bile duct cystadenocarcinoma. *Cancer*. 1988;61(5):941-6.
3. Sato M, Watanabe Y, Tokui K, Kohtani T, Nakata Y, Chen Y, et al. Hepatobiliary cystadenocarcinoma connected to the hepatic duct: a case report and review of the literature. *Hepatogastroenterology*. 2003;50(53):1621-4.
4. Erdogan D, Busch OR, Rauws EA, van Delden OM, Gouma DJ, van-Gulik TM. Obstructive jaundice due to hepatobiliary cystadenoma or cystadenocarcinoma. *World J Gastroenterol*. 2006;12(35):5735-8.
5. Lempinen M, Halme L, Numminen K, Arola J, Nordin A, Mäkisalo H. Spontaneous rupture of a hepatic cystadenoma and cystadenocarcinoma: report of two cases. *J Hepatobiliary Pancreat Surg*. 2005;12(5):409-14.
6. Horsmans Y, Laka A, Gigot JF, Geubel AP. Serum and cystic fluid CA19-9 determinations as a diagnostic help in liver cysts of uncertain nature. *Liver*. 1996;16(4):255-7.
7. Thomas JA, Scriven MW, Puntis MC, Jasani B, Williams GT. Elevated serum CA 19-9 levels in hepatobiliary cystadenoma with mesenchymal stroma. Two case reports with immunohistochemical confirmation. *Cancer*. 1992;70(7):1841-6.
8. Yu FC, Chen JH, Yang KC, Wu CC, Chou YY. Hepatobiliary cystadenoma: a report of two cases. *J Gastrointest Liver Dis*. 2008;17(2):203-6.
9. Lewin M, Mourra N, Honigman I, Fléjou JF, Parc R, Arrivé L, et al. Assessment of MRI and MRCP in diagnosis of biliary cystadenoma and cystadenocarcinoma. *Eur Radiol*. 2006;16(2):407-13. Epub 2005 Jun 28.