

## Parastomal Hernias – Clinical Study of Therapeutic Strategies

E. Târcoveanu, A. Vasilescu, E. Cotea, N. Vlad, M. Palaghia, N. Dănilă, M. Variu

First Surgery Department "I. Tănăsescu – Vl. Buțureanu", "Gr.T. Popa" University of Medicine and Pharmacy, Iași, Romania

### Rezumat

#### *Eventrațiile parastomale – studiu clinic asupra strategiilor terapeutice*

Eventrațiile parastomale sunt defecte parietale adiacente locurilor de stomie: ileostomie și colostomie. Incidența este variabilă, acestea fiind în general subestimate.

**Material și Metodă:** Între 2001-2010 în Clinica I Chirurgie Iași, au fost tratate 861 eventrații postoperatorii, din care 31 au fost eventrații parastomale întâlnite la 26 de pacienți (3%), din care 5 au fost recidive. Eventrațiile parastomale au fost explorate clinic, imagistic și intraoperator. Deoarece studiul nostru și literatura de specialitate au demonstrat că reparația cu plasă este cel mai bun procedeu în tratamentul eventrațiilor parastomale, în 2010 am inițiat un studiu prospectiv, randomizat, în care am realizat profilaxia cu plasă de polipropilen, în momentul efectuării colostomiei. Au fost înrolați în studiu 20 de pacienți cu colostomii definitive la care am implantat plasă la intervenția primară comparați cu 22 de pacienți la care s-a realizat colostomie simplă fără plasă. Criteriile de includere au fost: pacienți cu cancer rectal inferior, stadiu II-III, iradiat, cu obezitate, cu istoric de hernii sau eventrații și bolnavi activi care depun efort fizic.

**Rezultate:** Eventrațiile parastomale au fost asimptomatice, doar șase cazuri au necesitat tratament chirurgical în urgență. Am utilizat procedeul anatomic în 16 de cazuri (4 cazuri cu

eventrații parastomale recidivate, repoziționarea stomiei într-un caz), repararea cu plasă în 15 cazuri (un caz cu eventrație parastomală recidivată, repoziționarea stomiei în 5 cazuri). Ca morbidități postoperatorii am înregistrat 4 plăgi infectate (un caz după reparație cu plasă care a necesitat reintervenție cu ablația acesteia) și necroza colostomei într-un caz de eventrație parastomală strangulată cu evoluție postoperatorie gravă și deces. Recidiva după procedeul anatomic a fost observată în 6 cazuri, după reparare cu plasă într-un singur caz, și nicio recidivă după repoziționarea stomiei. Pacienții la care am utilizat profilaxia cu plasă de polipropilen, în momentul efectuării colostomiei pentru a reduce riscul eventrațiilor parastomale au fost urmăriti în medie 20 de luni (între 12 și 28 de luni), prin examen clinic și ecografic la fiecare 3 luni. În lotul pacienților cu colostomie simplă fără plasă am înregistrat 6 recidive (27,2%) și niciuna în lotul cu plasă. Nu a fost nicio complicație postoperatorie la pacienții din grupul cu plasă profilactică.

**Concluzii:** Eventrațiile parastomale sunt afecțiuni relativ rare raportate la numărul de eventrații postoperatorii. Creșterea incidenței este legată de creșterea speranței de viață a bolnavilor colostomizați, cu cancer rectal. Utilizarea profilactică a plasei în momentul efectuării colostomiei este o procedură sigură și care reduce riscul apariției eventrațiilor parastomale.

**Cuvinte cheie:** eventrații parastomale, reparare cu plasă, profilaxie, colostomie

---

#### Corresponding author:

Alin Vasilescu, MD  
First Surgery Department "I. Tănăsescu – Vl. Buțureanu", "Sf. Spiridon" Hospital  
no. 1 Independentei Street, 700111, Iași  
E-mail: vasilescu.alin@gmail.com

---

#### Abstract

Parastomal hernias are parietal defects adjacent to the stoma site, after ileostomy and colostomy. Their incidence is variable and they are generally underestimated.

**Methods:** Between 2001 and 2010 at the First Surgical Clinic Iasi, we treated 861 incisional hernias, of which there were 31 parastomal hernias in 26 patients (3%), 5 of which were recurrent parastomal hernias. Parastomal hernias have been explored clinically, through imaging and intraoperatively. Because our experience and literature review have demonstrated that a mesh repair is a safe procedure in the treatment of parastomal hernia, in 2010 we initiated a prospective randomized trial on the use of prophylactic polypropylene mesh at the time of stoma formation to reduce the risk of parastomal hernia. We enrolled in the study 20 patients with mesh implanted at the primary operation and 22 patients without mesh. The inclusion criteria were: patients with low rectal cancer, stage II-III, irradiated, obese, with a history of hernias, patients who do physical work.

**Results:** Most parastomal hernias were asymptomatic; only six cases with parastomal hernias required emergency surgical treatment. We performed local tissue repair in 16 cases (4 cases with recurrent parastomal hernia, stoma relocation in one case), sublay mesh repair in 15 cases (one case with recurrent parastomal hernia; stoma relocation in 5 cases). Postoperative morbidity registered included 4 wound infections (one case after mesh repair which required surgical reintervention) and stoma necrosis in one case with strangulation parastomal hernia with severe postoperative evolution and death. After local tissue repair recurrences were seen in 6 cases, after mesh repair we registered recurrence only in one case and no relapse after the relocation of the stoma. The patients with prophylactic mesh at the time of stoma formation to reduce the risk of parastomal hernia were followed for a median of 20 months (range 12 to 28 months) by clinical examination and ultrasound exam every 3 months. We registered 6 recurrences (27,2%), all in the no mesh cohort. We have not seen any morbidity in patients from the mesh group.

**Conclusions:** Parastomal hernia is a relatively rare disease compared to the number of incisional hernias. With increasing life expectancy stands we noted increased incidence of parastomal hernia as well. Prophylactic use of mesh during the primary operation is a safe procedure and reduces the risk of parastomal hernia.

**Key words:** parastomal hernia, mesh repair, prophylaxis, colostomy

## Introduction

Parastomal hernias are parietal defects adjacent to the stoma site, after ileostomy and colostomy. Although they are rarely encountered they determine special therapeutic problems. The incidence is variable, they are generally underestimated and are probably at 30-50%, with one-third requiring operative correction (1). The increase in incidence is related to the increase in life expectancy of patients with colorectal cancer. The main etiologies are given technical errors, stoma outside

the sheath of the rectus abdominis muscle and patient's predisposing factors (obesity, wound infections, malnutrition, old age, pulmonary diseases, immune status, cancer recurrence) (2).

The most important problem is a high recurrence of parastomal hernia after suture repair or relocation of the stoma, mesh repair by open or laparoscopic approach resulting in much lower recurrence rates. Because yet many more studies are needed to determine which method of repair is better, long-term follow-up of the various techniques offers incomplete data (1).

Surgeons are faced with the problems determined by parastomal hernias when they require surgery. Our study tries to reveal the clinical importance of this matter and may reflect the reality faced by patients.

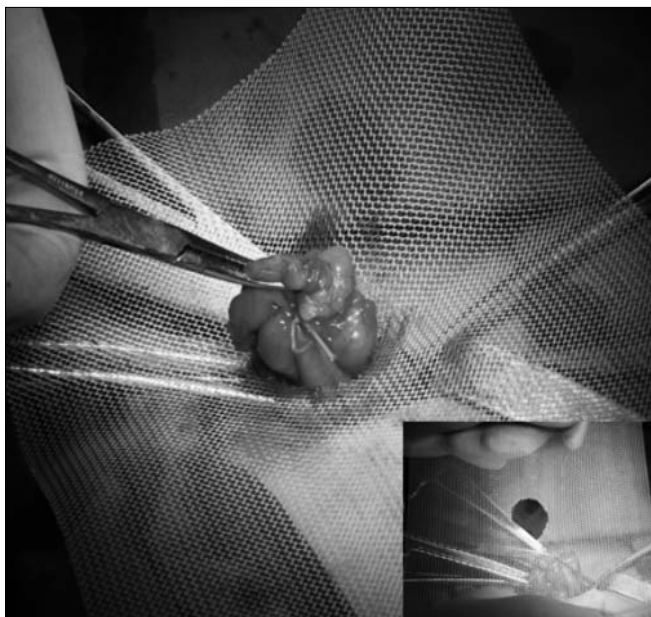
## Methods

At the First Surgical Department of "St. Spiridon" Hospital, between 2001 and 2010, 861 incisional hernias were treated, of which 31 parastomal hernias in 26 patients (3%), 5 of which were recurrent parastomal hernia.

As our experience demonstrated that a mesh repair is a safe procedure in the treatment of parastomal hernia, between March 2010 – December 2011 we initiated a prospective randomized trial on prophylactic use of mesh at the time of stoma formation to reduce the risk of parastomal hernia. We enrolled 20 patients with mesh implanted at the primary operation in the study and compared them to 22 patients with conventional stoma formation. The inclusion criteria were: patients with low rectal cancer, stage II-III, irradiated, obese, with a history of hernias, patients who do physical work. We used polypropylene mesh. Patients were examined after 3 months, 6 months, 12 months and 2 years. Any protrusion in the vicinity of the stoma was considered a parastomal hernia. The complications, reoperation, and parastomal hernia repair were recorded. The study was approved by the hospital's Ethics Committee.

## Operative procedures

We have performed sublay polypropylene mesh placement surgical techniques. A circular skin incision is made and the skin and subcutaneous tissue excised. An incision is made in the anterior rectus sheath, then the rectus muscle is split and the posterior sheath along with the peritoneum are incised. So, a space is created between the peritoneum and the rectus muscle. We customized the mesh by creating a central mesh hole with the diameter 5 mm larger than the colonic diameter (Fig. 1). The polypropylene mesh was fixed to the peritoneum and the serosa of the colon was not fixed to the mesh (Fig. 2), with the margins exceeding the parietal defect by 4-5 cm (Fig. 3). Then, the external rectus fascia was closed so that the mesh did not come in contact with the colic loop and the stoma was finally matured with seromucocutaneous sutures points (Fig. 4). By placing a prosthetic mesh during the primary operation, the operative time will be prolonged by



**Figure 1.** Mesh hole diameter is 5 mm larger than the colic loop

approximately 15 min. Also, by opening the bowel during the last stage of the operation, the contamination of the mesh with intestinal contents was kept to a minimum.

## Results

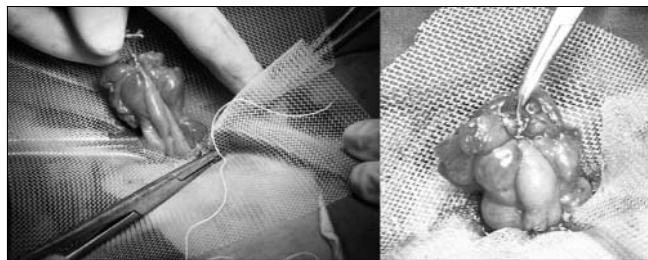
The patients with parastomal hernia had the following distribution by gender: male/female = 11/15. The mean age of the patients was 66.72 years (44-84 years).

Clinical examination, intraoperative exploration and CT exam revealed the following subtypes of parastomal hernia: interstitial (sac within layers of the abdominal wall) - 9 cases; subcutaneous (hernia sac in the subcutaneous plane) - 11 cases; intrastomal (sac penetrates into stoma) - 5 cases; peristomal (sac is within prolapsing stoma) - 6 cases. In one case only, the parastomal hernia occurred after loop colostomy, the rest developed after end colostomy.

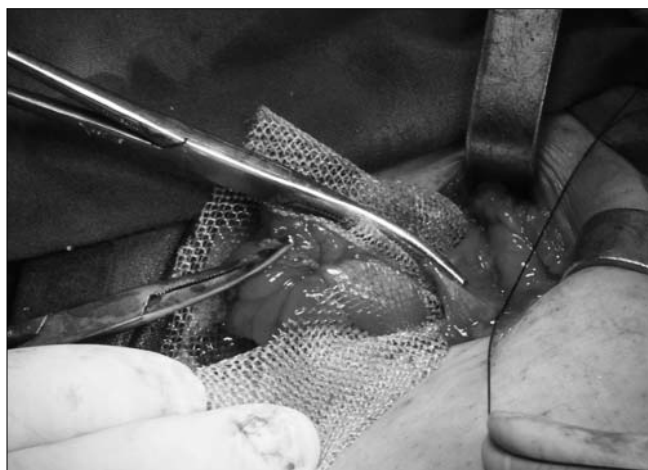The size of the hernia sac was: under 5 cm - 2 cases; between 5 and 10 cm - 12 cases; between 10 and 15 cm - 14 cases; more than 15 cm - 3 cases.

Concerning the condition for which the stoma was performed, rectal cancer predominated (22 cases), followed by anal cancer (2 cases). In 2 cases we performed a Hartmann operation: for an occlusive rectosigmoid cancer in one case and for perforated colic diverticulitis in another case. Cancers were predominantly diagnosed as stage III by TNM classification based on the AJCC Cancer Staging Manual, 7th edition: IIIA - 7 cases, IIIB - 6 cases, IIIC - 2 cases; 6 cases were classified as stage II, 3 cases as stage I and one case as IVA stage.

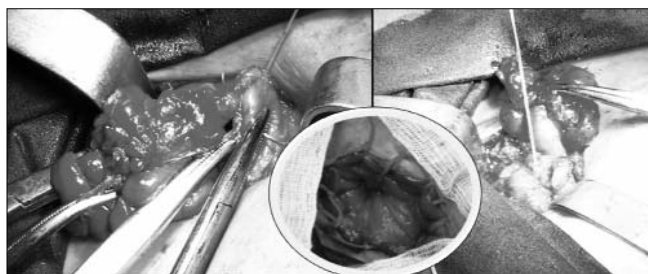
The time interval between primary intervention and parastomal hernia occurrence ranged from 7-96 months, with an average of 66.8 months (5.5 years). The mean recurrence interval of parastomal hernia was 22 months (ranged 4 - 56 months).



**Figure 2.** The polypropylene mesh is fixed to the peritoneum



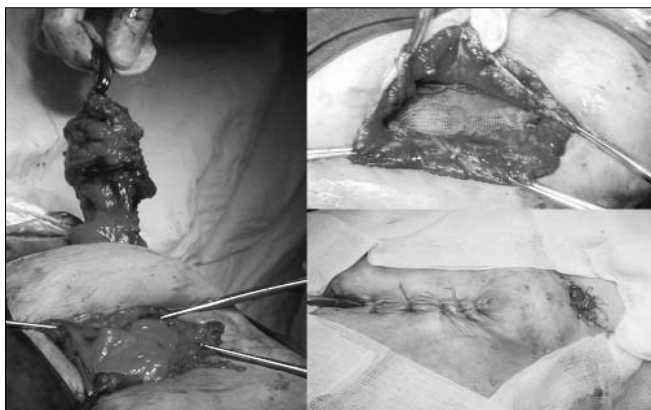
**Figure 3.** The mesh margins exceed the parietal defect by 4-5 cm



**Figure 4.** Closure of the muscular plane so that the mesh does not come in contact with the colic loop

Most parastomal hernias were asymptomatic; only six cases with parastomal hernias required emergency surgical treatment for obstruction (3 cases) or strangulation (3 cases). Most patients had local pain and deformation of the abdomen and difficulty changing the colostomy bag. Two patients had associated median incisional hernia. The predisposing factors for occurrence of parastomal hernia were: obesity - 13 cases; respiratory and/or cardiovascular disease - 16 cases; multiple operations on the abdomen - 15 cases; medical history of hernias and/or incisional hernias - 14 cases.

We performed: local tissue repair in 16 cases (4 cases with recurrent parastomal hernia; stoma relocation in one case); sublay mesh repair in 15 cases (one case with recurrent parastomal hernia; stoma relocation in 5 cases). The associated operations performed were: viscerolysis, colic resection



**Figure 5.** Relocation of the stoma

(5 cases), small bowel resection (2 cases). Postoperative morbidity included 4 wound infections (one case after mesh repair which required surgical reintervention) and stoma necrosis in one case, with strangulation parastomal hernia with severe postoperative evolution and death. After local tissue repair recurrences were seen in 6 cases, while after mesh repair we registered recurrence only in one case, which developed a parietal suppuration and no relapse after the relocation of the stoma (Fig. 5).

As our experience demonstrated that a mesh repair is a safe procedure in the treatment of parastomal hernia, in 2010 we initiated a prospective randomized trial on the use of a prophylactic mesh at the time of stoma formation to reduce the risk of parastomal hernia. Also, we performed a literature review and found a lack of studies on this technique and no citations in Romanian literature.

We selected patients with low rectal cancer after irradiation, staged II-III, obese, patients who perform great physical effort, with hernias in their past medical history. The operative time for prophylactic mesh placement did not significantly increase the operating time, ranging 13-20 min (the mean time = 15 min).

On the first postoperative day and until the patient was discharged, the stoma was evaluated on regular daily rounds by an experienced stoma nurse and a surgeon.

The patients were followed for a median of 20 months (range 12 to 28 months) by clinical examination and ultrasound exam every 3 months. We evaluated, by digital examination of the stoma inclusively, clinical signs of parastomal hernia, inflammatory reaction, signs of infection, signs of fistula formation, foreign-body reaction, signs of stricture formation.

All operations were elective and all patients with prophylactic use of mesh at the time of stoma formation (lot I) were operated on for rectal cancer: abdominoperineal excision for all cases. The operations were performed by two surgeons. The same surgeons performed conventional stoma formation (lot II) for rectosigmoid neoplasia: 10 abdominoperineal excisions, 12 Hartmann procedures for low anterior rectal resections.

Seven patients had preoperative chemo-radiotherapy and all patients had postoperative chemotherapy.

Four patients in lot I and five patients in lot II had a seroma in their midline incision and were treated by local drainage without the need for further surgery or antibiotic therapy. Two patients in lot II had wound infection. Three patients in lot I and two patients in lot II had pneumonia and two patients in lot I and four patients in lot II had a urinary tract infection and were treated with systemic antibiotics. Two patients in both lots had diabetes.

Over the long-term follow-up we registered 6 recurrences, all in the no mesh cohort. The patients had both clinical and objective signs of parastomal hernia for a median of 9 months (range 4 to 16 months). Two patients presented a problem with applying the stoma bag, the major complaint being esthetical and four patients required reoperation with the relocation of the stoma and mesh repair. We have not seen any morbidity (bowel strictures, inflammatory reaction, signs of foreign body reaction, infection, or fistula formation in the vicinity of the stoma) in patients from the mesh group.

## Discussion

A parastomal hernia is defined as an incisional hernia at the site of a stoma with symptoms and complications similar to a ventral hernia, but specific symptoms can also occur: difficulty maintaining the stoma bag, difficulty with irrigation or emptying of the stomas (3).

Devlin (4) described four types of parastomal hernia: Interstitial – a bowel loop herniates next to the stoma and penetrates between the intermuscular planes. Subcutaneous (most common type) - the herniation of the bowel loop occurs alongside the stoma and reaches into the subcutaneous tissue. Intrastomal (it usually occurs after ileostomy) - the herniation of the bowel occurs alongside the bowel for the stoma and enters the plane between the emerging and the everted part of the bowel. Perstomal - The stoma is prolapsed and loops of bowel and/or omentum enter the hernia space produced between the layers of the prolapsed bowel.

Clinical parastomal hernias are asymptomatic, symptomatic or complicated by subocclusion, occlusion, irreducibility. Physical examination specified diagnosis. Because they do not cause functional disorders, some parastomal hernias are well supported and abdominal deformity is accepted by patients for fear of reinterventions (5).

Increasing the volume of parastomal hernias, however, is inevitable, surgical repair becoming more difficult as its volume is greater. The creation of an abdominal stoma should not be regarded as a minor surgical procedure. Its risks must be assessed, especially of general and local reintervention in elderly patients, obese, vascular and / or other major diseases (6).

Indications for surgical treatment are absolute only in the presence of complications - obstruction, strangulation, the rest need an accurate assessment of risk. The main techniques used are fascial repair, stoma relocation and prosthetic mesh repair by laparotomy or laparoscopic intra-peritoneal mesh repair. Fascial repair and stoma relocation have a high

rate of complications (24-88%) and a high rate of recurrence (46-100%) (7,8). Mesh repair is considered to be a safe procedure with low risk of mesh infections. Prosthetic mesh repair has a recurrence rate of up to 28% (9,10).

The advantage of intra-peritoneal mesh placement by laparoscopic approach is that it is a sterile procedure with a probable lower risk of infection. Laparoscopic correction with expanding polytetrafluoroethylene (ePTFE) has a promising recurrence rate of 2-8%, but still presents a high rate of complications, of 30%: risk of iatrogenic bowel damage, bowel erosion, ileus by adhesion formation, colic stenosis or stoma stenosis (11-14).

In recent years there has been a decrease in peristomal complications by prophylactic mesh placement (15-17). Placement of a polypropylene mesh during the primary operation has been described by Rosin JD in 1977 (18).

Mesh placement during the primary stoma formation has been described by Helgstrand: onlay mesh procedure (it is positioned on the external rectus fascia) and sublay mesh procedure (it is positioned in different ways, either inside the abdomen, pre-peritoneal, or between the rectus muscle and the posterior rectus sheath) (19).

The placement of a prophylactic mesh during the primary operation is a safe procedure, postoperative morbidity levels were similar whether the mesh was placed or not, and reduces the incidence of parastomal hernia (20,21).

Although there no data related with antibiotic prophylaxis, but this is necessary to prevent postoperative wound infection and polypropylene mesh (22).

If polypropylene mesh is not isolated from the digestive wall, it can migrate into the lumen as in the case of diaphragmatic hernia repair with mesh (23).

Mylonakis E. et al (24) identified factors which predispose to increased parastomal hernia formation and that may be the indication of prophylaxis with mesh: elderly patients (age > 60 years), prostatic hypertrophy, cardiorespiratory disease, constipation or ascites, obesity, history of hernias. Despite limited evidence, Hotouras A et al recommended prophylaxis with mesh in all cases with permanent colostomy (25).

From our modest experience we can set up a permanent colostomy risk scale, leading to prophylactic mesh placement: elderly patients, obesity, co-morbidities that increase intra-abdominal pressure, life expectancy over two years, irradiated colorectal cancer and adjuvant chemotherapy, coexistence of abdominal hernias and incisional hernias. The existence of more than two risk factors requires prophylaxis with mesh.

Nevertheless, the surgical accuracy of stoma creation is the key factor to prevent a parastomal hernia. Alternatively, an extraperitoneal tunneling of the bowel may be considered (26).

## Conclusions

Parastomal hernia is a relatively rare disease compared to the number of incisional hernias. With increased life expectancy stands we noted increased incidence of parastomal hernia as well. Prophylactic use of mesh during the primary operation is a safe procedure and reduces the risk of parastomal hernia.

## Conflict of interest disclosure

Partial results of this study were published in the paper "Parastomal hernias can be prevented? Jurnalul de chirurgie 2011;7(1):123-129". The editor in chief of Jurnalul de chirurgie agreed to transfer all copyrights to Chirurgia.

## References

1. Israelsson LA. Parastomal hernia treatment with prosthetic mesh repair. *Chirurg*. 2010;81(3):216-21.
2. Jänes A, Cengiz Y, Israelsson LA. Preventing parastomal hernia with a prosthetic mesh: a 5-year follow-up of a randomized study. *World J Surg*. 2009;33(1):118-21; discussion 122-3.
3. Bara T, Eşianu M, Podeanu D, Neagoe R, György-Fazakas I, Török A, et al. The surgical treatment of the parastomal hernia using prolene mesh. *Chirurgia (Bucur)*. 2003;98(6):583-5.
4. Devlin HB. Peristomal hernia. In Dudley H ed. *Operative Surgery Volume 1: Alimentary Tract and Abdominal Wall*, 4th ed. London: Butterworths; 1983. p. 441.
5. Shellito PC. Complications of abdominal stoma surgery. *Dis Colon Rectum*. 1998;41(12):1562-72.
6. Cheung MT. Complications of an abdominal stoma: an analysis of 322 stomas. *Aust N Z J Surg*. 1995;65(11):808-11.
7. Carne PW, Robertson GM, Frizelle FA. Parastomal hernia. *Br J Surg*. 2003;90(7):784-93.
8. Rieger N, Moore J, Hewett P, Lee S, Stephens J. Parastomal hernia repair. *Colorectal Dis*. 2004;6(3):203-5.
9. Amin SN, Armitage NC, Abercrombie JF, ScholeWeld JH. Lateral repair of parastomal hernia. *Ann R Coll Surg Engl*. 2001; 83(3):206-8.
10. Stephenson BM, Phillips RK. Parastomal hernia: local resiting and mesh repair. *Br J Surg*. 1995;82(10):1395-6.
11. Berger D, Bientzle M. Laparoscopic repair of parastomal hernias: a single surgeon's experience in 66 patients. *Dis Colon Rectum*. 2007;50(10):1668-73.
12. Hansson BM, de Hingh IH, Bleichrodt RP. Laparoscopic parastomal hernia repair is feasible and safe: early results of a prospective clinical study including 55 consecutive patients. *Surg Endosc*. 2007;21(6):989-93.
13. Ballas KD, Rafailidis SF, Marakis GN, Pavlidis TE, Sakadamis AK. Intraperitoneal ePTFE mesh repair of parastomal hernias. *Hernia*. 2006;10(4):350-3.
14. LeBlanc KA, Bellanger DE, Whitaker JM, Hausmann MG. Laparoscopic parastomal hernia repair. *Hernia*. 2005;9(2):140-4.
15. Gögenur I, Mortensen J, Harvald T, Rosenberg J, Fischer A (2006) Prevention of parastomal hernia by placement of a polypropylene mesh at the primary operation. *Dis Colon Rectum*. 2006;49(8):1131-5.
16. Jänes A, Cengiz Y, Israelsson LA. Preventing parastomal hernia with a prosthetic mesh. *Arch Surg*. 2004;139(12):1356-8.
17. Marimuthu K, Vijayasekar C, Ghosh D, Mathew G (2006) Prevention of parastomal hernia using preperitoneal mesh: a prospective observational study. *Colorectal Dis*. 2006;8(8):672-5.
18. Rosin JD, Bonardi RA. Paracolostomy hernia repair with Marlex mesh: a new technique. *Dis Colon Rectum*. 1977;20(4): 299-302.
19. Helgstrand F, Gögenur I, Rosenberg J. Prevention of parastomal hernia by the placement of a mesh at the primary operation. *Hernia*. 2008;12(6):577-82.
20. Shabbir J, Chaudhary BN, Dawson R. A systematic review on

- the use of prophylactic mesh during primary stoma formation to prevent parastomal hernia formation. *Colorectal Dis.* 2012; 14(8):931-6.
21. Tam KW, Wei PL, Kuo LJ, Wu CH. Systematic review of the use of a mesh to prevent parastomal hernia. *World J Surg.* 2010; 34(11):2723-9.
  22. Ioannidis O, Paraskevas G, Varnalidis I, Ntoupas M, Tsigkriki L, Gatzos S, et al. Hernia mesh repair of the anterior abdominal wall and antibiotic chemoprophylaxis: multiple doses of antibiotics failed to prevent or reduce wound infection. *Chirurgia (Bucur).* 2013;108(6):835-9.
  23. Tănase M, Marin S, Amza S, Toader A. The use of allografts in the surgical treatment of enlarged hiatal hernias. *Chirurgia (Bucur).* 2012;107(2):195-8.
  24. Mylonakis E, Scarpa M, Barollo M, Yarnoz C, Keighley MR. Life table analysis of hernia following end colostomy construction. *Colorectal Dis.* 2001;3(5):334-7.
  25. Hotouras A, Murphy J, Thaha M, Chan CL. The persistent challenge of parastomal herniation: a review of the literature and future developments. *Colorectal Dis.* 2013; 15(5):e202-14.
  26. Lee JK, Kang WK. Risk factors of parastomal hernia and creation of an ostomy. *J Korean Soc Coloproctol.* 2012;28(5):225.